Robt. Mac de Smith



Robt. Meade Smith

Digitized by the Internet Archive
in 2014

https://archive.org/details/transactionsofpa5187path

TRANSACTIONS

OF THE

PATHOLOGICAL SOCIETY

OF PHILADELPHIA.

VOLUME FIFTH.

CONTAINING THE REPORT OF THE PROCEEDINGS FOR THE YEAR 1874, AND FROM JANUARY, 1875, TO JULY, 1875.

EDITED BY

JAMES TYSON, M.D.,

HOSPITAL PROFESSOR OF PATHOLOGICAL ANATOMY AND HISTOLOGY IN THE UNIVERSITY OF PENNSYLVANIA, ETC., RECORDER OF THE SOCIETY.

PHILADELPHIA:
PRINTED FOR THE SOCIETY BY J. B. LIPPINCOTT & CO.
1876.

THE present, and fifth, volume of the Pathological Society's Transactions, includes the material contributed during the whole of the year 1874, and from January to July of 1875; the object of the Publication Committee being so to arrange the matter that hereafter the annual volume will contain the work of a *session*, from September of one year to July of the next. It will be seen that the text of this volume exceeds notably in the number of pages that of the previous one, notwithstanding the fact that the time covered by it is but a year and a half, instead of three years. Gratifying as this is, it is scarcely more than any member, who has watched the liberal attendance and the large number of specimens contributed during this time, would have expected.

No material change has been made in the arrangement of the matter; but it will be observed that considerably more than heretofore of the remarks made in discussion have been added to the descriptions of the specimens. This has been deemed desirable on account of the increased interest they give to the specimens exhibited, as well as the new facts which some of them furnish in pathological anatomy; but the course of the Committee has perhaps been influenced more by the suggestion of a reviewer in one of our most valued journals, to the effect that such additions would increase the interest of our Transactions. The matter thus added, although more than heretofore, is still but a small proportion of the remarks published in our Proceedings.

Entered, according to Act of Congress, in the year 1875, by

J. B. LIPPINCOTT & CO.,

In the Office of the Librarian of Congress at Washington.

TABLE OF CONTENTS

OF VOLUME V.

	PAGE
List of Former Presidents	iv
List of Officers and Committees at Date of Issue	v
List of Members	vi
List of Specimens exhibited at the Meetings of the Society	xiv
List of Specimens reported on by the Committee on Morbid Growths	xxii
List of Specimens reported on by Special Committees	xxiii
List of Illustrations	xxiv
Diseases, etc., of the Osseous System	1
Diseases, etc., of the Organs of Digestion	20
Diseases, etc., of the Organs of Circulation	72
Diseases, etc., of the Organs of Respiration	113
Diseases, etc., of the Genito-Urinary Organs	139
Diseases, etc., of the Nervous System	179
Diseases, etc., of the Organs of Special Sense	197
Diseases of the Skin	205
Diseases, etc., of the Ductless Glands	208
Tumors not Otherwise Classifiable	218
Miscellaneous Specimens	232
Specimens from the Lower Animals	251
Index	253

19340

Former Presidents.

SAMUEL D. GROSS, M.D., LL.D. Oxon., elected 1857.
RENÉ LA ROCHE, M.D., elected 1858.
ALFRED STILLÉ, M.D., elected 1859–61–62 and '63.
EDWARD HARTSHORNE, M.D., elected 1863.
J. M. DA COSTA, M.D., elected 1864, '65 and '66.
JOHN H. PACKARD, M.D., elected 1867 and '68.
S. WEIR MITCHELL, M.D., elected 1869.
JOHN ASHHURST, Jr., M.D., elected 1870.
JAMES H. HUTCHINSON, M.D., elected 1871 and '72.
WILLIAM PEPPER, M.D., elected 1873.

OFFICERS AND COMMITTEES

OF THE

Pathological Society of Philadelphia.

President.

WILLIAM PEPPER, M.D.,

ELECTED OCTOBER, 1873, FOR THREE YEARS.

ELECTED AT THE ANNUAL MEETING, OCTOBER, 1875.

Vice-Presidents.

H. LENOX HODGE, M.D.,
W. F. NORRIS, M.D.,
JOHN S. PARRY, M.D.,
HARRISON ALLEN, M.D.

Secretary.

WM. G. PORTER, JR., M.D.

Treasurer.

WHARTON SINKLER, M.D.

Recorder.

JAMES TYSON, M.D.

Curator.

JAS. C. WILSON, M.D.

Committee on Pathological Research.

J. M. DA COSTA, M.D., F. F. MAURY, M.D.,
JNO. ASHHURST, JR., M.D., MORRIS LONGSTRETH, M.D.,
WHARTON SINKLER, M.D. (ex officio).

Committee on Publication.

S. W. MITCHELL, M.D., J. H. HUTCHINSON, M.D.,
J. H. BRINTON, M.D., S. ASHHURST, M.D.,
JAMES TYSON, M.D. (ex officio).

Committee on Morbid Growths.

R. M. BERTOLET, M.D., DE F. WILLARD, M.D.,
J. G. RICHARDSON, M.D., J. M. GUITÉRAS, M.D.,
J. C. WILSON, M.D., J. H. C. SIMES, M.D.,
LOUIS STARR, M.D.

LIST OF MEMBERS.

Members marked N. R. are non-resident.
Members marked O. M. are of those originating the Society.

Elected

1857 Agnew, D. Hayes, Professor of Surgery in the University of Pennsylvania, 1611 Chestnut Street. (O. M.)
1871 Alison, Robert H., 214 South Fifteenth Street.
1864 Allen, Harrison, Professor of Comparative Anatomy in the University of Pennsylvania, 117 South Twentieth Street.
1869 Allis, Oscar H., one of the Surgeons to the Presbyterian Hospital, 1328 Spruce Street.
1865 Andrews, Thomas H., Demonstrator of Anatomy in the Jefferson Medical College, 1117 Spruce Street.
1871 Ashbridge, William, Surgeon to the German Hospital, 1702 Chestnut Street.
1867 Ashhurst, Francis, Mount Holly, N. J. (N. R.)
1861 Ashhurst, John, Jr., one of the Surgeons to the Episcopal Hospital, 2000 West De Lancey Place.
1863 Ashhurst, Samuel, one of the Surgeons to the Episcopal Hospital, 1423 Walnut Street.
1871 Atlee, Washington L., Jr., 527 North Nineteenth Street.

1866 Bache, T. Hewson, 233 South Thirteenth Street.
1867 Bartles, William H., Insane Department Pennsylvania Hospital, West Philadelphia.
1869 Barton, J. M., 201 South Eleventh Street.
1873 Beecher, A. C. W., 1912 North Twelfth Street.
1870 Bell, J. R. F., 1817 North Eleventh Street.
1871 Bennett, Wm. H., 118 East Huntingdon Street.
1863 Benton, C. H. (N. R.)
1875 Bernardy, Eugene P., 1011 Walnut Street.
1870 Bertolet, Robert Morris, Pathologist to the Philadelphia Hospital, 113 South Broad Street.
1871 Betts, Thomas, Branchtown, Pa. (N. R.)
1860 Bishop, C. S., died ——.
1866 Black, J. J., Newcastle, Delaware.
1863 Boardman, C. H., St. Paul, Minnesota. (N. R.)

Elected

1857 Boker, Charles S., one of the Surgeons to the St. Joseph's Hospital, 1622 Chestnut Street. (O. M.)

1868 Bolles, Lucius S., died August 15th, 1873.

1873 Bray, Daniel, 112 North Seventeenth Street.

1857 Brinton, John H., one of the Surgeons to the Philadelphia Hospital, 1423 Spruce Street. (O. M.)

1874 Brubaker, A. P., 217 North Thirteenth Street.

1874 Bruen, Edward T., one of the Visiting Physicians to the Philadelphia Hospital, 1840 Green Street.

1871 Buck, William Penn, resigned October 23d, 1873.

1867 Burnett, C. H., Aural Surgeon to the Presbyterian Hospital, 127 South Eighteenth Street.

1872 Cathcart, James H., died March 5th, 1874.

1871 Cheston, C. Morris, West River, Maryland. (N. R.)

1865 Cheston, D. Murray, one of the Physicians to the Children's Hospital, 25 South Sixteenth Street.

1871 Clark, Leonardo S., 1505 Girard Avenue.

1866 Cleemann, Richard A., one of the Physicians to the St. Mary's Hospital, 340 South Twenty-first Street.

1872 Cohen, J. Solis, 1431 Walnut Street.

1869 Corbit, William B., Washington, D. C. (N. R.)

1871 Curtin, Roland G., Chief of the Medical Dispensary, Hospital of the University of Pennsylvania, 332 South Seventeenth Street.

1857 Da Costa, J. M., Professor of Theory and Practice of Medicine in the Jefferson Medical College, 1609 Walnut Street. (O. M.)

1859 Darby, John T., New York City. (N. R.)

1857 Darrach, James, Queen Street, near Rittenhouse, Germantown. (O. M.)

1868 Darrach, William, 42 Queen Street, Germantown.

1870 Deal, Lemuel J.*

1866 Duer, Edward L., one of the Obstetricians to the Philadelphia Hospital, 1704 Arch Street.

1870 Duhring, L. A., Clinical Professor of Dermatology in the University of Pennsylvania, 1416 Spruce Street.

1860 Dunton, W. R., corner Main and High Streets, Germantown.

1863 Dyer, Ezra, Pittsburg, Pennsylvania. (N. R.)

1875 Engel, Hugo, northeast corner Fifth and Wood Streets.

1857 Fischer, Emil, southeast corner Sixth and Brown Streets. (O. M.)

1863 Fish, Augustine H., died August 3d, 1872.

1857 Forbes, William S., one of the Surgeons to the Episcopal Hospital, 1405 Locust Street. (O. M.)

1869 Ford, William H., 1622 Summer Street.

Elected

1871 Fox, Charles, resigned.

1868 Garretson, James E., 1537 Chestnut Street.

1871 Gerhard, George S., Pathologist to the Presbyterian Hospital, 1823 Spruce Street.

1870 Getchell, Frank H., Clinical Lecturer on Diseases of Women in the Jefferson Medical College, 1432 Spruce Street.

1866 Goodell, William, Clinical Professor of Diseases of Women in the University of Pennsylvania, Preston Retreat, Twentieth and Hamilton Streets.

1868 Goodman, H. Earnest, one of the Surgeons to the Orthopædic Hospital, 1427 Chestnut Street.

1868 Graham, James, 1342 Pine Street.

1867 Grier, Matthew J., 312 South Fifteenth Street.

1868 Gross, Ferdinand H., one of the Surgeons to the German Hospital, 608 North Sixth Street.

1857 Gross, Samuel D., Professor of Surgery in the Jefferson Medical College, Eleventh and Walnut Streets. (O. M.)

1858 Gross, Samuel W., one of the Visiting Surgeons to the Philadelphia Hospital, 1115 Walnut Street.

1869 Grove, John H., one of the Surgeons to the St. Mary's Hospital, 1330 Arch Street.

1872 Gruel, Theodore H. E., 519 Spruce Street.

1874 Guitéras, John M., one of the Visiting Physicians to the Philadelphia Hospital, 1912 Vine Street.

1871 Hale, George J., 4512 Frankford Road.

1857 Hall, A. Douglass, one of the Surgeons to the Wills Ophthalmic Hospital, 1623 Spruce Street. (O. M.) Resigned.

1875 Hand, Frank C., 830 Pine Street.

1866 Hare, Horace Binney, one of the Physicians to the Episcopal Hospital, 229 South Sixth Street.

1868 Hargadine, R. W. (N. R.)

1859 Harlan, George C., one of the Surgeons to the Wills Ophthalmic Hospital, 1806 Chestnut Street.

1874 Harris, Charles M., 715 South Twenty-third Street.

1858 Harris, Robert P., resigned January 9th, 1873.

1857 Hartshorne, Edward, 1439 Walnut Street. (O. M.)

1859 Hartshorne, Henry, resigned October 12th, 1864.

1867 Hassler, Ferdinand A., resigned February 9th, 1871.

1869 Hatfield, Nathan L., one of the Visiting Surgeons to the Philadelphia Hospital, 501 Franklin Street.

1868 Hays, I. Minis, 1527 Locust Street.

1873 Hearn, Joseph, 324 Catharine Street.

1870 Henry, Frederick P., one of the Physicians to the Episcopal Hospital, 635 Spruce Street.

Elected

1866 Herbert, Theodore. (N. R.)

1857 Hewson, Addinell, one of the Surgeons to the Pennsylvania Hospital, northeast corner of Twenty-first and Walnut Streets. (O. M.)

1874 Hickman, N., 326 South Sixteenth Street.

1858 Hodge, H. Lenox, one of the Surgeons to the Presbyterian Hospital, 506 South Broad Street.

1871 Hoffman, Washington Atlee, died September 20th, 1874.

1860 Hopkins, Henry St. George. (N. R.)

1870 Houstoun, James P. S., Savannah, Georgia. (N. R.)

1866 Howe, Herbert M., 1606 Locust Street.

1859 Hoyt, William D. (N. R.)

1857 Humphries, George H., New York City. (O. M. N. R.)

1868 Hunter, Charles T., Demonstrator of Surgery in the University of Pennsylvania, 1905 Walnut Street.

1870 Hutchins, E. R. (N. R.)

1858 Hutchinson, James H., one of the Physicians to the Pennsylvania Hospital, 2019 Walnut Street.

1866 Ingham, James V., one of the Obstetricians to the State Hospital for Women, 1342 Spruce Street.

1874 Jameson, Edward, St. Louis, Mo. (N. R.)

1866 Jenks, William F., Surgeon to the State Hospital for Women.

1875 Johnson, Russell H., one of the Assistant Physicians to the Children's Hospital, 727 Pine Street.

1859 Kane, John K., Wilmington, Delaware. (N. R.)

1874 Keating, John M., one of the Visiting Physicians to the Philadelphia Hospital, 222 South Sixteenth Street.

1857 Keating, William V. (O. M.*)

1866 Keen, William W., one of the Surgeons to the St. Mary's Hospital, 1729 Chestnut Street.

1857 Keller, William, resigned. (O. M.)

1875 Kelly, Joseph V., 4257 Main Street, Manayunk.

1858 King, William, United States Navy. (N. R.)

1869 Knight, Samuel R., Superintendent of the Episcopal Hospital.

1867 Lambdin, Alfred C.*

1871 Landis, Henry G., Niles, Ohio. (N. R.)

1872 La Roche, C. Percy, Nice, France. (N. R.)

1857 La Roche, René, resigned October 12th, 1871. (O. M.) Died December 9th, 1872.

1870 Leach, Alonzo L., 2118 Spruce Street.

1869 Leaman, Henry, 1031 Vine Street.

1860 Lee, Charles C., New York City. (N. R.)

1861 Leedom, John M., Pulaski Avenue, Germantown.

Elected

1857 Levick, James J., resigned October 13th, 1861. (O. M.)
1868 Lewis, Francis W., 2016 Spruce Street.
1869 Lewis, Fred. W., died 1873.
1875 Lewis, J. Morris, 1216 Walnut Street.
1857 Lewis, Samuel, 1330 Spruce Street. (O. M.)
1859 Livezy, Edward.*
1873 Longenecker, Jerome.
1870 Longstreth, Morris, Pathologist to the Pennsylvania Hospital, 333 South Twelfth Street.
1870 Loughlin, J. Eneu, 632 Christian Street.

1874 Mann, Charles H., Children's Hospital.
1867 Markoe, James.
1868 Martin, Geo. (N. R.)
1874 Matteson, Charles C.
1865 Maury, Frank F., one of the Surgeons to the Philadelphia Hospital, 1218 Walnut Street.
1870 Maxwell, J. Gordon.*
1866 McArthur, John A., 406 South Broad Street.
1861 McCall, C. A., resigned.
1868 McClure, W. Wallace, one of the Surgeons to the Wills Ophthalmic Hospital, 29 South Sixteenth Street.
1873 McCoy, A. W., Pittsburg, Pa. (N. R.)
1864 Mears, J. Ewing, one of the Surgeons to the St. Mary's Hospital, 1429 Walnut Street.
1873 Meigs, Arthur V., Assistant Physician to the Children's Hospital, 1208 Walnut Street.
1857 Meigs, John Forsyth, one of the Physicians to the Pennsylvania Hospital, 1208 Walnut Street. (O. M.)
1874 Miller, C. K. I., 4039 Baltimore Avenue.
1857 Mitchell, S. Weir, one of the Physicians to the Hospital for Nervous Diseases, 1332 Walnut Street. (O. M.)
1857 Morehouse, George R., 227 South Ninth Street. (O. M.)
1857 Morton, Thomas George, one of the Surgeons to the Pennsylvania Hospital. (O. M.*)
1859 Moss, William, Chestnut Avenue, Chestnut Hill.
1871 Muhlenberg, Frank, 1618 Chestnut Street.
1869 Müller, August F., 4544 Germantown Avenue.
1873 Musser, Milton B., Fortieth and Walnut Streets.
1869 Mustin, J. Burton, died ——.

1869 Nancrede, Charles B., one of the Assistant Surgeons to the Episcopal Hospital, 2109 Pine Street.
1872 Newsham, Stanley P., 1507 South Fifth Street.
1868 Norris, Herbert, one of the Physicians to the Episcopal Hospital, 313 South Eighteenth Street.

Elected

1868 Norris, Isaac, resigned.
1869 Norris, J. C., 1307 Girard Avenue.
1861 Norris, William F., Clinical Professor of Ophthalmology in the University of Pennsylvania, 1532 Locust Street.

1875 O'Hara, Michael, 31 South Sixteenth Street.
1874 Osgood, Hamilton, 1805 Chestnut Street.

1857 Packard, John H., one of the Surgeons to the Episcopal Hospital, 1928 Spruce Street. (O. M.)
1868 Pancoast, William H., Professor of Anatomy in the Jefferson Medical College, 1100 Walnut Street.
1873 Parish, William H., 324 South Seventeenth Street.
1875 Parks, Edward L., 1338 Spruce Street.
1867 Parry, John S., one of the Obstetricians to the Philadelphia Hospital, 1513 Arch Street.
1870 Paul, Comegys, Assistant Physician to the Children's Hospital, 326 South Seventeenth Street.
1875 Paul, James, 1608 Walnut Street.
1857 Penrose, R. A. F., Professor of Obstetrics and Diseases of Women and Children in the University of Pennsylvania. (O. M.*)
1865 Pepper, George, died September 14th, 1872.
1865 Pepper, William, Clinical Professor of Medicine in the University of Pennsylvania, 1811 Spruce Street.
1870 Porter, William G., Jr., one of the Surgeons to the Presbyterian Hospital, 314 South Eleventh Street.

1874 Reed, Henry B., 1921 Walnut Street.
1859 Reed, Thomas B., one of the Surgeons to the Presbyterian Hospital, 1427 Walnut Street.
1871 Rex, George A., 2004 Pine Street.
1869 Rex, Oliver P.*
1864 Rhoads, Edward, died January 16th, 1871.
1869 Richardson, Elliott, Obstetrician to the House of Industry, 737 Spruce Street.
1863 Richardson, Joseph G., one of the Visiting Physicians to the Presbyterian Hospital, 1835 Chestnut Street.
1857 Richardson, T. G., New Orleans, La. (O. M. N. R.)
1868 Ritz, Charles M. (N. R.)
1874 Ronaldson, Wm. D.

1867 Santee, Eugene J., 532 North Sixth Street.
1863 Savery, Wm., Bryn Mawr, Pennsylvania. (N. R.)
1869 Schell, H. S., 1004 Vine Street.
1874 Seiler, Carl, 1327 Spruce Street.
1870 Seyfert, Theodore H., 1813 Columbia Avenue.

Elected

1870 Shaffner, Charles, 2042 Vine Street.
1869 Shapleigh, Elisha B., 658 North Eighth Street.
1868 Sherwood, Thomas H.*
1871 Simes, J. H. C., 2033 Chestnut Street.
1868 Sinkler, Wharton, one of the Physicians to the Hospital for Nervous Diseases, 1534 Spruce Street.
1858 Smith, A. H., Lecturer on Obstetrics at the Philadelphia Lying-in Charity, 1419 Walnut Street.
1863 Smith, E. A., 126 South Eighteenth Street.
1859 Smith, F. G., Professor of the Institutes of Medicine in the University of Pennsylvania, resigned.
1875 Smith, Stanley, Lecturer on Physical Diagnosis in Jefferson Medical College, 210 South Twelfth Street.
1871 Sparks, Geo. W.*
1866 Spooner, Edward A.*
1871 Starr, Louis, Assistant Physician to the Episcopal Hospital, 1417 Spruce Street.
1857 Stillé, Alfred, Professor of Theory and Practice of Medicine in the University of Pennsylvania, 3900 Spruce Street. (O. M.)
1870 Strawbridge, George, Clinical Professor of Diseases of the Ear in the University of Pennsylvania, 1616 Chestnut Street.
1869 Stryker, Samuel S., 3713 Walnut Street.

1866 Thomas, Charles H., Professor of Materia Medica in the Women's Medical College, 108 North Twelfth Street.
1868 Thomson, William, one of the Surgeons to the Wills Ophthalmic Hospital, 1502 Locust Street.
1870 Tinkham, J. H., United States Navy. (N. R.)
1866 Townsend, George D. (N. R.)
1868 Townsend, R. M., 1500 Walnut Street.
1864 Turner, A. P., 1621 Pine Street.
1863 Tutt, Charles Pendleton, died May 11th, 1866.
1863 Tyson, James, Professor of Pathological Anatomy and Histology in the University of Pennsylvania, 332 South Fifteenth Street.

1871 Valdivieso, R. (N. R.)
1870 Van Harlingen, Arthur C., Chief of the Dispensary for Diseases of the Skin, Hospital of the University of Pennsylvania, 129 South Fifteenth Street.

1874 Warder, Wm. H., one of the Obstetricians to the Philadelphia Hospital, 810 North Broad Street.
1867 Watson, E. W., 146 North Twentieth Street.
1866 Weightman, John F., resigned.
1875 West, Franklin, 1722 Girard Avenue.

Elected

1875 Whelen, Alfred, 1005 Spruce Street.

1873 White, J. William, one of the Visiting Surgeons to the Philadelphia Hospital.

1868 Willard, De Forrest, Pathologist to the Presbyterian Hospital, 113 South Sixteenth Street.

1865 Williams, Horace, one of the Obstetricians to the State Hospital for Women, 1717 Pine Street.

1875 Williamson, Jesse, 1711 Pine Street.

1867 Wilson, Ellwood, 212 South Fifteenth Street, resigned.

1869 Wilson, James C., one of the Visiting Physicians to the Philadelphia Hospital, 214 South Fifteenth Street.

1867 Wilson, James F., 826 Arch Street.

1869 Wilson, J. H. (N. R.)

1873 Winslow, W. H., 3729 Locust Street.

1864 Wistar, Thomas, resigned.

1863 Wood, Horatio C., Jr., Clinical Professor of Diseases of the Nervous System in the University of Pennsylvania, 1706 Chestnut Street.

1865 Woods, D. Flavel, one of the Physicians to the Presbyterian Hospital, 151 North Fifteenth Street.

1857 Woodward, J. J., United States Army, Washington, D.C. (O. M. N. R.)

1872 Worthington, David J., 116 South Fifteenth Street.

Members marked * have forfeited their membership.

CORRESPONDING MEMBERS.

1866 Bumstead, Freeman J., Professor of Venereal Diseases in the College of Physicians and Surgeons, New York.

1859 Clark, Alonzo, Professor of Theory and Practice of Medicine in the College of Physicians and Surgeons, New York.

1859 Dalton, J. C., Professor of Physiology in the College of Physicians and Surgeons, New York.

1860 Ellis, Calvin, Professor of Theory and Practice of Medicine in the Medical Department of Harvard University, Boston, Massachusetts.

1858 Flint, Austin, Sr., Professor of Theory and Practice of Medicine in Bellevue Hospital Medical College, New York.

1858 Hammond, William A., Member of the National Academy of Sciences, New York.

1860 Isaacs, C., New York, died ——.

1860 Reeves, James E., Wheeling, West Virginia.

1861 Rokitansky, Carl, Professor of Pathological Anatomy in the University of Vienna.

1860 Watson, John, New York.

1859 Worthington, Wilmer, West Chester, Pennsylvania, died 1873.

LIST OF SPECIMENS.

I.—THE OSSEOUS SYSTEM.

PAGE

1. Case of small round-celled sarcoma By Dr. Charles B. Nancrede 1
2. Intracapsular fracture of the femur . By Dr. O. H. Allis 5
3. Chronic arthritis—knee . By Dr. H. Lenox Hodge 5
4. Epulis . . . . . By Dr. R. M. Bertolet 6
5. Multiple gummata of the cranial bones and dorsal vertebræ, giving rise to extensive destruction of these structures, leading to compression of the spinal cord and inducing paraplegia . . . . By Dr. R. M. Bertolet 7
6. Chronic arthritis—wrist . . By Dr. H. Lenox Hodge 9
7. Hip-joint disease; the head and neck of the femur, removed by excision—the head found separated from the neck by ulceration . . . By Dr. H. Lenox Hodge 10
8. Exostosis of lower jaw . By Dr. John Ashhurst, Jr. 11
9. Osteo-sarcoma of the lower jaw, involving the ramus, angle, and a portion of the body . . By Dr. J. Ewing Mears 12
10. Compound comminuted fracture of the skull, involving both tables, with depression . . By Dr. J. Ewing Mears 12
11. Excision of the knee . By Dr. John Ashhurst, Jr. 14
12. Head of the femur removed by excision in a case of coxalgia By Dr. J. M. Barton 15
13. Compound fracture of skull, multiple fractures of vertebræ and ribs, laceration of spinal cord By Dr. John Ashhurst, Jr. 15
14. Fracture of the skull . . . By Dr. W. S. Forbes 16
15. Fracture of the cranium . . By Dr. Edw. L. Parks 17

II.—THE DIGESTIVE APPARATUS.

PAGE

1. Obstruction of the bowel . By Dr. Morris Longstreth 20
2. Enlarged spleen and cirrhotic liver By Dr. Morris Longstreth 20
3. Cancer of the liver . . By Dr. Morris Longstreth 22
4. Rupture of the gall-bladder . . By Dr. Wm. Pepper 23
5. Intussusception . . . By Dr. James Tyson 24
6. Gall-stone passed by a woman during life By Dr. James Tyson 25
7. Multiple intussusception . By Dr. A. C. W. Beecher 25
8. Multiple intussusception . By Dr. Morris Longstreth 26
9. Enormously distended stomach, in connection with caseous consolidation of the left lung, with several abscesses simulating pneumothorax . . . . By Dr. Wm. Pepper 26
10. Cancer of the pylorus . . . By Dr. F. P. Henry 27
11. Typhoid fever—anomalous course of temperature—marked symptoms of spinal irritation—death on ninth day (?)—characteristic lesions . . . By Dr. Wm. Pepper 29
12. Viscera from a case of amputation of the breast; death four weeks after operation, and wound almost healed By Dr. John H. Packard 31
13. Cancer of the gall-bladder . . By Dr. James Tyson 32
14. Ulceration of Peyer's glands . By Dr. J. Ewing Mears 33
15. Dysenteric inflammation, with cystic kidneys By Dr. F. P. Henry 35
16. Gastric ulcer . . . . By Dr. F. P. Henry 35
17. Two specimens of intestines from cases of typhoid fever By Dr. Wm. Pepper 36
18. Congenital imperforation of the duodenum and absence of the gall-bladder . . By Dr. Richard A. Cleemann 38
19. Sarcoma involving the parotid gland and masseter muscle By Dr. J. Ewing Mears 41
20. Two cases of intestinal perforation, the sequelæ of typhoid fever . . . . . By Dr. F. P. Henry 41
21. Perforation of vermiform process by ulceration, and resulting acute diffuse peritonitis By Dr. W. H. Warder, for Dr. Edward Stone 43
22. Cystic disease of the submaxillary gland By Dr. John Ashhurst, Jr. 45

PAGE

23. Cancer of the cæcum, and intussusception into large intestine —intramural fibroid tumor of the uterus—cystic ovaries By Dr. Wharton Sinkler, for Drs. J. J. Black and Stewart 46
24. Hepatic abscess, opening externally in right side—death from exhaustion . . . . By Dr. Wm. Pepper 47
25. Peritoneal tuberculosis . . . By Dr. F. P. Henry 50
26. Scirrhous cancer of the pancreas, liver, and lung; hydatid cyst of liver . . . . By Dr. H. Osgood 51
27. Cirrhosed liver and congested stomach By Dr. F. P. Henry 55
28. Gummata in the liver . . By Dr. A. C. W. Beecher 56
29. Epithelial cancer of rectum By Dr. Leonardo S. Clark, for Dr. Abraham S. Gerhard 59
30. Multiple hernia . . . By Dr. De F. Willard 62
31. Verbal communication on intestinal obstruction caused by huge thrombus resulting from rupture of the abdominal aorta By Dr. Wm. Pepper 63
32. Cancer of the liver By Dr. O. H. Allis, for Dr. Mixsell, of Easton, Pa. 65
33. Biliary calculi impacted in the left branch of the hepatic duct, attended with numerous cystic formations in the corresponding lobe of the liver . . By Dr. R. M. Bertolet 65
34. Multiple cavernous angeioma of the liver By Dr. R. M. Bertolet 68

III.—THE VASCULAR SYSTEM.

1. Disease of the mitral and aortic valves By Dr. J. Ewing Mears 72
2. Advanced mitral disease of the heart, conjoined with disease of the kidneys . . . . By Dr. James Tyson 72
3. Aneurism of the aorta . . By Dr. J. H. Hutchinson 77
4. Congenital malformation of the heart, contraction of the pulmonary artery, deficient septum ventriculorum, with origin of the aorta from both ventricles; no cyanosis By Dr. Geo. A. Rex 78
5. Specimens from Dr. Levis's case of aneurism of the subclavian artery treated by the introduction of horse-hairs By Dr. Morris Longstreth 79

PAGE

6. Atheromatous and calcareous degeneration of the aorta By Dr. J. H. Hutchinson 83
7. Aneurism of the arch of the aorta By Dr. J. H. Hutchinson 84
8. Aneurism of the abdominal aorta By Dr. H. B. Reed, for Dr. H. B. Hare 86
9. Aneurism of the arch of the aorta, with enormous hypertrophy of the heart . . . . By Dr. James Tyson 88
10. Aneurism of the abdominal aorta . By Dr. J. C. Wilson 88
11. Extensive atheroma of the circle of Willis and cerebral arteries By Dr. Wharton Sinkler 90
12. Hypertrophy of the heart; pericarditis, with enormous thickening of the pericardium . By Dr. Wharton Sinkler 92
13. Patulous foramen ovale, and thickened and attached pericardium By Dr. Wharton Sinkler 93
14. Extensive disease of mitral valves; auricular vegetations By Dr. Wharton Sinkler 93
15. A case of rupture of the heart, and post-mortem muscular spasms . . . . . By Dr. W. W. Keen 94
16. Acute pericarditis: hypertrophy of heart from previous disease By Dr. Wm. Pepper 95
17. Aneurismal perforation of the trachea By Dr. R. M. Bertolet 96
18. Aneurism of the aorta, with supposed rupture of the heart By Dr. John Guitéras 97
19. Dilated heart; pleuritic effusion in a patient who had yellow fever two years previous to death By Dr. John H. Packard 100
20. Aneurism of the innominate artery; obstruction in the larynx; tracheotomy . . . . By Dr. John Guitéras 103
21. Aneurism of abdominal aorta . By Dr. James Graham 105
22. Aneurism of abdominal aorta . By Dr. W. G. Porter 106
23. Punctured wound of chest-wall, with incised wound of aorta By Dr. Edw. L. Parks 106
24. Rupture of external iliac artery—death on twelfth day from internal hemorrhage . By Dr. John Ashhurst, Jr. 107
25. Rupture of the aorta . . By Dr. W. G. Porter 111

IV.—THE RESPIRATORY SYSTEM.

PAGE

1. General tuberculosis, with enlarged lymphatics
By Dr. J. G. Richardson, for Dr. A. Fricke 113
2. Papillomatous growths in the larynx of a child
By Dr. R. M. Bertolet 113
3. Hydrothorax, from chronic subacute pleurisy; fatty degeneration of the heart, and incipient cirrhosis of the kidneys; paracentesis, followed by great relief; return of pleurisy; death from ulceration of colon . By Dr. Wm. Pepper 116
4. Pseudo-membranous laryngitis . By Dr. Oscar H. Allis 119
5. Lungs from a case of acute catarrhal pneumonia with secondary miliary tuberculosis of the pleura By Dr. James Tyson 120
6. Chronic pleurisy with phthisis . By Dr. De F. Willard 122
7. Albuminoid expectoration . . . By Dr. Wm. Pepper 124
8. Portion of lung from a case of pulmonary phthisis, with cavities (bronchiectatic?), hæmoptysis, death from asphyxia. Enormous clot of blood in a large cavity in right lower lobe
By Dr. Wm. Pepper 125
9. Cast from a bronchial tube . . By Dr. J. Solis-Cohen 126
10. Abscess of the lung . . . By Dr. John Guitéras 127
11. Tubercular ulceration of the larynx and trachea
By Dr. R. M. Bertolet 129
12. Lungs from a case of empyema . . By Dr. F. P. Henry 135
13. Larynx of a man strangled with a piece of meat, together with the bolus
By Dr. Edw. L. Parks, for Dr. F. F. Maury 137

V.—THE GENITO-URINARY APPARATUS.

a. KIDNEYS, BLADDER, ETC.

1. Cystic kidneys; tubercular phthisis; ulceration of stomach and intestines . . . . By Dr. De F. Willard 139
2. Cirrhotic kidneys, with enormous hypertrophy of the heart
By Dr. James Tyson 140

PAGE

3. Tuberculosis of the kidney—Peculiar worm-like bodies from the urine of the same case
By Dr. R. M. Bertolet, for Dr. Thomas B. Reed 142
4. Contracted kidneys and hypertrophied heart
By Dr. F. P. Henry 147
5. Cystic kidneys; obstruction by enlargement of the lateral lobes of the prostate gland
By Dr. W. H. Parish, for Dr. C. M. Harris 148
6. Soft cancer (encephaloid) of the kidney and of the lumbar glands (?) . . . . By Dr. James Tyson 148
7. Latent cirrhosis of kidneys without albuminuria or dropsy; hypertrophy of heart; dyspnœa; sudden death
By Dr. Wm. Pepper 150
8. Kidney from a case of hæmaturia in an infant
By Dr. J. G. Richardson 151
9. Calculus, bladder, ureters, and sacculated kidneys
By Dr. W. G. Porter, for Dr. J. G. Allen 152
10. Vesical calculus of small size, producing marked symptoms
By Dr. John Ashhurst, Jr. 153

b. FEMALE ORGANS OF GENERATION.

11. Ovarian tumor . . . By Dr. H. Lenox Hodge 154
12. Ovarian tumor removed by ovariotomy
By Dr. H. Lenox Hodge 154
13. Ovarian tumor of the left ovary, and a tubal dropsy of the right Fallopian tube . . . By Dr. H. Lenox Hodge 154
14. Fluid removed from a cyst of the broad ligament
By Dr. H. Lenox Hodge 155
15. Ovarian tumor . . . . By Dr. F. P. Henry 156
16. Medullary carcinoma of the left ovary
By Dr. J. Ewing Mears, for Dr. W. W. Keen 157
17. Cancer of the uterus . . By Dr. John H. Packard 164
18. Fibroid tumor of the uterus
By Dr. James Tyson, for Dr. Francis L. Haynes 165
19. Epithelial tumor of the vagina . By Dr. J. Ewing Mears 166
20. A case of atresia vaginæ . . . By Dr. H. S. Schell 168

c. MALE ORGANS OF GENERATION.

21. Medullary sarcoma of the testicle, with undescended testicle
By Dr. R. M. Townsend 172

PAGE

22. Cystic medullary cancer of testicle
By Dr. W. S. Forbes 175
23. Chylous fluid from a hydrocele
By Dr. H. Lenox Hodge, for Dr. C. H. Masten 176
24. Epithelial cancer from urethra
By Dr. J. Ewing Mears 178

VI.—THE NERVOUS SYSTEM.

1. Cerebral hemorrhage . . By Dr. John H. Packard 179
2. Cerebral hemorrhage . . By Dr. John H. Packard 180
3. Tuberculous deposit at base of brain
By Dr. John H. Packard 181
4. Sclerosis of the spinal cord, with atrophy of the motor cells in the anterior horns of the gray substance
By Dr. R. M. Bertolet 182
5. Myxomatous neurome of the brachial plexus
By Dr. R. M. Bertolet 188
6. Multiple myxoma of the spinal cord
By Dr. R. M. Bertolet 189
7. Clot in left corpus striatum . . By Dr. Wm. Darrach 190
8. Extensive subcranial extravasation, which complicated a fissured fracture of the skull . By Dr. Richard A. Cleemann 191

VII.—THE ORGANS OF SPECIAL SENSE.

1. Aural polyp . . . . . By Dr. C. H. Burnett 197
2. Polypi from the ear, with portions of a necrosed incus
By Dr. C. H. Burnett 199
3. Bead removed from meatus auditorius externus
By Dr. C. H. Burnett 201
4. Keratosis obturans . . . By Dr. C. H. Burnett 201
5. Gunshot wound of the eye: excision of the eyeball
By Dr. John Ashhurst, Jr. 203

VIII.—DISEASES OF THE SKIN.

PAGE

Description of a specimen of lupus vulgaris
By Dr. Louis A. Duhring 205

IX.—DISEASES OF THE DUCTLESS GLANDS.

1. Adenoid disease . . By Dr. James H. Hutchinson 208
2. Diseased supra-renal capsules from a case of Addison's disease
By Dr. F. P. Henry 211
3. Tumor of the thyroid gland . By Dr. John H. Packard 213
4. Enormously enlarged spleen . . By Dr. W. G. Porter 214

X.—TUMORS NOT OTHERWISE CLASSIFIABLE.

1. Hard cancer of the mamma . By Dr. John H. Packard 218
2. Hard cancer of the mamma By Dr. J. Ewing Mears 218
3. Hard cancer of the mamma By Dr. John Ashhurst, Jr. 220
4. Fatty tumor from the region of the scapula
By Dr. C. B. Nancrede 220
5. Angeioma with sarcomatous degeneration
By Dr. L. A. Duhring 223
6. Sebaceous cyst from the temporal region
By Dr. John Ashhurst, Jr. 226
7. Lipoma . . . . . By Dr. John Ashhurst, Jr. 226
8. Lipoma . . . . . By Dr. H. Allen 226
9. Solid enlargement of the bursa patellæ
By Dr. John Ashhurst, Jr. 227
10. On the anatomical differences between carcinoma, sarcoma, etc.
By Dr. John Ashhurst, Jr. 227
11. Epithelioma of the lip . . By Dr. C. B. Nancrede 229
12. Cystic mammary tumor . By Dr. John Ashhurst, Jr. 230

XI.—MISCELLANEOUS.

PAGE

1. The anatomical, pathological, and surgical uses of chloral By Dr. W. W. Keen 232
2. Wad of paper and cloth removed from lacerated wound of the leg . . . . . By Dr. J. Ewing Mears 241
3. Supernumerary toe . . By Dr. John Ashhurst, Jr. 242
4. So-called hermaphroditism . . By Dr. John M. Keating 242
5. Monstrosity. Case of malformation of the nose By Dr. Ferdinand H. Gross 243

XII.—SPECIMENS FROM THE LOWER ANIMALS.

1. Trichina spiralis . . . By Dr. R. M. Bertolet 251
2. Cystic liver from a rat By Dr. A. C. W. Beecher, for Dr. Isaac E. Roberts 252
3. Sponge-like bodies from synovial cyst in a cow By Dr. J. C. Wilson 252

REPORTS OF THE COMMITTEE ON MORBID GROWTHS.

1. On Dr. J. Ewing Mears's case of osteo-sarcoma of the lower jaw, involving the ramus, angle, and a portion of the body . 12
2. On Dr. John H. Packard's case of viscera from a case of amputation of the breast 32
3. On Dr. J. Ewing Mears's case of sarcoma involving the parotid gland and masseter muscle 41
4. On Dr. A. C. W. Beecher's case of gummata in the liver . 59
5. On Dr. Leonardo S. Clark's case of epithelial cancer of the rectum 62
6. On Dr. Wharton Sinkler's case of thickening of the pericardium 92
7. On Dr. W. G. Porter's case of rupture of the aorta . . 112

PAGE

8. On Dr. Wm. Pepper's case of the button-like prominence upon the inner wall of the pulmonary cavity 126
9. On Dr. De F. Willard's case of cystic kidneys; tubercular phthisis; ulceration of stomach and intestines . . . 140
10. On Dr. John H. Packard's case of cancer of the uterus . . 165
11. On Dr. H. S. Schell's case of atresia vaginæ . . . 172
12. On Dr. W. S. Forbes's case of cystic medullary cancer of testicle 176
13. On Dr. J. Ewing Mears's case of epithelial cancer from the male urethra 178
14. On Dr. C. H. Burnett's case of aural polyp 198
15. On Dr. F. P. Henry's case of supra-renal capsules . . 213
16. On Dr. John H. Packard's case of tumor of the thyroid gland 213
17. On Dr. W. G. Porter's case of enormously enlarged spleen . 217
18. On Dr. J. Ewing Mears's case of hard cancer of the mamma . 219
19. On Dr. Harrison Allen's case of lipoma 227
20. On Dr. J. Ashhurst, Jr.'s, case of solid enlargement of the bursa patellæ 227
21. On Dr. J. Ashhurst, Jr.'s, case of cystic mammary tumor . 231
22. On Dr. A. C. W. Beecher's case of cystic liver from a rat . 252

REPORTS OF SPECIAL COMMITTEES.

1. On Dr. W. G. Porter's case of calculus 153
2. On Dr. H. Lenox Hodge's specimen of ovarian tumor of the left ovary, and a tubal dropsy of the right Fallopian tube . 155
3. On Dr. John Ashhurst, Jr.'s, case of gunshot wound of the eye 203
4. On Dr. John M. Keating's case of so-called hermaphroditism . 242
5. On Dr. Ferdinand H. Gross's case of monstrosity; malformation of the nose; abnormalities of brain 243

LIST OF ILLUSTRATIONS.

		PAGE
Fig. 1.	Sarcoma of the orbit. Drawn by Dr. C. B. Nancrede .	4
Fig. 2.	Congenital imperforation of duodenum. Drawn by Dr. John M. Keating	38
Fig. 3.	Rupture of external iliac artery. Drawn by Dr. John Ashhurst, Jr.	110
Fig. 4.	Atresia vaginæ. Drawn by Dr. H. S. Schell . .	171
Fig. 5.	Sclerosis of the spinal cord: transverse cut of the spinal cord through the lumbar enlargement. Drawn by Dr. R. M. Bertolet	183
Fig. 6.	Infantile spinal paralysis: transverse cut of the spinal cord through the lumbar enlargement. Drawn by Dr. R. M. Bertolet	184
Fig. 7.	Tumor of the sternum, from Dr. Hutchinson's case of adenoid disease. Drawing from a photograph .	209
Fig. 8.	Tumor surrounding dorsal vertebræ, from the same case	210
Fig. 9.	Spinal cord compressed by tumor, from the same case .	210
Fig. 10.	Section of angeioma with sarcomatous degeneration. Drawn by Dr. A. Van Harlingen	224
Fig. 11.	View of head of Dr. F. H. Gross's monstrosity before dissection	244
Fig. 12.	The brain viewed from above, same case . . .	245
Fig. 13.	The brain viewed from below, same case . . .	246
Fig. 14.	Profile view of the brain seen from the right, same case	247
Fig. 15.	Profile view of the brain seen from the left, same case .	248
Fig. 16.	Profile view of the imperfect inter-orbital septum seen from the left. All the illustrations in this case were drawn by Dr. J. M. Keating	249

REPORT.

I.—THE OSSEOUS SYSTEM.

1. *Case of small round-celled sarcoma.*

By Dr. Charles B. Nancrede.

The patient, Lizzie H., æt. 13 years, first complained of pain in the right side of the thorax, which ceased within forty-eight hours, and then recurred only after the lapse of two or three weeks. On examination by her mother, a small tumor, the size of a hazel-nut, was found about the middle of the outer surface of one of the lower ribs, probably the seventh. I first saw the patient on November 14th, 1872, at the University of Pennsylvania, where I was then acting as Dr. Strawbridge's chief of clinic. She then had diplopia, owing to paralysis of the external rectus of the right eye, and also suffered from pains over the right brow and side of the head. The diagnosis then made was that of intracranial tumor, compressing the right abducent nerve. At a subsequent visit, she complained of "the lump in her side,"—now increased to the size of a hen's egg,—which was diagnosed by Prof. Agnew, Dr. W. F. Norris, and others, as probably being an enchondroma of the ribs, accompanied by a secondary deposit at the base of the brain, causing the divergent squint. Prof. Agnew declined to remove the tumor of the ribs until the head-symptoms were relieved.

For a month no change in the fundus of either eye could be detected with the ophthalmoscope; later there seemed to be a slight haziness, and some projection of the right papilla. This, owing to a marked astigmatism, was difficult to determine positively. The patient had frequent attacks of headache, lost strength and flesh, and had a capricious appetite; all the while the tumor was increasing and rapidly involving the adjacent ribs.

About January 1st, 1873, œdema of the left eyelid was noticed, varying in degree from day to day. In two weeks' time this partially subsided, and a small tumor at the outer part of the orbit, just beneath the superciliary ridge, was discovered. The latter rapidly increased, displacing the eye downwards and outwards, and was occasionally accompanied by marked œdema of the lids. After each attack of œdema there was a decided increase of the tumor. The vision of the eye was not affected.

During the later part of June, 1873, the same condition supervened in the right orbit: both of the growths enlarging, bulging upwards and outwards the orbital plates of the frontal bone, with protrusion of the eyes, injection of the conjunctiva, and, finally, ulceration of both corneæ. There also commenced at this time a small, soft growth on the vertex. During the latter part of July, 1873, another growth commenced on the right masseter muscle. This increased very rapidly, and extended into the back part of the mouth, where ulceration soon commenced. It became so large, and so involved the muscle, as to cause almost complete closure of the mouth.

During the last three months of life, mydriasis came on in both eyes, commencing in the left, with concomitant loss of sight. From an early period of her illness, she was annoyed by indefinite abdominal pains, preventing sleep, and towards the close of life these became so severe as to require large doses of morphia. At first the general health was good, but latterly deteriorated rapidly. Six weeks before death the patient became totally blind, owing to the destruction of the corneæ from ulceration, and there were repeated hemorrhages from the stumps. For three or four weeks before death there was a slight cough present, and the tumor in the side ulcerated in two places, from which several severe hemorrhages occurred. At this time she also suffered from deafness of the right ear. She died quite suddenly, during sleep, on November 1st, 1873.

In the *post-mortem* of the above case I was assisted by Dr. F. P. Henry, who kindly made for me the following notes:

"A large hemispherical tumor occupied the left anterior half of the frontal bone, and extended below it, so as to involve the orbit and its contents. Its transverse diameter extended from the root of the nose to a little beyond the external angular process of the frontal bone; its perpendicular diameter, from the infra-orbital ridge nearly to the commencement of the hair. The eyebrow crossed the tumor at its centre. A similar tumor occupied the right side of the frontal bone, but was situated more externally, its centre corresponding to the external angular process, with a radius of about an inch. A third smaller tumor was situated over the

right masseter muscle, and, by its growth inwards, had involved the alveolar processes of the superior maxillary bone and caused the loss of one of the molar teeth.

"Both eyeballs were extruded, but the exophthalmos was more marked on the left side. The balls were completely disorganized, a bluish, semi-transparent disk marking the situation of the cornea; but there was nothing resembling a staphyloma.

"On removing the scalp, a number of hemispherical tumors were found beneath the pericranium, varying from the size of a split pea to that of a section of a walnut. These tumors when cut into were yellow-white in color, and of a cheesy consistence. The largest of them was over the posterior fontanelle. There were two on the coronal suture, one in the median line, the other on the right side near the anterior border of the temporal muscle. There was a fourth beneath the left temporal muscle nearly as large as the one over the posterior fontanelle, and a fifth, smaller, at the posterior border of the same muscle. Besides these, there were a number of smaller growths scattered over the cranial surface, from the size of a split pea to that of a section of a filbert. On removing the skull, the largest of these—viz., the one over the posterior fontanelle, those on the coronal suture, and the one beneath the left temporal muscle—were found to be attached to the dura mater, and involved the bone in its entire thickness. The veins covering the convolutions were engorged with blood,—the venous engorgement being more marked over the right hemisphere. The dura mater, beneath the tumors described, was adherent to the brain. With the exception of these adhesions, the brain was healthy. A small amount of fluid, estimated at one drachm, was found in each lateral ventricle. The tumor observed externally on the left anterior half of the frontal bone was found to be adherent to the dura mater at the sphenoidal fissure and its neighborhood, its point of attachment having a diameter of about an inch. The roof of the left orbit was broken open, and its cavity examined. No trace of eyeball, muscles, or nerves was found, the orbital cavity being completely filled by the tumor.

"At the right side of the thorax was a large pyriform tumor, its base extending from the inferior angle of the scapula to the lower border of the ribs, its apex looking outward and projecting from the thorax. It bore a striking resemblance to a mammary gland. At its apex was a circular ulcer nearly an inch in diameter, covered with a grayish-yellow slough; above this was another about half the size, and presenting the same sloughy surface. This tumor was but a portion of a much larger growth, which occupied about three-fourths of the right pleural cavity, displacing the lung

upward and backward, and compressing it to such an extent that its tissue was not readily recognized. The left lung was healthy. Both ventricles of the heart were filled with fluid blood. The liver occupied a lower position than normal, being apparently crowded down by the tumor in the thorax.

"On microscopic examination were found the ordinary cell-elements of small round-celled sarcoma,—viz., round, and, in some portions, spindle-shaped, nucleolo-nucleolated cells, imbedded in a delicate, faintly-fibrillated stroma."

There are several points of interest connected with this case, to which I shall briefly refer. According to Knapp, changes in the ophthalmoscopic appearances of the eye generally accompany intra-orbital growths, and necessarily do so when the optic nerve is involved. But in this case there was no appreciable change in the fundus of either eye, even within a few months of death, although there must necessarily have been pressure exerted by the growths on the optic nerves. Again, notwithstanding the great amount of disease discovered in the right pleural cavity after death, there were no ante-mortem symptoms beyond dyspnœa and a slight cough,

Fig. 1.

which only came on about three weeks before death. In addition to these slight symptoms, at one time I detected what I thought to be a fluid effusion in that side of the chest; for there was dulness on percussion and absence of respiratory murmur at least two inches higher than a subsequent exploration revealed.

As regards the frequency of such cases, I have carefully searched through most of the English and French works on diseases of the eye and on general surgery, and have been unable to discover with certainty any similar ones. In two cases—one reported by Abernethy,* the other by Paget†—the growths seemed to have been similar in their site, but neither was secondary to, or contemporary with, other like deposits. I wish to make it clear that I do not refer to recidives after extirpation of the eyeball, for they are common. Many of the cases I have met with in my reading, especially among writers of the earlier part of this century, that have been classed as encephaloid, seem to have been really sarcomata. Galezowski refers to Nélaton's Clinical Surgery as mentioning several; but, on examining the record, they are found to be described as encephaloid. Owing to no description of their microscopical appearances being given, I think it best to pass them over.

The drawing was made about two months before death. When this took place, the morbid changes were still more marked.

January 8th, 1874.

---

2. *Intra-capsular fracture of the femur.*

By Dr. O. H. Allis.

The specimen was derived from a female 77 years of age, who had fallen on the sidewalk. The usual symptoms were present, though crepitus was too indistinct to be of value in diagnosis.

The person survived the injury but fourteen days.

The specimen represents the fracture as being, *in front*, about half an inch above the *anterior inter-trochanteric line; behind, midway of the neck.* A reflection of the capsular ligament posteriorly holds the head of the bone to the shaft. *January 8th*, 1874.

---

3. *Chronic arthritis—knee.*

By Dr. H. Lenox Hodge.

The specimens were removed to-day by exsection of the knee-joint, at the Presbyterian Hospital. The patient is 16 years of age, and is in good

---

* Surgical Observations on Tumors, etc., p. 43. London, 1811.

† Paget's Lectures on Surgical Pathology, p. 469.

condition. He has suffered from arthritis of the right knee for about five years. A year ago he was in a hospital for three months, under treatment by rest and counter-irritants, without permanent benefit. Since then he has suffered much pain, and been obliged to use crutches when he moved about.

The semilunar cartilages have been completely destroyed, and in several places the articular cartilages on both the femur and tibia, and at these positions the bone is carious. Upon making the sections with the saw, the bone above the joint was found softened. The patella and its cartilage are less diseased than the femur and tibia.

I would ask the opinion of the members as to the probable cause of the complete destruction of the semilunar cartilages.

Dr. John Ashhurst, Jr., said that, according to his experience in those cases in which the disease originates in the synovial membrane, particularly in cases of gelatinous arthritis, the seminular cartilages disappear at a comparatively early period; whereas in those cases in which the disease originates in the extremities of the femur and tibia the articular cartilages suffer more, and the seminular cartilages are found comparatively unaltered.

February 26th, 1874.

---

4. *Epulis.*

By Dr. R. M. Bertolet.

It is through the kindness of Dr. Thomas Stellwagen that I am enabled to exhibit this tumor to the Society. We have here a bicuspid, removed from the lower jaw, to which a fragment of the alveolar process is seen firmly united. The tooth was removed from a middle-aged lady, and with its extraction ended what had been, no doubt, a very bad toothache, for there is attached to it a pear-shaped, distinctly nodulated growth, which upon closer inspection is found to arise not from the tooth, but from the periosteum of the adherent bone.

The tumor is half an inch in length, and measures a quarter of an inch in diameter at its widest part: it is covered with a dense capsule of connective tissue, which at a few points is beginning to undergo calcification. The interior of the growth is filled with a soft, reddish substance, throughout which an imperfectly radiating, denser substance can be seen by the unaided eye.

The microscopic examination shows the structure to be composed of

round nucleated cells, many seen as apparently free nuclei; there are also present numerous giant or myeloplaxic cells, *i.e.*, irregularly-shaped parent-cells of enormous size, containing each from five to twelve daughter-cells. Spindle-shaped cells are also seen, but the round-celled variety predominates. Of these appearances, the existence of the multinuclear giant-cells alone suffices to disclose the sarcomatous nature of the epulis. The fact that the so-called epulides belong to the class of sarcomata was first pointed out by Virchow. They are more frequently found upon the lower than upon the upper jaw, where they may attain, when not interfered with, quite a considerable size. It is seldom that these growths are seen at such an early period of their existence and removed with the same facility as happened in this instance. The interest attached to this specimen lies in the fact that although the tumor unquestionably starts from the periosteal layer of the bone, yet its growth has been inwards at the expense of the cancellous tissue, which has been partially absorbed, and a cavity formed, out of which the tumor is readily lifted. The base of the tumor being opposite the neck of the tooth, it becomes an easy matter to conceive how the less-resisting cancellated structure necessarily first yielded to the gradual expansion of the tumor, which was thus made to assume a position as though it were a central osteo-sarcomata, when in reality it pertains to the periosteum and not to the medullary portion of the bone. The presence of the multinuclear giant-cells does not in the least militate against the view of the periosteal origin of the tumor, since they are found in the periosseous as well as the intraosseous sarcomata of bones generally.

March 12*th*, 1874.

---

5. *Multiple gummata of the cranial bones and dorsal vertebræ, giving rise to extensive destruction of these structures, leading to compression of the spinal cord and inducing paraplegia.*

By Dr. R. M. Bertolet.

The accompanying skull and spine were removed from the body of a patient who died at the Philadelphia Hospital. Owing to the low condition of the man when admitted, and to the fact that he was unable to speak any but his own language, very little could be ascertained as to his previous history. Drs. Miller and Keating, resident physicians to the hospital, have, however, kindly furnished me with the clinical records of the case, from which the following summary has been made:

"Edward P., æt. 34, a native of Poland, was admitted into the hospital October 14th, 1873. He complained of dull pain in the back, and of obstinate constipation. Stated that he had had gonorrhœa several times, aad when quite young had a sore on the penis. Did not recollect having had any secondary manifestations. In all other respects had been a very healthy man.

"The patient was at once put upon iodide of potassium, and improved somewhat for several weeks. In December he began to complain of pain in the region of the kidneys, and tube-casts were detected in his urine. He was then placed under treatment for his renal troubles, the iodide of potassium being discontinued. During the following month the pain in the back became so intense that he was carefully examined for aortic aneurism; but no evidences of such a condition could be detected.

"About six weeks before his death (February, 1874), gradual loss of both motion and sensation were noticed in both legs, finally amounting to complete paraplegia. The obstinate constipation persisted throughout, but the bladder was controllable."

No further records of the *autopsy* were preserved than these specimens, yet they in themselves are of sufficient interest to merit further study. The skull, which is so freely riddled with more or less complete perforations of various sizes, presents no other evidences of syphilitic alterations than those occurring in the immediate neighborhood of the gummata. Many of these growths can still be seen hanging loosely in these circular cavities, while the peripheral bony margins show an inflammatory process of hyperostosis and sclerotic thickening to be going on. A directly opposite process, leading to rarefaction and atrophy of the bony structures, has been induced in the centre by the pressure of the gradually-expanding tumors. At numerous points, where the perforation through both compact bony layers is incomplete, it will be seen that the erosion extends now more towards the external periosteal surface, while at other places again the pressure of the gummata has evidently been greatest in the direction of the cranial cavity, leading to absorption of the endocranial plate, the external covering remaining intact. There can be little question that in this instance the seat of these syphilitic gummata has been in the diploë, and not sub-periosteal, a fact which goes far towards explaining why their presence was not manifested during life, neither by any elevations beneath the integumentary coverings, nor by any ulcerations in the same.

Upon the anterior surface of the spinal column no less than six large, round, circumscribed tumors are seen. Their presence in this situation has likewise given rise to extensive destructive inflammation. The second

dorsal vertebra has been almost completely broken down, permitting a very decided bending of the spinal column at this point. The presence of one of these growths upon the surgical neck of the third rib upon the right side has led to such extensive destruction that a fracture at this portion of the rib has occurred.

Upon the posterior aspect of the spine but two of these tumors are seen: one is situated upon the left side of the fifth and sixth dorsal vertebræ, the other upon the right side of the ninth. At both points the growths protrude so far into the cavity of the spinal canal as to press firmly upon the spinal cord. In the latter, extensive gray degeneration of the posterior and lateral columns has taken place. The microscopic appearances of these alterations will be described upon a future occasion.

The sections of the gummata show, at many points, commencing cheesy degeneration. Sections made through specimens hardened in bichromate of potash show that there is a concentric arrangement around the thickened blood-vessels of the highly corpuscular parenchyma of the tumor. Bands of connective-tissue fibres are seen coursing through the field at wide intervals, the interstices between them being completely filled with small, round, corpuscular elements. *March* 12*th*, 1874.

---

6. *Chronic arthritis—wrist.*

By Dr. H. Lenox Hodge.

The specimens were removed this day at the Presbyterian Hospital, on account of chronic arthritis of the wrist. The patient is a man about 35 years of age, who has suffered from chronic arthritis for the last two years. The pain has been very great. Abscesses have formed and have been discharged on the back of the hand, on the front of the fore-arm, on the palm of the hand, and on the palmar surfaces of thumb and forefinger. The excision was done after Lister's plan. The lower ends of the ulna and radius, including the radio-ulnar articulation, the whole carpus except the pisiform bone and the hooked process of the unciform, and the carpal extremities of the metacarpal bones of the forefinger and third finger, were removed. The carpal extremities of the metacarpal bones of the thumb and of the fourth and fifth fingers were healthy, and, contrary to Lister's recommendation, were allowed to remain. In excision of the knee-joint no harm results from leaving part of the femur covered with its cartilage if healthy. It was therefore thought that in the case of the wrist also,

healthy bone covered with sound cartilage could be left without danger, and that these carpal extremities of the metacarpal bones would add to the future usefulness of the hand. Above the section made by the saw there was an abscess in the radius: to this the gouge was freely used.

Such extensive disease of the wrist is comparatively rare. It is the first case which I have seen in which I thought excision necessary. In this case, as well as in a number of others of similar nature, I have made use of Esmarch's apparatus for the prevention of hemorrhage, with great satisfaction. There was no bleeding during the operation, and no ligature was requisite after the elastic band was removed. All tendency to hemorrhage was arrested by dry lint.

Dr. Allis asked whether new sheaths are formed over these exposed tendons after this operation, and whether they are lubricated by the same fluid as in health.

Dr. Hodge said he had avoided opening the sheaths when he could. The tendons which were divided, and of which the sheaths were, therefore, also divided, were the extensors of the wrist, the two radial, and the ulnar. One portion of the common flexor of the fingers was also partly exposed, but not so as to interfere with its sheath. The tendons were divided at the extremity of their insertion, and therefore the lubrication of the sheath would remain in its totality. The one most difficult to avoid is the ulnar extensor, and he was therefore careful to cut between it and the bone, and thus to preserve all its surrounding structures. He thought that if this operation was carefully performed, the sheath of the tendon would not be injuriously interfered with. *April* 23*d*, 1874.

---

7. *Hip-joint disease; the head and neck of the femur, removed by excision, —the head found separated from the neck by ulceration.*

By Dr. H. Lenox Hodge.

The patient is a delicate, pale, emaciated lad, 7 years old. About four months ago he fell, but was able to walk about that day. The next day he was obliged to remain in bed. An abscess formed, and discharged behind the great trochanter. The limb became shortened, and the inclination of the pelvis very marked. The knee is partially anchylosed, but there was a remarkable degree of motion at the hip for a case of arthritis. Excision was done at the Children's Hospital, May 6th, and the head of the

femur was found entirely separated from the neck, and lying in a pocket in the gluteal muscles above the great trochanter. The neck pressed against the acetabulum, and in the excision was removed as usual below the trochanters. This separation of the head by ulceration is rare, and accounts for the unusual motion at the hip prior to the operation. The case is interesting also on account of the short period in which this extensive destruction of bone appears to have resulted.

Dr. John Ashhurst, Jr., said that this case appeared to have been one of the variety which systematic writers called *femoral coxalgia*,—*i.e.*, a case in which the disease originated in the extremity of the femur rather than in either the synovial membrane or the acetabulum. It was, he believed, in such cases that separation of the femoral head was most apt to occur, the destructive process affecting chiefly the neck of the bone, which was unprotected by cartilage; whereas in the form of hip-disease known as *articular coxalgia* the head of the femur might be almost completely disintegrated, while the remnant yet remained firmly attached to the shaft. *May* 14*th*, 1874.

---

8. *Exostosis of lower jaw.*

By Dr. John Ashhurst, Jr.

The specimen was removed from the lower maxilla of a young girl. The tumor grew from the base of the jaw on the left side, near the angle of the bone, projecting downwards and outwards, and causing quite a marked deformity. The growth, which was pedunculated, was removed without external incision, the operation consisting in freely dissecting off the cheek from the bone, through the mouth, and then severing the attachments of the tumor with strong cutting-forceps. The great advantage of this plan of proceeding was that the wound required no dressing, and that there was left no external scar. The exostosis was of the cancellous variety, and, as often happens with these growths, was covered on its external surface with an adventitious bursa. *June* 10*th*, 1874.

9. *Osteo-sarcoma of the lower jaw, involving the ramus, angle, and a portion of the body.*

By Dr. J. Ewing Mears.

The specimen was removed from a boy æt. 14. In this case the diagnosis was sarcoma, the jaw presenting the stony hardness of such growths. But the diagnosis in this situation is at all times difficult. Where the lymphatics over the parotid are the seats of disease, the movability of the growth aids a decision. Last summer I removed a tumor, as large as a Sicily orange, from directly over the parotid, and am confident that it did not involve the gland, from this circumstance.

September 10*th*, 1874.

Report of the Committee on Morbid Growths:

"The series of small tumors removed by Dr. Mears from a patient æt. 14 present, as suspected, the well-known microscopic appearances of the round-cell sarcoma; but only in such a subordinate manner that your committee, in making this their preliminary report, are inclined to view it as a mere sarcomatous degeneration of the striated muscular fibres which make up the bulk of the growth,—in short, are seen in sections made in every possible direction. Should this prove, upon further investigation, to be the case, then it must be pronounced a *myosarcoma.*"

September 24*th*, 1874.

---

10. *Compound comminuted fracture of the skull, involving both tables, with depression.*

By Dr. J. Ewing Mears.

William McD., æt. 14, was admitted into the surgical wards of the hospital, August 19th, suffering from a wound of the cranium. It was stated that he had sustained the injury at Cramp's shipyard; an iron clamp or dog weighing fourteen pounds falling a distance of thirty feet, his head being struck by the angle of the tool. He was stunned by the blow, but soon regained consciousness, and when admitted he was able to give an account of the injury. Examination revealed a lacerated wound of the scalp over the frontal bone, about one inch from the line indicating the position of the frontal suture. On separating the flaps the bone was found

depressed to the extent of half an inch, and the external table was very much comminuted. Nausea and vomiting were present, the pupils were largely dilated, the pulse slow and full, and respiration was somewhat labored.

Although the symptoms of compression were not strongly marked, I deemed it advisable, in view of the character of the wound, to remove the fragments of bone, and thus avoid the possible dangers of subsequent compression or the occurrence of intra-cranial suppuration.

Owing to the size of the wound of the bone, it was impossible to apply the trephine. After enlarging the wound of the scalp by incisions, the elevator was applied, and the comminuted portions of the outer table, some eighteen in number, were detached. After removing these it was found that the inner table had been pushed off, as it were, *en masse*, leaving a loose fragment much larger in diameter than the opening in the outer table. This fragment, after numerous attempts, was sufficiently dislodged (being pushed aside) to admit of its division by the bone-plyers. The portions were then readily extracted, and the dura mater brought into view; with the exception of a wound of one of the small arteries of this membrane, the hemorrhage from which was easily checked, it was uninjured. The wound was well cleansed by gently injecting cold water, and the incisions in the scalp were closed by wire sutures. The wound was strapped with isinglass-plaster, and covered by compresses wet with ice-water. The head was kept elevated; as soon as the patient recovered from the effects of the anæsthetics, a drop of croton oil was administered. This failing to produce any effect, eight grains of calomel were given, which soon opened the bowels freely. Instructions were given to keep him perfectly quiet, and to continue cold applications to the head; one grain of calomel three times daily was administered. Sloughing of the portion of lacerated scalp occurred, and the dead tissue was removed by the scissors. Healthy suppuration soon took place, and the wound was rapidly filled by granulations.

By September 17th the wound had closed, with the exception of a slight surface about the size of the nail of the little finger. A large depression was left on the surface. The recovery of the patient was uninterrupted.

At first view this wound appeared to partake largely of the character of an *impacted* fracture, and, as such, it was a question not readily decided as to the propriety of operative interference. The symptoms of compression also, as has been stated, were not strongly marked.

The depressed character of the wound produced apprehensions as to the subsequent effects, and seemed to justify the removal of the fragments. The fact that the inner table was found to be detached to so large an ex-

tent, and that there existed a wound of one of the vessels of the dura mater which poured out a quantity of blood, fully confirmed the propriety of removing the bone. The measurements of the fragment from the inner table were found to be in the long diameter 2 inches, in the short diameter $1\frac{5}{8}$ inches; of the external plate in the long diameter $1\frac{3}{4}$ inches, in the short diameter $1\frac{1}{4}$ inches.

The fracture involved the frontal bone, situated about one inch from the line indicating the position of the obliterated frontal suture, and was limited behind by the coronal suture. *September* 23*d*, 1874.

---

11. *Excision of the knee.*

By Dr. John Ashhurst, Jr.

The parts exhibited are the condyles of the femur, the articulating surface of the tibia, the patella, and the remains of the semilunar cartilages. The specimens are exhibited in their recent state (the operation having been performed this morning), as furnishing an excellent illustration of the gelatinoid change which Brodie has described under the name of pulpy, and Swain under that of gelatiniform degeneration. The affection was called by Barwell *strumous*, and by Athol Johnstone *scrofulous synovitis;* but I prefer the name *gelatinous arthritis*, because, while originating in the soft tissues, the disease, if not interfered with, ultimately involves all the structures of the joint. The patient from whom the specimens on the table were derived is a boy about five years of age, who has suffered from the disease nearly two years.

Dr. James Tyson inquired of Dr. Ashhurst whether the "gelatiniform degeneration" here referred to was not, more precisely speaking, an example of the so-called *mucous degeneration* of the pathologists, of which the essential feature was a conversion of the intercellular substance into a transparent mucin-containing material, while the cells themselves remained intact. The seat of the changes in the specimen presented would seem to be that especially selected for this degeneration, *i.e.*, the cartilages and bones.

Dr. Ashhurst replied that, so far as he knew, no one had investigated the minute anatomy of this disease except Mr. Barwell, who regarded the condition as essentially the same as the granulation-change met with in ordinary inflammation. The terms *gelatiniform*, *pulpy*, etc., etc., Dr. A. thought referred to the naked-eye appearances of the parts, rather than to their microscopic characters. *December* 10*th*, 1874.

12. *Head of the femur removed by excision in a case of coxalgia.*

By Dr. J. M. Barton.

Mina F., æt. 10 years, with a decidedly strumous history, has suffered from the usual symptoms of coxalgia for the last fourteen months; suppuration beginning five months ago, and the amount of discharge being quite moderate until the middle of December, when, the child having lost appetite and flesh, hectic fever having appeared, and the discharge from the sinuses becoming quite profuse, excision was determined upon.

On December 22d I excised the head of the femur in the usual manner. The femur was found dislocated upon the dorsum of the ilium, as the deformity indicated. The acetabulum was free from disease, except a small portion of its lower margin, which was readily removed.

The patient did remarkably well for two weeks. Appetite very good; bowels natural; no pain, and the discharge quite moderate in amount; but from this time she gradually sank, and died exhausted, January 11th, twenty days after the operation.

I have here also the upper extremity of the shaft of the femur, removed *post mortem*, showing the efforts at repair. It was nearly in contact with the acetabulum, and its attachments to the pelvis were quite firm.

January 15th, 1875.

---

13. *Compound fracture of skull, multiple fractures of vertebræ and ribs, laceration of spinal cord.*

By Dr. John Ashhurst, Jr.

The patient, a man æt. 22, was brought to the Episcopal Hospital on the morning of April 3d, 1875. About one hour before he had jumped from a train of cars while in motion, striking the parapet of a bridge, and thence falling head-foremost to the ground below. On admission, a small contused wound was found in the scalp, and the latter was separated from the skull over a considerable distance, but no fracture could be detected by the finger. There were slight symptoms of cerebral concussion. Between the scapulæ there was a very severe contusion, with extensive ecchymosis, and a general rounded projection of the spines of the upper dorsal vertebræ. There was complete paraplegia, the loss of sensibility reaching to an inch below the nipple on either side. The temperature of the paralyzed

parts seemed abnormally high to the hand, but was not tested with the thermometer. There was no retention, with partial suppression of urine, but no priapism.

The patient survived about twenty-six hours, having become comatose a short time before death.

An *autopsy*, which was unavoidably hurried, was made thirty hours after death, and revealed an extensive stellate fracture of the left parietal bone, with slight depression of the outer and greater depression of the inner table. The meninges were congested, but not lacerated, and the brain was normal. There were comminuted and partially impacted fractures of the bodies of the fourth, fifth, sixth, seventh, and eighth dorsal vertebræ, with fractures of the heads of the corresponding ribs on either side. The fourth dorsal vertebra was displaced towards the right, and at a point corresponding to the junction of the third and fourth vertebræ the spinal cord was almost completely severed, its continuity being maintained by means of a mere shred on the right side. The spinal meninges were much congested, and a spicula of bone was found in the substance of the cord. The vertebral canal contained a large quantity of fluid blood. The other organs of the body were not examined.

The notes were furnished by Dr. J. C. Merrill. *April* 22*d*, 1875.

---

14. *Fracture of the skull.*

By Dr. W. S. Forbes.

James McG., æt. 22 years, was admitted to the surgical ward of the Episcopal Hospital on the 16th of April. He walked to the hospital from his home, several squares distant. He had been in the dispensary of the hospital three days before, and stated that in a fight he had received a blow on the side of his head with a stick. He was advised to come into the house at once, but declined doing so.

When he entered on the evening of the 16th, he was found to have a compound fracture, with slight depression, at the anterior inferior angle of the left parietal bone. During the evening he was dull and stupid, but could be aroused when urged; and, while he could not pronounce his name, he could write it on a slate, and answer intelligently in monosyllables. He was given a purge, and a pledget of lint was placed over his wound, with directions to be kept quiet in bed.

When I saw him, for the first time, on the morning of the 17th, four days after the accident had taken place and some fourteen hours after he had entered the house, there were no symptoms of depression, and he was perfectly rational.

He was ordered one-fourth of a grain of calomel every four hours, counter-irritation to the nape of his neck, dry cold to the top of his head, and the wound to be dressed with wet lint covered with oiled silk, and low diet to be given. Under this treatment he continued to remain very well.

On the morning of the 23d there was a very slight expression of facial paralysis on the left lower side of the jaw and corner of the mouth. One-fourth of a grain of opium was added to the calomel.

On the morning of the 25th his condition was all that could be desired under the circumstances. Normal pus came from the wound, moderate in quantity; he had no pain, his skin and pulse in good condition. Early on the morning of the 26th there was a sudden change for the worse. The respiration became stertorous, the pulse rapidly rose to 154, and was intermittent in a marked degree; a red, frothy matter flowed freely from the right nostril, coma set in, he became cyanosed, and died on the morning of the 26th, about ten o'clock, thirteen days after his accident.

An examination was made twenty-six hours after death. The membranes of the brain were somewhat congested; there was a depressed, stellated fracture beneath the external wound; the internal table of the bone was found extensively fractured, and more depressed than the external table, but there was no unusual expression of inflammatory action in the neighborhood of the fracture.

The left ventricle was filled with serum and some pus. There was a large abscess in the posterior part of the right cerebral hemisphere.

April 22d, 1875.

---

15. *Fracture of the cranium.*

By Dr. Edw. L. Parks.

T. W., 37 years old, born in Scotland, was brought, intoxicated, to the Philadelphia Hospital the 2d day of last May. When seen by the resident physician at 2.30 in the afternoon, he was asleep, and was not aroused. When seen again in the evening of the same day, he was still unconscious. Pulse 84, pupils slightly contracted. "He appeared," writes the resident physician, "like one who had been drinking to excess and engaged in a drunken brawl."

He remained unconscious till the evening of the next day (May 3d), when he gave his name, complained of headache, and answered some questions intelligently, though he could not tell how he had been hurt. There was much tenderness over the whole surface of the head. Pupils continued contracted, as they had been since his admission. There was an effusion of blood into both eyes, around the orbits, and over the right mastoid process.

In the afternoon of Tuesday, 4th, he began to relapse into unconsciousness.

Wednesday, 5th, he was quite conscious, and complained of a severe headache.

Thursday, 6th, he complained of severe pain, radiating from the temples over the forehead. His mind was clear, and he had perfect use of all his limbs. His pulse had been gradually falling since his admission, and on the evening of this day was 54 beats a minute; respiration, 18; temperature, 98°.

Friday, 7th, morning, his hands and feet were cold, pulse 50, and there was slight ptosis. Great restlessness during the day. In the forenoon he lost control of his sphincters. In the afternoon he became quite unconscious. At noon his temperature was 100°; at 7 o'clock in the evening his temperature was 102°, pulse 98, respiration 26, with complete loss of motion and sensation.

He died at 8.30 P.M., five days after admission.

When first seen, he was ordered fifteen grains of blue mass. Subsequently, blood was twice taken by cups from the back of the neck and from the temples, with marked relief each time. Blisters and ice were also used.

At the coroner's inquest, it was ascertained that he was pushed violently backwards from the door of a drinking-saloon, and fell, striking his head against the pavement.

From the notes of the *post-mortem* examination we select the following:

"On removal of scalp, crown was seen to be discolored by blood. Temporal fascia of left side was injected, also the whole posterior aspect between scalp and pericardium.

"A fracture was seen, which commenced at centre of skull, above the external occipital protuberance, and passed irregularly but directly to right side of skull, ending at junction of squamous portion of temporal bone. There was a free escape of bloody serum before removing the skull-cap. After removal of skull-cap, the fracture was found to traverse the skull from the inferior angle of the parietal bone of one side to that of the

other. The length of the fracture, by actual measurement, was twelve inches.

"Brain was injected, and clots found in its substance, and a large coagulum was found in the anterior portion of the cranial cavity. A clot on the left side was very adherent, and was semi-organized.

"The ventricles were normal. There were evidences of softening around the seat of injury; also a large abscess on left side.

"Cerebellum normal.

"Cause of death, fracture of skull, as described, followed by an effusion of blood into the cranial cavity."

This case is valuable for several reasons: the length of the fracture, and the symmetry of the injuries to each parietal bone. Though strongly suspected, the fracture was not distinctly recognized during the life of the patient. Nor should we expect otherwise, since the clear-cut edges were held in close apposition by the scalp, occipito-frontalis muscle, temporal fascia, and periosteum, aiding the natural position of the bones. No crepitus, preternatural mobility, or deformity was to be found to point out that there was a fracture. *June 24th*, 1875.

II.—THE DIGESTIVE APPARATUS.

1. *Obstruction of the bowel.*

By Dr. Morris Longstreth.

The specimen was removed from the body of a young man who died shortly after admission to the Pennsylvania Hospital. He had been ill on board ship about ten days, with obstinate constipation, apparently arising, so far as the history could be obtained from his friends, from some obstruction of the bowel, but had received no treatment.

At the *autopsy*, the upper two-thirds of the small intestine were found distended to about the size of the colon; the contents were fluid, and the coats congested. In the right renal region there was a sharp twist, the tube being bent directly on itself, and it was at this point bound by a slight inflammatory band, which prevented any movement of the bowel and maintained a perfect occlusion of the intestine. There were a few inflammatory adhesions in the neighboring parts, but these other bands did not seem to make such perfect obstructions as the one previously mentioned. The calibre of the lower part of the intestinal tube was much reduced in size. The colon contained considerable solid matter of a whitish color.

January 22*d*, 1874.

---

2. *Enlarged spleen and cirrhotic liver.*

By Dr. Morris Longstreth.

G. H., æt. 50; single; hatter; was admitted to the Pennsylvania Hospital September 23d, 1873, and died December 4th, 1873. The patient denied that he was syphilitic or intemperate. He had had two severe attacks of malarial fever in Arkansas three years ago; otherwise he had been in good health until June last. At that time he had a very copious hemorrhage; he had subsequently been very weak, but there was no return of bleeding. Anasarca and ascites appeared shortly afterwards. No urinary symptoms were noticed.

On admission, spleen was found to measure four inches in transverse diameter; abdomen distended; heart and liver displaced upwards. On October 6th, vomited blood,—about eight ounces; and this recurred several times.

November 4th.—Abdomen increasing in size; some decrease in hepatic dulness found. Splenic dulness began as high as the fifth rib. Microscopically it was thought the blood showed an increase of white blood-corpuscles. Stomach had become very irritable.

November 27th.—Two gallons of fluid were drawn from the abdomen.

Died December 4th, from exhaustion.

Autopsy, made two hours after death.

Thorax.—No morbid appearances to note.

Heart.—Organ was small, and its left ventricle was somewhat hypertrophied.

Abdomen contained a large amount of fluid, it having nearly refilled to its original size after the tapping.

Liver was contracted, hob-nailed, and fissured in places, and weighed three and a half pounds. The fibrous tissue was increased; abundant oil-globules were seen; cells reduced in size, very granular and fatty,—indeed, no cells could be found normal in appearance. On upper surface was a small but deep-puckered depression, from which nearly all traces of cell-structure had disappeared, nothing but the fibrous elements being present, with the interspaces filled with blood, which escaped on section. Connective tissue in the fissure was increased and opaque.

Gall-bladder contained greenish bile; its duct was narrowed but patulous.

Spleen was enormously enlarged, weighing three pounds avoirdupois. The organ rested nearly horizontally under the diaphragm. It had several deep fissures running across its outer surface, and from its upper extremity was a large, projecting mass. Capsule thickened, and trabeculæ very prominent. Its tissue appeared mottled, and under the microscope its granular and corpuscular as well as fibrous and elastic tissue were found enormously increased.

Kidneys were considerably increased in size, and very firm; capsules were quite adherent, and on removal left a granular surface. The organs were very much congested, but their outline was regular. A small cyst was found on the outer edge of the left kidney. Under the microscope the epithelial cells of the tubes were found quite granular, but not fatty, and no casts were discovered. *January 22d*, 1874.

3. *Cancer of the liver.*

By Dr. Morris Longstreth.

E. W., æt. 35, a widow, domestic, was admitted to the Pennsylvania Hospital November 18th, 1873, and died November 23d, 1873.

She had been in poor health for five years, but was without distinctive symptoms of disease until last summer, when she had an attack of vomiting, with loss of appetite. Subsequently she had considerable pain in the abdomen; but this was not a prominent symptom.

On admission, the patient was extremely weak, and it was difficult to make an examination or to obtain any history. The abdomen was much enlarged, and in the right iliac fossa and umbilical region a large mass was felt. She suffered from vomiting; urine was albuminous, very scanty, and contained granular casts with fatty epithelial cells attached.

On the fifth day after admission she was in a moribund condition, and a pretty thorough examination was made. There was dulness from the fourth rib to a point ten inches below, nearly to the ilium. The lower border of the liver could be distinctly made out.

Autopsy, one hour and a half after death.—Body emaciated; no anasarca of cellular tissue.

Thorax,—a few adhesions of pleural sacs on both sides. Lung-tissue everywhere crepitant; near the apex of the right lung was a small calcareous nodule, surrounded by a congested area.

Heart and *vessels* were normal, except a slight thickening of the mitral valve and a few atheromatous patches in the aorta. *Lungs* and *bronchial glands* were blackened by a pigmentary deposit.

Abdomen contained a large amount of blood-stained serum.

Stomach was rather small, and adherent to the surrounding parts. On the lesser curvature were three or four much enlarged and infiltrated glands of soft consistency. These contained no fluid.

Projecting into the cavity of the organ and connected with the enlarged glands was a large granulating mass, fungus-like, with everted edges and a depressed centre. Its surface was uneven, but ulcerated at only one or two points slightly.

Liver was enormously enlarged in all directions, and weighed ten pounds three ounces avoirdupois; the peritoneal coat, though thickened in places, was generally smooth; the right lobe was constricted or depressed at the part corresponding to the costal border. There were no very prominent nodules on the upper surface of either lobe, but the under surface of the

left lobe was considerably nodulated. The lower border of the organ was firm, and generally even. There was no umbilication of any of the nodules. The calibre of the vena cava was somewhat encroached upon, and turned from its normal direction by the enlargement of the organ upwards and backwards. Transverse section of the left lobe revealed irregular cancerous infiltration of the hepatic tissue; the deposit was soft, and yielded little or no juice.

Gall-bladder was moderately distended with greenish bile; cystic, hepatic, and common ducts pervious.

Spleen was of normal size; a few patches of recent lymph on its surface.

Kidneys were of normal size; weight of both, ten ounces. Capsule transparent, and readily removable.

Uterus very small; os the size of a pin's head; probe entered about one inch; no cancerous nodules in any other parts.

January 22*d*, 1874.

---

4. *Rupture of the gall-bladder.*

By Dr. Wm. Pepper.

The specimen was removed from Mr. A., æt. 70 years; of a healthy, long-lived family; had always enjoyed good health until the summer of 1873. For many years he had been of sedentary habits, and, although temperate in the use of stimuli, ate abundantly. About July last he began to be troubled with attacks of severe pain in the epigastrium, attended with vomiting, weakness, discoloration of urine, and distinct, though not extreme, yellowness of skin. These attacks were of short duration, but recurred every week or so. His general health did not seem affected severely, and the nature of his case was not suspected. In December he was seized with intense pain, referred to the right side of the back, below the ribs, and to a point in front about midway between the gall-bladder and the umbilicus. The pain was very intense, and was moderated only by large doses of morphia. There was vomiting, with anæmia, constipation, and deep brownish-red discoloration of urine, which was found to be free from blood, but to contain bile-pigment. It was not tested for biliary acids. After twenty-four hours there was some remission in the severity of the suffering, when a second violent exacerbation occurred. The same partial relief occurred again in twenty-four hours, followed by a third

intense paroxysm, during which he became slightly delirious and struggled to leave his bed. During his violent struggles against the strong restraint which was used to keep him in bed, he suddenly complained of still more intense pain in the right hypochondrium. He then soon sank into a state of collapse, with cold extremities, distended belly, which was tender on pressure, and wandering delirium. Death occurred fifteen hours afterwards, or about seventy-two hours from the beginning of the attack.

At the *autopsy* the abdomen alone was examined. There was general peritonitis, with fine injection of the membrane and adhesions of the coils of the intestines. On separating these, delicate ridges of soft lymph marked the lines of adhesion. There was a large amount of thick, grumous bile in the right hypochondriac region, lying free among the coils of the intestines close to the concavity of the liver. This organ was of full size, and in an early stage of cirrhosis. No lesions of the stomach, spleen, or kidneys were observed. The common bile-duct was greatly dilated, measuring about three-eighths of an inch in diameter. At a point one inch from the intestine a large conical biliary calculus was found impacted. About this point the duct was distended with bile, and on following up its ramifications throughout the liver they were found distended with grumous bile containing numerous coarse, gritty particles of biliary gravel. The gall-bladder was collapsed, and contained only a round, black calculus, three-eighths of an inch in diameter. The walls were thickened and fibrous; the mucous lining was normal, save in one point, just at the beginning of the cystic duct, where there was a perforation which would admit an ordinary probe. The cystic duct was narrow and tortuous, but still patulous for fluids. *January* 22*d*, 1874.

---

5. *Intussusception.*

By Dr. James Tyson.

The specimen of intussusception of the small intestine into the large, through the ileo-cæcal valve, was removed from an infant boy seven months old. On Sunday, January 24th, the child was remarkably bright, playing and romping with his father to an extreme degree. On the following day he had several discharges of blood, but no other matter, from the bowels, and towards evening vomiting set in. In the evening I saw him, and, suspecting the condition at once, directed a dose of oil, followed by small doses of calomel (one-sixth gr. every hour). On the following day injec-

tions were ordered, and the calomel continued, to no purpose. On Wednesday the vomiting almost ceased, but the bowels remained unopened, and there was distinct dulness in the right iliac region. The vomiting returned the following day, there was more discharge of blood from the bowels, and the child died at 4 P.M. on the 29th, having had quite a normal stool immediately before death.

The *post-mortem* examination was made the next day. The abdomen, which was never markedly tympanitic, contained a large amount of fetid sero-sanguinolent fluid. There were peritonitis, and intense injection of the bowel throughout almost its entire extent, and the tumor presented was found at the seat of the ileo-cæcal valve. It was three inches in diameter, and a portion of intensely congested small intestine had passed through the orifice and formed the tumor. *February* 12*th*, 1874.

---

6. *Gall-stone passed by a woman during life.*

By Dr. James Tyson.

The stone is three-eighths of an inch in diameter, a nearly perfect octahedron, with somewhat irregular facets, passed by an unmarried female about 30 years of age. She was jaundiced, her urine was loaded with bile, and she had the usual pain of biliary colic, which was somewhat intermittent, being worse at night. After an unusually severe attack the stools were examined, this stone found, and she rapidly recovered.

February 12*th*, 1874.

---

7. *Multiple intussusception.*

By Dr. A. C. W. Beecher.

The specimen was taken from a child less than fifteen months old, in which there were five intussusceptions (four existing at present, one having been pulled out) in a portion of small intestine two feet in length. They are all invaginated in the same direction, two of them extending fully an inch and one-half. There are no inflammatory deposits or adhesions. There were no symptoms before death pointing to this condition, and I was not looking for it when it was found. I have also found, while resident physician at the Philadelphia Hospital, similar unlooked-for intus-

susceptions in very young children whom I have examined *post mortem*, but not so many invaginations in so short a piece of intestine as this.

February 26*th*, 1874.

---

8. *Multiple intussusception.*

By Dr. Morris Longstreth.

The patient from whom the specimen was taken suffered an injury of the fore-arm, for which amputation was performed. For some time previous to death, which occurred from obscure causes, he had had a profuse diarrhœa. At the autopsy there were found eight invaginations of the small intestine, all occurring in its upper-half portion. The largest was not of a greater extent than three inches, while the smallest was not over half an inch. They were easily reducible, three of them having been pulled out previous to the specimen being brought before the Society. There were no evidences of any inflammatory trouble at these points or at other portions of the abdominal cavity. No lymph or adhesions, nor any congestions, were found in any portion of the intestine.

February 26*th*, 1874.

---

9. *Enormously distended stomach, in connection with caseous consolidation of the left lung, with several abscesses simulating pneumothorax.*

By Dr. Wm. Pepper.

Patrick Q., æt. 45, had been under observation for over a year, suffering with aggravated diabetes mellitus. It was found impossible to restrict his diet, and he habitually ate and drank most inordinately. A few months before his death, symptoms of pulmonary disease appeared, and rapid consolidation of the left lung followed. A little later, the physical signs of a cavity in the left mammary region were detected. At this time his morbid craving for food and drink rapidly diminished, and the amount of urine to the proportion of sugar fell. Some days afterwards it was noticed that the dulness which had been present over the lower lobe of the left lung was replaced by large, metallic, tympanitic percussion-resonance, extending from the base of the thorax up to the fourth intercostal space. The quality and volume of this tympany were carefully compared with the resonance over the left hypochondrium, and appeared distinctly differ-

ent. There were also amphoric breathing and vocal resonance over the antero-lateral part of the left chest, below fourth rib; distinct and very constant metallic tinkling, and marked succussion-splash. These signs evidently suggested pneumothorax, and the sign which chiefly opposed the idea of its presence was the existence of numerous bubbling râles heard apparently superficially over the entire antero-lateral region of left chest.

The diagnosis of pneumothorax circumscribed below the level of the fourth interspace was determined upon. The patient rapidly sank, and died.

At the *autopsy*, the chest and abdomen were opened, and the organs examined *in situ*. The left lung was solidified throughout from cheesy infiltration, with four abscesses of considerable size,—two in the lower part of the upper lobe, and two in the lower lobe. There was no pneumothorax; but the pleuræ were in contact throughout, and were, in parts, coated with fresh lymph. The right lung was comparatively healthy, containing but a few scattered nodules of cheesy deposit.

The stomach was enormously distended with gas, and pressed very forcibly up into the concavity of the diaphragm.

It was evident, therefore, that the phenomena above described, which so closely simulated pneumothorax, and which occurred in a case when pneumothorax might have been expected, were dependent upon an enormous stomach, in connection with a consolidated lung, the seat of several abscesses of considerable size. *March* 12*th*, 1874.

---

10. *Cancer of the pylorus.*

By Dr. F. P. Henry.

The patient from whom this specimen of cancer of the pylorus was removed was an unmarried female, æt. 55, who had been under my care at different times for about four years. I first attended her in 1870, for rheumatism, from which she had suffered for more than twenty years. When I began to attend her she had been confined to her room for several years, being almost completely crippled by chronic rheumatism. All the joints had been affected, and the fingers were distorted so as to render them of little use. My efforts in the way of treatment were chiefly limited to relieving the acute exacerbations from which she frequently suffered, but, with the hope of achieving some more permanent success, and at the

same time to remove the constipation, which was an important element in the case, I put her upon the use of Rochelle salts in drachm doses three times a day. Under this treatment she steadily improved, and in the summer of 1870 she descended the stairs for the first time in ten years. Whether this success was owing to the treatment or to the unusually warm weather of that year is of course an open question. This amelioration of the rheumatism was permanent. She remained free from any serious illness until I was called to attend her about the first of February of the present year. The symptoms at that time were obstinate vomiting and constipation; but as she had been for a long time subject to transient attacks of acute indigestion, readily amenable to treatment, I at first anticipated nothing serious. The usual remedies not benefiting her, I began to suspect some organic trouble, and on palpating the abdomen I discovered a tumor about three inches to the right of and a little below the umbilicus, at about the junction of the umbilical and right lumbar regions. This tumor I proved to be disconnected from the liver by finding that there was tympanitic resonance on percussion between it and that viscus. It was hard, immovable, and somewhat tender. On pressure, pulsation was communicated to it from the abdominal aorta.

As it was lower than we generally expect to find a tumor of the pylorus, the idea of a fecal tumor presented itself. The condition of the patient at that time was good: the pulse strong, and about 80. A pill containing two grains of aloes was administered three times a day, and on the third day operated freely three times, the discharges being fecal. The tumor was then examined and no diminution in its size observed.

Numerous remedies were employed to relieve the vomiting and nausea, among them the oxalate of cerium and the wine of ipecac in small doses, —the latter on the strength of Dr. Ringer's recommendation, in his work on Therapeutics. Neither of them was of the slightest service.

The patient was seen by Dr. Howell, of Woodbury, N. J., in consultation, who, with Dr. Nancrede, was present at the *autopsy*. The stomach was found distended with fluid ingesta, and much below its normal position, the greater curvature descending more than an inch below the umbilicus. The pylorus was closed by a scirrhous thickening of its walls, but the resiliency of the tumor was so great that by using force the little finger could be forced through the duodenum. The thickening did not extend to the duodenum. The gall-bladder was distended with bile, and a large calculus could be felt through its walls. The microscopic examination made by Dr. Nancrede showed the characteristic fibrous alveoli of cancer crowded with large round cells. The specimen derives a further interest from the

fact that it has been preserved nine days in a solution of hydrate of chloral, gr. xv ad ℥i.

The President said that a point of unusual interest in connection with this case was the occurrence of carcinoma in a patient who had had rheumatoid arthritis. He did not remember ever to have met with the combination of carcinoma with this disease. He thought also that some writers on the subject of rheumatoid arthritis mentioned its tendency to exclude carcinoma. *April 9th*, 1874.

---

11. *Typhoid fever—anomalous course of temperature—marked symptoms of spinal irritation—death on ninth day (?)—characteristic lesions.*

By Dr. Wm. Pepper.

John K., æt. 38, German. On admission, 4th of April, 1874, complained of dyspeptic symptoms, with constipation. He seems to have improved under treatment, and was only seen in the wards at meal- and bed-times. On the 8th he was noticed by the night-nurse to have a staggering gait; he was stupid, and temperature 101¾°. Next morning temp. was 104¾°; pulse 102. Hardly any history could be obtained from him; he had been living about Front and Race Streets.

Much stupidity, and at times a condition of coma-vigil. Marked tremor, and great rigidity of all the muscles. No eruption, no sordes; constipation; slight meteorism; no tenderness; apparently nowhere any pain. Urine high-colored, not albuminous, with slight diminution of urea; had to be drawn with catheter. No cough or sputa. Physical examination: resonance rather exaggerated anteriorly; dulness over the two bases posteriorly; marked absence of respiratory murmur throughout the lung. A double pericardial friction-sound heard at the base of heart. 9th, evening temp. 104°; pulse 120. 10th, morning temp. 103½°; pulse 125; resp. 30; evening temp. 103°; pulse 144; resp. 30. At 11.45 P.M. he was found unconscious, rigid, motionless; temp. 106¾°; pulse 145; resp. 45. He was packed in cold sheets wet with cold water for two hours, when temp. fell to 101½°. During the day and night of the 11th the temperature showed a constant tendency to rise, so that only by repeated packing could it be kept between 100° and 103°. At 10 P.M. it reached 105°, but was soon brought down to 100¾°; finally, at 6 A.M. of the 12th, he died, with a temperature of 105°. His other treatment has consisted of quiniæ sulph., gr. xxiv daily, concentrated nourishment, eight ounces of whisky daily, and the use of febrifuge draughts.

Post-mortem, ten hours after death.

Thorax.—The lungs were congested, especially in their postero-inferior portions, where they presented a condition approaching splenification. The pericardial sac was not distended. On opening pericardial sac, about two ounces of clear serum were found. There was a patch of lymph on the anterior surface of aorta, one and one-fourth inches above the origin. This lymph did not seem recent, as it was tough, and there appeared to be new-formed vessels. There were several milk-spots over surface of the heart.

Heart.—The cavity of the left ventricle almost obliterated by firm contraction of walls, without contents. The right ventricle contained a little dark fluid blood. No lesion of the valves. The lining membrane not stained.

Abdomen.—There was marked retention of warmth. The liver was of moderate size; its tissue pale, somewhat congested. The spleen double the natural size; tissue much softened; no abnormal deposit. The mesenteric glands greatly enlarged, pinkish, and dry. The intestines greatly distended with gas, and containing fluid fecal matter. The lower three feet of the ileum were opened; there was marked injection of the mucous membrane. The solitary follicles were greatly enlarged, and Peyer's patches, especially towards the valve, were also enlarged, with prominent raised borders and enlargement of the orifices of the follicles. The patches were of a pale grayish color (medullary infiltration).

Head.—Vessels of the dura mater were slightly injected. The arachnoid over the convexity near the sinuses and along some of the larger veins was milky and thickened; chronic inflammation. No abnormal effusion.

Kidneys.—Cortex pale and probably fatty. About one pint of urine was found in the bladder.

Microscopic examination.—The uriniferous tubules were filled throughout the kidney with fatty cells, decidedly granular, and, rarely, some free oil-drops. There was also some degeneration of the liver. The heart-muscle was fatty; the fasciculi being granular throughout, though the striation was yet perfectly distinct. There was no degeneration of the voluntary muscles. Portions were examined from the pectoral and rectus muscles. *April* 23*d*, 1874.

12. *Viscera from a case of amputation of the breast; death four weeks after operation, and wound almost healed.*

By Dr. Jno. H. Packard.

The death was preceded by about half an hour of increasing dyspnœa, she having been previously in perfect health in this respect.

Heart fatty; valves normal; aorta entirely free from atheromatous deposits. The heart was full of liquid blood, as were also the aorta, vena cava, and blood-vessel system generally.

The *pulmonary arteries* were full of firm clot; that in the right branch being firmer, and occluding the vessel more completely, than that in the left. On the right side the clot was traced through several successive ramifications of the vessel into the middle lobe of the lung. On the left side it was less extensive, and tended towards the lower lobe of the lung.

Lungs everywhere crepitant; perhaps somewhat emphysematous in the lower lobes. Old cicatrices existed in both apices, and in the left lung there was a very small hardened cheesy deposit.

The *bronchial glands* were much enlarged, and full of carbonaceous matter.

Liver in a very early stage of cirrhosis. *Gall-bladder* much thickened, and lobulated (or contorted?); quite white.

Pancreas irregularly thickened,—in some places hardened, and in others so soft as to tear readily.

Spleen quite diffluent; a thick sheet of white lymph over its anterior surface.

Left kidney and *supra-renal capsule* normal; right not examined.

The seat of the operation-wound was found almost entirely healed, and the neighboring tissues perfectly sound, and free from appearance of disease.

The explanation of the fatal result in this case seemed to be that, from some trifling exertion, the weak and fatty heart "slowed" its movements, when coagulation began to take place, especially, or perhaps only, in the pulmonary artery, where the current was less forcible than in the aorta. The slight obstruction thus produced would still further embarrass the feeble right ventricle, and this circumstance would favor the closer blocking of the vessels. Hence, violent respiratory efforts would ensue, the blood not having access to the aerating organs, and death was the result of mechanical asphyxia.

I desire to call attention to the fact that in this patient, the subject of

cancer, there were evidences of the former occurrence of phthisis in the cicatrices at the top of each lung. *April 9th*, 1874.

Report of the Committee on Morbid Growths:

"Your committee found in Dr. Packard's specimen a large-sized gall-stone impacted in the ductus choledochus, where it had caused the lining membrane to ulcerate. The portion of the tube lying in front of the foreign body was pervious, although its mucous membrane was very much swollen and congested. The gall-bladder itself was contracted, and contained a small quantity of thick, dark, grumous bile; its walls were covered with a layer of fat half an inch in thickness. The head of the pancreas was found very much indurated, and somewhat increased in size. This was found upon examination to be due to an excessive development of connective tissue between the normal secreting parenchyma."

May 7th, 1874.

---

13. *Cancer of the gall-bladder.*

By Dr. James Tyson.

P. G., æt. 63, was admitted to the Philadelphia Hospital March 5th, 1874; born in Ireland; was formerly intemperate. No history of cancer in the family. Had been a very healthy man. Ten years ago an epithelioma appeared on his lip; it gradually increased in size, and had been operated upon three times,—the last time, a year ago, in this house, by Dr. Pancoast. From the time of his admission he presented a uniformly pale, anæmic appearance. There was constantly aggravated dyspepsia, relieved only by milk diet; also occasional attacks of vomiting, which would last for over twenty-four hours, accompanied by quite severe colic. His bowels were very costive, and a diarrhœa was very apt to set in when the bowels were opened by remedies. The normal tympany seemed to prevail throughout the abdomen. Since admission, he had been taking a mixture containing tinct. ferri chlor., nitro-muriatic acid, and extract of taraxacum.

April 15th.—Has been steadily improving as to his symptoms, though he still has the same anæmic, cachectic appearance. Discharged him to out-ward department.

April 28th.—Has re-entered the wards, having had another attack of vomiting, with aggravated dyspeptic symptoms.

Ordered him milk diet, and a mixture containing tinct. ferri chlorid., tinct. gentian. comp., and infusion of columbo.

May 4th.—There has been no vomiting for the last three or four days, but he is rapidly emaciating. Pulse 84, of fair volume. Tympanitic percussion continues throughout his abdomen, except over a small area midway between ensiform cartilage and umbilicus, and rather a little to the right of the median line. Palpation discovers an uncertain hardening above the umbilicus.

May 5th.—Died this morning.

Post-mortem examination, five hours after death.—Body exceedingly emaciated, the skin being drawn tense over the bones; skin of a dark sallow color. On opening the abdominal cavity, the mesenteric glands were found very much enlarged. Pancreas healthy, as also the stomach's cardiac and pyloric extremities. Stomach was greatly distended by gas, and its upper surface, especially to the right, was firmly adherent to the under surface of the liver. There was no gall-bladder found, but its place was occupied by a large cavity, which was bounded by the posterior surface of the stomach and under surface of the liver, this organ being destroyed to a considerable extent. The cavity contained some fluid, and small cheesy lumps. The wall between it and the stomach was very thin. The intestines were healthy. The specimen was supposed to be one of cancerous disease of the gall-bladder. *May* 14*th*, 1874.

---

14. *Ulceration of Peyer's glands.*

By Dr. J. Ewing Mears.

This small portion of the lower end of the ileum was removed from a child aged 2 years and 3 months, the cause of whose death was typhoid fever. The apparent absence of prodromic symptoms, and the rapidly fatal termination which took place, seem to make the case one of more than ordinary interest.

The case occurred in a family in which the mother had been under treatment for some time for a chronic disease. Attention was first directed to the child on the morning of the 13th inst., and treatment was asked for a condition of purulent ophthalmia of the left eye, which had suddenly developed itself. The associated symptoms of slight heat of skin, increased temperature, and coating of the tongue, were attributed to the local condition, and therefore did not attract particular attention. The statement furnished by the parents was that the child had been in apparent good health until this date,—had engaged in play with his playmates, and shown

no signs of impending ill health. There was no diarrhœa, so far as could be ascertained, and tympanites was not present. The child manifested some irritability on being disturbed, obeyed, however, when spoken to, and was perfectly rational. Local treatment was directed to the eye, and a mild purgative ordered; also a febrifuge mixture; milk and beef-essence for a diet.

In the evening the condition of the patient did not appear to be much changed, except that he complained of cephalalgia. The purgative had acted, without producing hypercatharsis. The temperature and circulation were not increased.

At the next visit, on the morning of the 14th, a marked change was observed to have taken place in the condition of the patient. The pulse was 130, the temperature was notably increased, the tongue was dry, and, except the edges, covered with a brownish coating. Delirium was present, though not very active in character. An involuntary evacuation of fæces had occurred, which was of a yellowish color. There was tympanitic distention of the abdomen. The conjunctival inflammation had somewhat subsided. The symptoms continued to increase in severity until evening, when coma and convulsions occurred, in which the child died, shortly after midnight.

Sixteen hours after, an *autopsy* was made by Dr. W. H. Parish, and the following conditions noted: The dependent portions of the body were markedly discolored from hypostatic congestion. Brownish spots of varying sizes and shapes covered the trunk and extremities.

The vessels of the meninges of the brain were engorged, and sections of the cerebrum and medulla oblongata showed great congestion of the contained blood-vessels. The ventricles were empty. The medulla and upper part of the cord were firm; no evidence of softening. The lungs were normal, the heart firm and contracted. The mucous membrane of the stomach was covered by blackish deposit, which was readily removed, showing the surface normal. The liver was not affected. The gall-bladder was much distended. The adjacent intestines were much stained by contact with the gall-bladder. The spleen was enlarged and congested. The mucous membrane of the small intestine exhibited a very marked reddening, which attracted attention at the duodenum, by the contrast with the inner coat of the stomach. The solitary glands throughout were enlarged, and Peyer's patches showed beginning ulceration. The mesenteric glands were in great numbers enlarged, varying in size from that of a pea to that of an almond. The kidneys and bladder were not examined.

In connection with this case, it is interesting to mention that on the day

of the death of this child another member of the family, a girl aged 5, was attacked with typhoid pneumonia, which terminated favorably.

May 28*th*, 1874.

---

15. *Dysenteric inflammation, with cystic kidneys.*

By Dr. F. P. Henry.

P. D., seaman, æt. 62, was admitted to the Episcopal Hospital on the 2d of May. He had been on a voyage to the French islands on the east coast of Africa, and during the passage home he had suffered from diarrhœa, with colicky pains in the stomach and bowels, and occasionally passed blood by the rectum. On the voyage home, five of his shipmates and the mate died, after complaining of the same symptoms.

The patient grew steadily worse, remedies having no control over the dysentery, and he died on May 12th, ten days after admission. Three days before death he passed a quantity of blood, estimated at a quart *by the nurse*, per rectum. The *post-mortem* revealed a healthy state of all the abdominal viscera except the large intestine and kidneys. There are no ulcers visible upon the mucous membrane of the colon and rectum, which is swollen and greatly congested. The kidneys present numerous cysts of large size.

During life the urine was not examined, no symptoms pointing towards disease of the kidneys. The patient was conscious up to within two hours of his death.

May 28*th*, 1874.

---

16. *Gastric ulcer.*

By Dr. F. P. Henry.

A. H., æt. 19, admitted to the Episcopal Hospital April 18th; had been sick for about three months before admission. It was impossible to get from her anything like a clear history of her case. On entry, she was much emaciated and jaundiced. There was intense pain on pressure over the epigastrium, and great pain over the same region after eating. When I took charge of the case on May 1st, the girl was evidently sinking, and suffered such intense pain that the treatment from that time consisted almost solely in the use of hypodermic injections of morphia. She died on the 13th of May.

At the *post-mortem* examination a small circular ulcer was found near the cardiac orifice of the stomach. The lungs, heart, and kidneys were healthy. The liver weighed five pounds, was indurated and coarsely granular on section. It appeared to be in the first stage of cirrhosis.

The immediate cause of death seemed to be heart-clot. Firm, yellowish-white clots were found in both ventricles. There was no appearance of pulmonary emphysema, as was observed by Dr. Packard in a case of sudden death from heart-clot recently reported by him to the Society, but the lungs presented an anæmic appearance, as though the supply of blood had been gradually diminished.

An interesting feature of the case is the occurrence of cirrhosis of the liver with gastric ulcer. Rindfleisch attributes the cause of gastric ulcer to the occurrence of "small hemorrhages from the superficial venous trunks of the gastric mucous membrane," caused by "the temporary stagnation of the blood's afflux" in the act of vomiting. "The hemorrhagic infarction becomes a caput mortuum, its organic connection with the healthy mucous membrane is destroyed, and the actual separation only a question of time." This separation is greatly facilitated by the action of the gastric juice, which immediately attacks the dead mucous membrane.

In cirrhosis of the liver there is a constant obstruction to the return of venous blood from the stomach through pressure upon the portal vein, rendering hemorrhage extremely liable to occur during the act of vomiting or even independently of it. I am not aware that any frequent connection has been noticed between the two diseases, but, if so, it would seem to add additional weight to Rindfleisch's theory of the pathology of gastric ulcer.

May 28th, 1874.

---

17. *Two specimens of intestines from cases of typhoid fever.*

By Dr. Wm. Pepper.

One of the specimens shows the lower portion of the ileum, with marked enlargement of the glands of Peyer and of the solitary follicles. In a few spots superficial ulceration has appeared. The walls of the bowel are somewhat thickened and too vascular; and there were evidences of general peritonitis, with production of pus and yellowish lymph. The spleen was enlarged; the mesenteric glands enlarged and slightly softened.

The specimens came from a child of 4 years, who died on the eighth day, of a violent attack of typhoid fever. The early symptoms were ob-

scure and undecided, consisting only of irregular feverishness and failure of strength and appetite. Convulsions occurred on the fifth and sixth days, and the little patient remained subsequently in a state of stupor. The abdomen was much distended, and was evidently the seat of pain. There was no diarrhœa; but when stools were procured by laxatives, they were thin and yellowish.

No cause for the severe peritonitis could be found, as ulceration of the glands of Peyer had in no instance extended deeply enough to cause inflammation of the serous membrane; and there certainly had been no perforation. It is probable, therefore, that it was due to the septic poison of the disease, as is seen in pyæmia, erysipelas, etc. No special source of infection could be discovered at the place where the disease had originated.

September 24*th*, 1874.

The second specimen exhibited extreme disease of the solitary glands and patches of Peyer in the ileum, removed from a man 28 years of age, who died in the University Hospital on the twenty-third day of an attack of typhoid fever. He had received no medical treatment until his admission on the twentieth day of the disease, and for four days before that time had been almost without food or attendance. His prostration was extreme; nervous symptoms mild; slight eruption only; considerable bronchial congestion; abdomen distended and tender, and incessant colliquative diarrhœa. The stools ran away from him almost continuously, and were composed of thin, yellowish liquid. All treatment proved unavailing to check this, and death occurred from exhaustion.

At the *autopsy*, marked pulmonary congestion and decided enlargement of the spleen were found. The mesenteric glands very much enlarged, reddish, and softened. The small intestine was distended, and its walls were vascular. The intestinal glands were implicated throughout the entire course of the bowel, but the lesions were most profound through the ileum, especially towards its lower end. The solitary glands were greatly enlarged, containing semi-fluid exudation, and in some instances had undergone superficial ulceration. The disease of the patches of Peyer towards the lower end of the ileum was extraordinarily intense. The intestine presented for a distance of more than a foot, a mass of large, oval ulcers, almost confluent, with thick, rounded edges and irregular fungous surfaces.

September 24*th*, 1874.

18. *Congenital imperforation of the duodenum and absence of the gall-bladder.*

By Dr. Richard A. Cleemann.

These specimens of morbid anatomy represent arrest of development of the duodenum and of the gall-bladder. They were removed, with the assistance of Dr. C. B. Nancrede, at the necropsy of a female infant, made thirty hours after death. The body was emaciated; the cadaveric rigidity well marked. On opening the abdomen, the stomach and what proved to be a portion of the duodenum greatly distended were seen, of a pearly whitish appearance, extending quite across from side to side and deep down in that cavity. The contents of this double pouch, to which the stomach contributed about two-thirds, consisted, besides gases, of a thick, blackish-green liquid, resembling meconium: after these were removed the capacity of the whole sac for water was seven and a half fluidounces. Examining

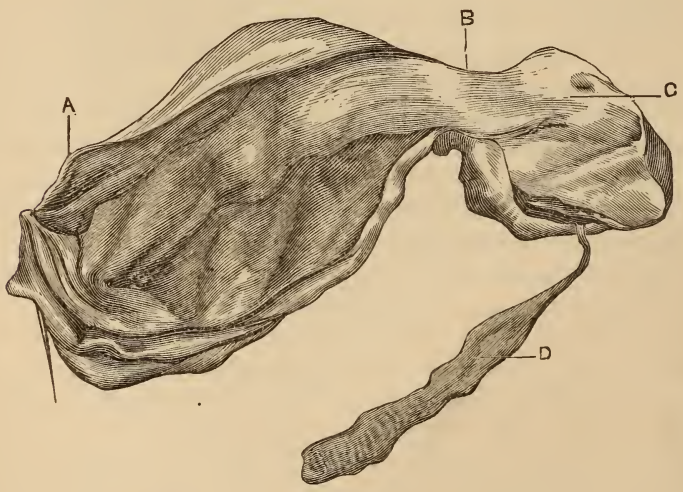

Fig. 2.

A. Stomach.
B. Pylorus.
C. Portion of duodenum above imperforation enormously dilated.
D. Small intestine.

the interior of the duodenal portion, a papilla with a central depression is seen, situated posteriorly and near the lower end, but no outlet. A thin strip of tissue has been left, uniting the external face of this little eminence with

a narrow blind pouch, which was continuous with the jejunum. The latter and the rest of the intestinal canal were contracted, and presented nothing abnormal. The anus, vagina, and urethra were pervious and well formed; the bladder empty. On inspecting the liver, the depression between the right and square lobes is found to be without the gall-bladder, a thin cord of tissue, somewhat expanded anteriorly, occupying this position. Nothing further of special interest was observed in the contents of the abdominal and pelvic cavities; those of the thorax and cranium were not examined.

The subject of these imperfections seemed, at birth, to be in perfectly good condition, and had in due time alvine and urinary evacuations. However, in the course of the first day, after something fed her by the nurse, vomiting began, and persisted till the fifth day, when death occurred from exhaustion. The matters vomited at first looked like what had been ingested, but subsequent ejections had a peculiar yellow color, and were at the close quite dark, resembling the *post-mortem* contents of the stomach, and had a very disagreeable odor. Along with the gastric disturbance, restlessness soon began, and then evidences of pain manifested themselves, which increased till the little patient seemed in an agony of suffering. She ceased to micturate after the second day, but had motions from the bowels to the end.

The hour-glass-shaped pouch formed by the stomach and part of the duodenum, the much dilated pylorus like a firm ring, making but a loose constriction, had a very deceptive appearance; especially before the immersion of the specimen in alcohol, in which it has contracted unequally. It looked as if the stomach had reverted to the sacculated condition which occurs in some lower animals, and which, indeed, has sometimes been found in infants. In two instances of congenital stricture of the duodenum, reported in the Transactions of the Pathological Society of London (the only cases there described at all similar to this), the shape of the conjoined stomach and part of the duodenum was precisely the same. In the first of these, furnished by Dr. Wilks, the infant died on the second day, fourteen hours after vomiting began, and there were no evacuations from the rectum, the bowels being found distended with meconium at the necropsy. The stricture occurred just above the entrance of the common duct.* In the other case, contributed by Dr. George Buchanan, the child lived eighteen months, presenting a curious succession of symptoms; the difficulty was caused by a slightly oblique septum, with a perforation through the centre only a line in diameter; between the walls of this diaphragm ran the bile-duct.†

---

* Trans. Path. Soc. of London, vol. xii. p. 101. † Ibid., p. 121.

Congenital imperforation in the course of the intestinal canal is much more rare than at its extremities; a fact easily explained by the greater simplicity of development of the walls of the tube than of its outlets. On account of this rarity, little is to be found written on the subject in systematic medical works; but the younger St. Hilaire treats generally concerning it as follows: "It (the alimentary canal) is sometimes imperfect in one or several regions, principally in its terminal portions, but never throughout its whole length. The imperforation results at one time from a membrane placed transversely, at another from the approach and intimate union of the intestinal walls so that the form of the organ changes from that of a canal to that of a solid cord, and again, finally, from the termination of the intestine in a *cul-de-sac*."* Occurring in the duodenum, as in this case, the condition is of course necessarily fatal.

Absence of the gall-bladder, on the other hand, is not very uncommon, and, a compensatory dilatation developing itself in the course of the hepatic duct or in the substance of the liver itself,† its non-existence is quite compatible with prolonged life. The conjunction of the two anomalies is, however, very interesting in view of the functional and local relations of the defective organs, to explain which it may be supposed either—following Sir James Paget in the theory which makes one organ in its development serve the purpose of an excretion in the production of another‡—that the imperforate duodenum determined the absence of the gall-bladder, or that the close juxtaposition of certain portions of the two organs exposed them to the direct action of some local disturbing cause. To know what was the condition of the hepatic duct would be useful in this connection, but, unfortunately, the specimen was removed too hurriedly to admit of its dissection.

As at the necropsy no local condition, such as an adventitious band, was discovered to account for the anomalies, so, with the same negative result, nothing was elicited in the history of the mother's pregnancy to warrant their reference to inheritance, mechanical disturbance, or profound mental impression—the three principal supposed agents in the arrest of development. *September 24th*, 1874.

---

* Histoire des Anom. de l'Organisation. Bruxelles, 1837, tome i. p. 376.

† Sharpey & Quain's Human Anatomy, by Leidy, first Amer. edit., vol. ii. p. 401.

‡ Lectures on Surgical Pathology, third London edit., p. 19.

19. *Sarcoma involving the parotid gland and masseter muscle.*

By Dr. J. Ewing Mears.

The specimen was removed from a male patient, aged 58, at St. Mary's Hospital. *September* 10*th*, 1874.

Report of the Committee on Morbid Growths:

"The large tumor removed from the parotid region on September 10th, by Dr. Mears, is made up of large round and spindle-cell elements; the sparse interstitial substance is finely fibrillated.

"Some of the sections reveal the presence of a glandular tissue and ducts lined with cylindrical epithelium, thus leaving little doubt of the involvement of the parotid gland. There is apparently no excessive development of the epithelial lining, no budding out of epithelial processes; but, on the other hand, the glandular cells are widely separated and compressed by the abundant development of the sarcomatous cells in the connective tissue.

"The sarcoma has likewise invaded the masseter muscle, and here it also seems to spread along the connective tissue mainly, though in a few of the muscular fibres beneath the sarcolemma were seen extending the large nucleated bodies, as if the sarcous elements were undergoing a similar transformation.

"Further study of these sections will, however, be requisite before your committee can pronounce with any degree of certainty on this point. Many of the muscular fibres are irregular in outline, swollen and contorted; their striations are obliterated, a so-called 'amyloid degeneration' having taken place. This condition has often been noted in muscular fibres that are being encroached upon by new growths." *September* 24*th*, 1874.

---

20. *Two cases of intestinal perforation, the sequelæ of typhoid fever.*

By Dr. F. P. Henry.

Both of the subjects furnishing these specimens were walking cases of typhoid fever. The first case, from which the specimen in alcohol was obtained, was admitted to the Episcopal Hospital on the 9th of May, and died on the 5th of June. For the first four days after admission he re-

mained in bed, but during the greater part of his stay of nearly a month in the hospital he was up the most of each day. He was easily fatigued, however, and subject to headache and dizziness. This latter symptom, dizziness, was his chief complaint, and taken in connection with his slow pulse, anorexia, and frequent headache, was calculated to draw attention to the brain as the seat of disease. This dizziness was so great as to cause him to adopt a peculiar gait to steady himself. I noticed him one day walking with his legs very wide apart, and on questioning him found that it was to prevent himself from falling. His temperature was found so near normal that no record of it was preserved until June 1st, when I observed it recorded as 101°; this being the evening temperature.

On June 2d, the morning temperature was 99°, and the evening, 101½°.

On June 3d, morning, 98¾°; evening, 100.°

June 4th.—Morning, 99½°; evening, 104½°. It was at this time that symptoms of peritonitis showed themselves. There was enormous tympanitic distention and great tenderness of the abdomen, with a pulse of 140. The temperature was taken again during the night, and found to be 105½°.

The man died before morning, in a state of collapse, the result of shock. At the *post-mortem*, a few hours after death, there was found a small quantity of watery fæces in the abdomen, and a few patches of opacity, with increased vascularity, upon the peritoneum covering the small intestines. The ileum was thickly covered with ulcerated Peyer's patches, and after careful search a small perforation was discovered at the bottom of one of these ulcerations, a few inches above the ileo-cæcal valve.

This patient was kept upon liquid diet, as a strong suspicion of typhoid fever existed, and the ulceration cannot, therefore, be considered due to a traumatic cause.

The second case was admitted to the Episcopal Hospital on the 12th of October, 1874. He had been ill for five weeks previous, but had not been confined to bed. His symptoms were headache and fever, always worse towards evening; pain in the right iliac region, and diarrhœa, amounting to from fifteen to twenty stools in the twenty-four hours. Six days before admission to the hospital, he was suddenly seized with nausea and vomiting, the diarrhœa continuing, with pain accompanying each passage.

On admission, there was excessive tenderness over the whole abdomen, great rigidity of the abdominal muscles, particularly the recti, and vomiting at frequent intervals of a small quantity of pale-green fluid, apparently mucus, tinged with bile.

I first saw the patient on the 13th, the morning after his admission, and

found the above-mentioned symptoms. The decubitus was dorsal, with the thighs and legs flexed. The pupils were moderately contracted; respirations 18 per minute and very shallow; pulse 160, weak and thready; skin cool and moist.

The treatment followed by Dr. Steele, the resident physician, had consisted of a grain of opium, in pill, every three hours, with a hypodermic injection of one-quarter of a grain of morphia every six hours, with nutritious enemata.

I administered one-quarter of a grain of morphia hypodermically, and on leaving the hospital found the respirations 16 per minute, and the pulse still 160.

At 1 P.M. there was no pulse at the wrist, the respirations were 14 per minute, and the pupils decidedly contracted. Died at 9 P.M.

The opium administered did not produce sleep or stupor, but served to mitigate the severity of the pain.

At the *autopsy*, eleven hours after death, the intestines were found matted together in one mass by, and bathed in, about two quarts of very offensive pus. Mesenteric glands enlarged but not softened. Several ulcerated Peyer's patches were observed, but the ulceration was by no means so extensive as in the preceding case. At the bottom of one of these patches were found two rather large perforations, and a third at the bottom of a second ulcer. In these ulcerations the whole of the glandular structure has sloughed away, leaving a clean-cut ulcer, showing a late stage of the disease. The intestines are covered with a thick layer of lymph.

The notes and observations in connection with these cases were by Drs. Steele and Reid. *October 22d*, 1874.

---

21. *Perforation of vermiform process by ulceration, and resulting acute diffuse peritonitis.*

By Dr. W. H. Warder, for Dr. Edward Stone.

The specimen was from W. B., æt. 24 years, married, temperate, and who had always enjoyed good health previous to his last illness. Dr. S. was called to see him on the evening of October 24th. He said that he had had "cramps" all day, for which the ordinary domestic remedies were taken,—ginger, brandy, etc.,—but without much relief. His bowels had been moved twice that day, and he had had nausea and some vomiting during the afternoon. He was suffering at the time of the visit from

severe pain in the umbilical region, which came on in paroxysms every few minutes, and was not relieved by pressure, although the belly was not sensitive to pressure. Tongue slightly coated; pulse 80, rather small and weak.

October 25th, morning.—Considerable vomiting during the night. Pain has been relieved, but considerable tenderness has been developed generally over the abdomen, not sufficient, however, to prevent him from leaving his bed to go down-stairs. The soreness is most marked between epigastrium and umbilicus. No tympanites whatever. Has no pain, excepting when turning in bed, and the position of lower extremities has no influence on it. Tongue heavily coated in the centre. Respirations hurried and somewhat superficial; pulse 98, small and weak, and considerable heat of skin.

October 25th, evening.—Vomiting has ceased. Although "he feels better," and is comfortable while lying still, he is much weaker. Pulse running 120, and very small and compressible, with marked heat of skin. Respiration entirely thoracic. No tympany, the belly looking natural as before. Lying on his back, with limbs extended. Bowels have not been opened since yesterday. Retention of urine; catheter was passed, and about a half-pint of urine withdrawn, normal in appearance.

During the night he sank rapidly, and died at 7 A.M., October 26th.

(After his death, Dr. Stone learned that he had been ailing and had had "pain in his stomach" for several days before he saw him.)

Autopsy, twenty-six hours after death.—Abdomen only examined. Rigor mortis well marked. Abdomen flat. Signs of violent acute peritonitis, involving the whole sac. Omentum swollen and injected, and glued down by recent adhesions to surrounding viscera. Intestines congested and matted together, covered here and there with patches of soft yellow lymph. In right iliac fossa, the caput coli and lower portion of ileum were more firmly adherent, and were thickly covered with lymph. The vermiform appendix was firmly adherent to an adjacent coil of intestine by its extremity, and was about the diameter of the index-finger, patulous, and full of semi-fluid fæces. Near its base a small ulcer was found to have perforated the bowel. The mucous membrane of the intestinal canal elsewhere was not ulcerated. No foreign substance was found, and the fæces in the colon were healthy. Peritoneal cavity contained about one-half pint of sero-purulent fluid. *November* 14*th*, 1874.

The President said these cases were of interest and importance, in consequence of their being much more frequent than is usually acknowledged,

on account of their fatality and the obscurity of their diagnostic symptoms. In this unfortunate case one would suppose from the size of the appendix that there had been latent disease of a chronic inflammatory character, so that the true period of beginning of the typhlitis was not observed, while the disease was rapidly going on to perforation. Indeed, typical symptoms can scarcely be said to have manifested themselves. The case was also of interest from the fact that there appeared to be no foreign body or hardened secretion of mucus occupying the appendix, as is usually the case, though, from the fact that there was still free communication between the appendix and the cæcum, such a body may have existed and have escaped into the large intestine.

In answer to a question by Dr. Harrison Allen, the President further said that in his own observation the position of the ulcer had seemed to be a matter of indifference. He had seen it occupy the extremity of the appendix, and all intermediate points between this and the cæcum. He had seen from two to four ulcers with two perforations. The ulcers often arise in connection with some distinct irritating particle which is at times attached at the site of the perforation, and seems to have been the determining cause of the ulcer at that point. In cases where the opening between the appendix and the bowel is closed by adhesions, the cavity of the appendix is apt to be greatly distended by the accumulation of pus. In cases where the communication with the cæcum is retained, the irritating foreign body may escape from its position into the large intestine, and thus be overlooked. But it would seem that usually the seat of the ulcer was quite accidental, perhaps depending in many cases on the position where the foreign body lay in contact with the mucous membrane. In cases of typhlitis which result from other causes than the presence of irritating foreign bodies, whether of inspissated mucus or fæces, or bodies more strictly foreign, such as fruit-seeds, the appendix itself is not so apt to be the seat of the disease as the walls of the cæcum, and the attack is apt to assume rather a different form. *November* 14*th*, 1874.

---

22. *Cystic disease of the submaxillary gland.*

By Dr. Jno. Ashhurst, Jr.

The specimen consists of a much hypertrophied submaxillary gland, exhibiting at its posterior part a large cyst which contained a whitish mucoid

substance. The gland had been removed by excision twelve days previously, from a lad thirteen years old, who had been suffering from the affection between four and five months. Excision rather than simple incision was employed, as being a more rapid as well as more radical method of treatment, and one the better results of which justified the slightly greater risk by which it was attended. The operation had presented no particular difficulty, the facial artery being the only large vessel which required division, and the patient is since convalescent. *December* 10*th*, 1874.

---

23. *Cancer of the cæcum, and intussusception into large intestine—intramural fibroid tumor of the uterus—cystic ovaries.*

By Dr. Wharton Sinkler, for Drs. J. J. Black and Stewart, of Newcastle, Delaware.

The specimens are from a lady who was in her 63d year, and previous to September, 1873, was remarkable for her good digestive powers. After that time she was subject to flatulence, with severe attacks of pain in the abdomen, which increased in frequency as her strength failed. For three months before the close of life, vomiting was a prominent symptom, being induced by every attempt to take nourishment, and for the last ten days she was kept alive by the repeated exhibition of brandy, a large portion of which was rejected.

She died October 18th, 1874.

The *post-mortem* examination was made the following day by Dr. Black, in presence of Drs. Porter and Bush, of Wilmington, and Dr. Stewart, of Newcastle.

The specimen of bowel includes the large intestine from the commencement of the colon. Dr. Black wrote that the first part of the transverse colon appeared to have "swallowed" the caput coli, the appendix vermiformis and the commencement of the ileum being also carried in, while the cæcum appeared to be a mass of cancer. On opening the first part of the transverse colon, this mass seemed to lie within it, mucous surface to mucous surface, and peritoneal to peritoneal.

The *mesentery* and *omentum* were full of shot-like bodies, and the *duodenum* up to the pylorus was very much thickened, and contained the same deposit almost blocking it.

The *kidneys* were slightly granular; the *liver* of natural size,—smooth, but hardened in texture, of light-brown color, and somewhat fatty. The

uterus contained the intra-mural uterine fibroid forwarded, which was the seat of a calcareous degeneration. The *right ovary* contained a cyst as large as an orange, filled with fluid; the left, a similar smaller cyst.

December 10*th*, 1874.

---

24. *Hepatic abscess, opening externally in right side—death from exhaustion.*

By Dr. William Pepper.

W. S., æt. 30, was admitted to the Philadelphia Hospital October 11th, 1874. He was of intemperate habits, but had never had venereal disease nor dysentery. Had never lived in any tropical climate. Several years before, while in the army, he was wounded in the left side by a charge of duck-shot, part of which remained, but gave rise to no subsequent trouble. He first began to complain in March, 1874, of severe pain in the right side. This was at first paroxysmal, but soon became dull and continuous, and was attended for six weeks with hectic fever. This diminished, and soon there was noticed bulging of lower part of antero-lateral aspect of right thorax. The swelling extended around base of chest on right side, but was most prominent about seventh and eighth ribs in line of anterior border of axilla. Here it was, when it first appeared in June, very hard, but by August it had become softened, with indistinct fluctuation; and, on the 22d, eight fluidounces of pus were withdrawn by the aspirator by Dr. Tyson. The minute opening did not close, but continued to discharge pus quite freely. His general condition, under the use of tonics and nutritious diet, remained quite good for some time, but by October he began to lose ground decidedly. There was an ulcerated opening in eighth interspace, from which large discharges of pus occurred daily. A probe could be passed six inches upwards and inwards through the intercostal opening. The liver-dulness began at sixth interspace, and extended to two inches below margin of ribs. Injections of various medicated liquids were used, but without any beneficial effects. Before December the tissues around the fistulous opening began to slough, and portions of the eighth and ninth ribs were exposed in a necrosed and roughened condition. His general condition grew rapidly worse, and death occurred on December 2d.

Autopsy, six hours after death.—The ulcerated surface on the right side was seven inches long by five wide, extending from the sixth interspace above to the eleventh below. It was perforated by an opening in the

eighth interspace, and by another some two inches in length in the ninth. Upon removing the sternum, nothing abnormal was noticed in the thoracic cavity, excepting an adhesion of the lower surface of the right lung, by slight cellular bands, to the diaphragm. No perforation of the thoracic cavity had taken place. Immediately below the diaphragm quite a large abscess was found occupying the right extremity and upper surface of the liver, the space between it and the diaphragm and right kidney, and communicating with the external opening.

Liver but slightly enlarged. Structures at a distance from the abscess fatty. Surface of right kidney ulcerated; its structure indurated and firm. No extended peritoneal involvement. The liver, diaphragm, ascending colon, and right kidney were firmly bound together, circumscribing the abscess.

This case presents several features of great clinical interest.

1. As to the locality of the abscess. The absence of the usual causes and symptoms of hepatic abscess, the previous severe pain in the right side, the point of rupture, and the physical signs, raised the question whether the case was one of circumscribed pyo-pneumothorax, or of abscess beneath the diaphragm. And the difficulty of determining this was increased by the close adhesions beneath the under surface of the right lung and the diaphragm, and the great degree in which the latter muscle was stretched upwards.

2. The question as to the starting-point of the disease. It might be regarded as possible that the disease had originated in connection with the rib; but a careful consideration of the case appears to render this untenable. It will be noticed that the hectic fever, which undoubtedly marked the occurrence of suppuration, preceded by some weeks the first appearance of external bulging. Again, the readiness with which a collection of pus forming in connection with the rib might discharge externally, renders it highly improbable that it could effect such extensive internal trouble before finding an exit through the skin. Abscess of the liver in rare instances arises in this climate idiopathically, or at least without recognizable cause, and it is very rare for the entire course of the disease to be unattended by any special symptom of hepatic disturbance. The *post-mortem* appearances of the liver, finally, show such a degree of destruction of its tissue as to indicate that the abscess originated in its substance.*

---

* To this must be added the absence of any traumatic cause of necrosis of the ribs, and also the absence, as shown by careful examination of the patient's history, of any syphilitic taint.

Dr. James Tyson remarked that from his knowledge of the case as it existed while under his care, he could not feel altogether satisfied with the idea of the hepatic origin of the abscess. The almost stony hardness of the tumor of the side as presented when he first saw the case, the remoteness from the liver of its most prominent portion, as well as its apparent superficial position, all led him to suppose it was associated at its beginning with disease of the ribs, although the traumatic nature of its origin as suggested by the patient was not entertained for a moment, as the gun-shot wound was on the opposite side. He had never suspected any relation of the abscess to the liver either primarily or secondarily.

Dr. Pepper said that against the idea of its having started from the ribs were the facts that while the man had suffered from pain on the right side for months, and that while there was found so extensive a lesion internally, the external swelling presented itself a comparatively short time before its evacuation; and we must suppose that if it started externally, it had perforated, by ulceration, the diaphragm and the firm fibrous capsule of the liver, and had destroyed a portion of the liver three inches in diameter by one and a half inches in depth. These facts, taken in connection with the well-known phenomena of hepatic abscess, its occasionally latent character, sometimes advancing to rupture without having given any marked evidence of disease of the organ, seem to leave no other conclusion to be arrived at than that it was a hepatic abscess which had worked its way externally to the point described.

Dr. R. M. Bertolet asked whether there were any evidences of embolic processes. Portal thrombosis being by far the most common cause of hepatic abscess, it is very important to ascertain the presence or absence of ulcerative and inflammatory processes in the intestines and gall-bladder; indeed, it is now denied by many that primary suppurative hepatitis ever occurs, but that the origin of hepatic abscess is by an embolus or foreign body obstructing a blood-vessel. Even traumatic affections of the liver only rarely lead to the formation of abscesses, and preferably when complicated by the presence of a foreign body.

Dr. Pepper replied that no careful examination had been made to this end, but that while abscess of the liver, especially of the metastatic form, which is so frequent, was apt to be attended by a partial stasis or thrombosis, he could not think that embolism was the only cause of such abscess. In a number of cases which he had studied of hepatic abscess following dysentery, he had observed portal thrombosis around the abscess.

Dr. Allen said that in gun-shot wounds of the liver the pus therefrom

was sometimes observed to have a peculiar color due to blood-staining, caused not so much, however, by the presence of blood as by its coloring-matter, hæmatin, or derivatives. *January* 15*th*, 1875.

---

25. *Peritoneal tuberculosis.*

By Dr. F. P. Henry.

I. J. H., æt. 40, was admitted to the male medical ward of the Episcopal Hospital about August 1st, 1874, for diarrhœa, and, after remaining for six or seven weeks, was discharged, apparently cured. He was again admitted about three weeks ago, the diarrhœa having returned, and was first seen by me at that time.

His symptoms on admission were—extreme emaciation, great feebleness, and profuse diarrhœa, averaging from twelve to fifteen watery stools in the twenty-four hours. There was no complaint of pain, and no cough. The abdomen was retracted, and slightly tender on pressure.

A variety of remedies were used, without effect, to check the diarrhœa, which, before death, became an almost continuous watery discharge.

The *autopsy* was made by Dr. Merrill, the resident physician, eighteen hours after death.

The *right lung* was found to contain a number of miliary tubercles unevenly disseminated through its tissue, but could hardly be said to be *infiltrated* with these bodies. There was a cavity about the size of an egg at the apex, very superficially seated in the lung-tissue.

The *left lung* was hepatized in the upper half of the superior lobe; a portion cut off sank in water. Tubercles were also found in small quantity in this consolidated portion and throughout the remainder of the lung.

The *heart* was healthy.

The *intestines* were covered with tubercles from the duodenum to a short distance below the ileo-cæcal valve.

The *mesentery* also contained these bodies and numerous enlarged glands.

A flattened tumor, several inches in circumference (about six), was found in the mesentery at or near its junction with the vertebræ. It is supposed to consist of a mass of tubercular mesenteric glands.

The *mucous membrane of the intestine* was pale, but apparently healthy; there was no appearance of tubercle or ulceration in it.

The *stomach*, *liver*, *kidneys*, and *spleen* were healthy.

The urine was examined before death, and found free from albumen.

I would like to ask the opinion of the Society as to the cause of diarrhœa in this and similar cases.

In *this* case, it has occurred to me that the tumor found in the mesentery might have caused pressure sufficient to paralyze some of the sympathetic fibres supplying the small intestine, and thus have given rise to a stage of congestion which relieved itself by a transudation of serum.

If nerve-fibres should be found to be involved in this mass, support would be given to this theory.

No traces of inflammation were found in the peritoneum.

January 15*th*, 1875.

---

26. *Scirrhous cancer of the pancreas, liver, and lung; hydatid cyst of liver.*

By Dr. H. R. Osgood.

The organs which I have the honor of presenting to the Society were taken from the body of a female, æt. 81. I was called to this person shortly before her death. Found her in great discomfort, the painful symptoms radiating from the vicinity of the stomach. Patient referred her pain to a spot somewhat at the left of the median line, but in the epigastric region. Pressure revealed the greatest sensitiveness in the median line an inch or two below the xiphoid cartilage. The patient was annoyed by constant vomiting, and was unable to retain either food or drink. It was principally with reference to this symptom that I had been called, for the pain just mentioned, although constant, was not excessive. It was only when I resorted to palpation that it became unbearable. Percussion also created such distress that because of the advanced age and great debility of the patient, and especially since I saw she was sinking, I refrained altogether from any attempt to establish a diagnosis, and directed my attention to the relief of the gastric symptoms. Under the influence of bismuth and morphia the vomiting ceased, and a fair amount of milk and lime-water, as well as beef-tea, was taken for a short time. Wines, including champagne, were not kindly borne. The heart pulsated normally. I discovered a mild bronchitis, which accounted for the patient's cough. There was obstinate constipation, which was relieved by enemata. After a day or two of the improved condition of the stomach, the patient again refused food of every sort. Injections of beef-tea were administered without avail, and she passed quietly away. I regret that my clinical details are

so meagre; yet, under the circumstances, I felt justified in sparing the patient what would have been a painful examination. She was in a too prostrated condition to give me her history. Her immediate attendants simply knew that she had been treated for dyspepsia during the past summer at the Women's Hospital. It was not until after her decease that I had the good fortune to learn some details of her history from a lady to whom the patient had several months ago related them. It seemed that the deceased referred the beginning of her illness to a day so long as twenty-five years ago, when she was engaged upon her son's farm in gathering stones, which she removed by the help of basket and apron. She had filled her basket, and then proceeded to fill her apron, the end of which she held in one of her hands. Upon lifting her basket with the other hand she suddenly felt something give way in the vicinity of her stomach. She fell senseless to the ground, and was carried to her bed, in which she remained for a period of eight weeks. Subsequently she labored constantly, but with less strength and vigor than formerly. Excepting that the patient never entirely recovered from the effects of this occurrence, I could learn nothing concerning her health during the seventeen years which intervened between this and another injury which the patient received in falling down a flight of stairs. This was eight years ago. She was again taken up senseless, and again confined to her bed for several weeks. Patient thought this fall aggravated the original injury, and never felt well thereafter. Previously a very stout person, she became much reduced in weight. She frequently said there was some internal derangement, and, curiously, imagined that her "sweetbread" was involved. She was familiar with the anatomy of the pig, and hence her remarkably correct supposition. The remitting symptoms of her ailment during the past eight years were great restlessness, irregularity of appetite, frequent vomiting of food, pain in the epigastric region, obstinate constipation. These data of her complaint became so severe in the early summer of last year as to lead her to seek aid at the Women's Hospital, where a physician examined her with great care and finally pronounced the difficulty a violent form of dyspepsia.

The friends of the patient consented to a *post-mortem* examination of the body. There was marked emaciation, but no external signs of injury. Heart somewhat atrophied, its muscular tissue flabby, valves normal. Slightly atheromatous condition of the ascending aorta. Left lung in a fair condition. Right lung bound down by pleuritic fibrous tissue of great age and immense strength, besides which the antero-posterior far exceeded the lateral diameter of the thorax. I could have removed the lung only

by slow dissection, and, having only half an hour for the entire examination, was obliged to leave the lung in position. I could see, however, that it was studded with pale-yellow nodules, varying in size from that of a pea to that of a filbert. I cut off a slice of lung containing one of these nodules, and have since examined it under the microscope. Upon uncovering the liver, I found its upper and anterior surface studded with projections varying in size, and of a color somewhat lighter than that of the surrounding hepatic tissue. Removed the liver, and found these nodules generally distributed throughout the organ. The whole liver was atrophied, especially the left lobe, in the lower border of which were fine specimens of scirrhous degeneration. In the same lobe and same situation, but nearer the longitudinal fissure, I found a beautifully-proportioned cyst one and one-half inches in diameter. Its walls consisted of firm fibrous tissue. It fluctuated but slightly. If I had then known that I would be permitted to take possession of these organs, I should have left the cyst intact for the observation of the Society. I opened it, and there exuded not fluid, but a thick cheesy matter, followed by a jelly-like mass of friable consistence. The cheesy matter occupied one-third of the interior of the cyst, and completely surrounded the gelatinous mass which filled the centre. The gall-bladder was distended by one large calculus. Removed the stomach. I found its internal surface in a condition of chronic hyperæmia, and abundantly covered by a catarrhal secretion. No contents; color dark brown; otherwise normal externally as well as internally. I next sought for the pancreas, in the place of which I found a large solid mass attached to the spinal column. I removed it together with the spleen, which came with it. Latter organ small and normal. Cutting into what I supposed to be the pancreas, but which was a shapeless mass, lacking the tail of that organ, my knife gave the "cry" characteristic of scirrhous tissue. In the mesenteric fat about it, were curious coils of calcification. Further than this I did not examine, except to see that the kidneys were normal. I saw that these organs presented the rare combination of scirrhous cancer and hydatid, and finally prevailed upon the friends of the patient to allow me to take them away. I regret that I was forced to leave the right lung. Upon subsequent examination of the contents of the cyst, I found in the jelly of its centre an occasional hooklet, crystals of cholesterine, débris of various sorts. It is then a hydatid cyst in a condition of fatty degeneration. I did not examine the cheesy matter, not deeming it necessary.

The embarrassing feature of these organs is the condition of the pancreas. What I supposed to be its body and head, upon further examination suggests an enlarged mesenteric gland. I do not find the head of the

pancreas. This mass is on the left of the aorta (which, I may remark at this point, is atheromatous and calcified). The superior mesenteric artery plunges into this mass, turns upon itself, emerges half an inch from its point of entrance, and terminates in the calcified loops already mentioned. I have indicated its course by a bit of cord. The splenic artery leaves the aorta (for there seems to be an extremely short cœliac axis) and runs straight to the left. But, while in its normal relation the artery passes along a groove in the upper border of the pancreas, in the specimen under consideration it passes outside the lower fourth of the mass posteriorly. Its left cut extremity, however, lies directly above a tissue which may suggest mesenteric fat, but which, judging from a very brief microscopic examination, I am inclined to think is pancreatic,—probably the remains of the tail of the pancreas.

On the other hand, the splenic vein, which normally pursues the same course as the artery, but in an opposite direction, coursing below its artery, begins at its splenic end in proper relation to its artery, viz., below it. Its course, however, takes it above the artery, and it finally plunges into and through the very centre of the fibrous mass at least an inch above the origin of the splenic artery. I have indicated the course of both artery and vein by straws. So much for the hints given by these vessels. The main question seems to be, Where is the pancreas? A portion of its body and tail is, I believe, to be seen. But the head has disappeared, and the fibrous mass lies to the left of the abdominal aorta, the proper position of the head of the pancreas being on the right of that tube. The fact that the superior mesenteric artery forms its first loop in the substance of the fibrous mass would seem to be a proof that this mass is an enlarged gland. But in its very centre we find the splenic vein, and at its left border pancreatic tissue. May not this body have taken up the head of the pancreas as well as the splenic vein? Concerning its actual situation in the body of the patient, judging from its relation to the abdominal aorta and such of the pancreatic tissue as we find, it may be taken for granted that it lay a little to the left of the normal site of the head of the pancreas, but that, while a portion of its bulk occupied a plane somewhat above the normal level of the body of the pancreas, its main bulk took the place of the body and angle of that organ. As already mentioned, the splenic artery at its left extremity lies upon pancreatic tissue, and immediately in connection with the tissue was the spleen, which I removed and left behind. This residue of the pancreas appears to extend directly into the fibrous mass at the right. I have refrained from mutilating the mass beyond the original cut, thinking it would be more instructive if I left the specimen as it is,

for the inspection of the members, hoping it would then be referred to the *Committee on Morbid Growths* for further examination.

After I had gained the unexpected permission to take the organs away, I sewed up the hydatid cyst with its contents and restored it to a condition which will sufficiently indicate its original appearance.

The small nodule which I removed from the lung, I have examined under the microscope, and find its structure similar to that presented by the nodules in the liver. The combination of conditions shown by the specimens is rare. We have cancer of the lung, cancer and hydatids in the liver (I cannot say there was no hydatid in the right lung), and a condition of the pancreas which demands further study. In regard to the cyst, I would call attention to the fact that it existed in the body of a person 81 years of age, which is very unusual. According to Budd, hydatid tumors are so rare in the aged that he limits them to the years of life between six and fifty. The oldest of Frerichs's hydatid-patients was sixty-five. Davaine finds this form of tumor between the ages of twenty and forty. Single hydatid cysts are also very rare in the left lobe of the liver.

I will add merely that the specimens have been kept in a fifteen-grain solution of chloral, and have, I think, retained their original color, consistency, and freedom from odor more perfectly than would have been possible in any other preservative. *January* 15*th*, 1875.

---

27. *Cirrhosed liver and congested stomach.*

By Dr. F. P. Henry.

The specimens were removed from a woman æt. 53, who was admitted to the hospital on December 8th, 1874. She first noticed a fulness of the abdomen in July last, which increased for three or four weeks and then disappeared under medical treatment. Early in October the abdomen began to enlarge again, and continued to do so until she applied for admission.

At that time there were all the signs of abdominal dropsy, which existed in so great a degree as to cause orthopnœa for the first two or three days after admission. There was also well-marked jaundice, and some œdema of the legs and feet. The abdominal distention was so great that the liver could not be felt, and this distention rendered it also impossible to deter-

mine accurately the vertical diameter of the liver. The bowels were moved three or four times daily without medicine.

There was no albumen in the urine. As the patient refused to submit to tapping, elaterium in daily doses of one-tenth grain was given, but produced no increased action of the bowels; on the contrary, the bowels became rather more constipated.

On the 18th, the skin on the back and legs ruptured; this was followed by a steady discharge of serum. The abdomen became softer, but the constipation became more obstinate, and about this date she was given one-tenth grain of elaterium hypodermically; this produced no effect, and was repeated on the 20th. The elaterium again produced no effect. On the 22d, there was slight discharge of fæces in response to an enema.

The patient became gradually weaker, the jaundice more intense, and a mild, cheerful delirium supervened.

For the last two days of her life she swallowed with difficulty, and was supported almost entirely by nutritive enemata.

At the *autopsy*, six hours after death, the *abdomen* was found distended with yellowish serum; the *liver* hard, covered with nodules, and of a brownish-yellow color; weight, three and a half pounds.

Spleen much enlarged and congested, its capsule thickened and opaque, but easily detached.

Kidneys healthy; *heart* also healthy.

Commencement of *aorta* atheromatous.

Lungs hypostatically congested, otherwise healthy.

The *stomach* contained a quantity of coagulated blood, which must have been poured out shortly before death, as no hæmatemesis had taken place. Mucous membrane of stomach reddened and swollen.

January 15*th*, 1875.

---

28. *Gummata in the liver.*

By Dr. A. C. W. Beecher, for Dr. J. C. Norris.

The specimen was derived from C. L. J., æt. 60 years, American, strictly temperate; had had no serious ailment prior to the sickness from which he died; denied having had venereal disease; no intermittent fever; no dysentery; no hæmatemesis; no dropsy. He was a confectioner until eight years ago, since when he had not been engaged in any business. His family

for several generations was healthy; no history of cancer, consumption, or syphilis. The last sickness was of sixteen weeks' duration; he was deeply jaundiced after the first week. He was costive during the first six weeks, after which his bowels were moved daily without medicine, the stools being clay-colored from the first, and continued so until death.

There was no pain at any time in any of the abdominal organs, and no enlargement. Urine passed in normal quantity and deeply colored. He expectorated large quantities of frothy matter, occasionally colored with blood. He suffered from a great irritation of the skin, compelling him to scratch all night unless under the influence of anodynes.

The above history was given to me by Dr. J. C. Norris, at whose request I made the *post-mortem* examination, assisted by Dr. Isaac E. Roberts.

Post-mortem examination.—Skin deeply jaundiced, body somewhat emaciated, abdomen rather scaphoid.

The abdominal viscera were all deeply tinged with biliary coloring-matter; otherwise healthy, except the liver, which, though normal in size, had a hard mass of tissue at its transverse fissure, and surrounding the vessels entering there. There were a few hard nodules in the longitudinal fissure, and these were very small. The vessels entering the liver were markedly encroached upon in their calibre, the portal vein and hepatic artery being reduced to about one-eighth of an inch in diameter. The gall-bladder was not distended, and upon pressure there exuded a transparent straw-colored or yellow fluid of syrupy consistence. Upon plunging a scalpel into the substance of the liver, a fluid similar in character to that from the gall-bladder poured out: it was not so thick, however. The quantity amounted to several ounces. This fluid seemed to come from the dilated hepatic ducts, which were very much enlarged; in the hepatic duct, just before it entered the cystic duct, there was a dilatation equal in size to a shell-bark. Though there was apparently no obstruction of the common bile-duct or of the cystic duct, yet the fluid in the liver did not exude under slight pressure.

The heart was small, but healthy; the lungs healthy, but some old pleuritic adhesions existed on the right side. No abnormal effusions in any of the cavities either of chest or abdomen. Kidneys healthy, but stained with bile.

Dr. S. W. Gross asked whether the growths had developed from the secreting tissue of the liver or in the connective tissue about the transverse fissure.

Dr. R. M. Bertolet, to whom the specimen had been referred for microscopical examination, said he had not had time to make a satisfactory exami-

nation. The sections he had removed contained nothing beyond connective tissue and fat-globules, further division of the growths being deferred until it had been exhibited. The tumor, when he first saw it, was about as large as a shell-bark, had surrounded the portal vein, and produced evident constriction. The matters contained in the gall-bladder and biliary ducts were biliary, and gave the usual reaction of the bile-pigments. If it should be scirrhus, it is certainly a very unusual site for it. There are, on the other hand, many clinical facts against it. In the first place, primary cancer of the liver is exceedingly rare; three-fourths of all cancers of the liver are secondary, and of these two-thirds are metastatic to primary growths in the visceral area of the portal circulation. Further, it has some suspicious appearances which suggest a gummy tumor, which, although usually occurring in multiple form, is sometimes isolated.

Dr. Gross said his reason for asking the question lay in the fact that all the specimens of carcinoma of the liver he had seen had been developed in the substance of the liver, and not in the connective tissue, while it is well known that it is claimed that cancer is never developed in connective tissue, but only in glandular structures.

The President said that the specimen was one of great clinical rarity, whatever the nature of the growth might be. In carcinoma of the liver, masses of varying size are frequently seen developed from the glands or connective tissue in the transverse fissure of the liver, without actually involving the hepatic structure. The walls of the gall-ducts or bladder, or less frequently of the blood-vessels, may either become involved in the disease, or may be compressed so as more or less to obstruct the lumen. Nearly always in such cases there has been disease of other portions of the liver-structure associated; and he could not remember more than a very few instances where carcinomatous growths had appeared limited exclusively to the tissues in the transverse fissure of the liver. If this specimen be of malignant nature, therefore, it certainly should be regarded as of unusual interest.

Dr. Bertolet said the latter question was answered by the fact that secondary cancers of the liver often could be clearly traced to cancerous thrombi in the vessels of the organ, the infecting mass being developed in and spreading from these thrombi. Virchow has even seen a thrombus of the portal vein undergo complete carcinomatous degeneration when there had been as yet no extension to the surrounding tissues. Naunyn goes so far as to say that all secondary cancers of the liver originate as cancerous degenerations of thrombi,—that the majority of carcinomas of the liver start out from branches of the portal vein; but, as this growth lies out-

side and not within the lumen of the vessel, such a thrombic source is excluded.

Dr. B. stated that he had recently had the opportunity of studying several fine specimens of secondary hepatic cancer, and had noted that a peripheral or portal invasion of the acini seemed to be the rule, and that all attempts to inject the portal vein had signally failed.

February 11*th*, 1875.

Report of the Committee on Morbid Growths:

"The hepatic growth presented by Dr. Beecher consists of a dense whitish cicatricial tissue, in which are imbedded irregularly-shaped, yellowish, cheesy masses. The great preponderance of the gray fibrous tissue gives the growth a dense, scirrhus-like consistence. Bands of connective tissue permeate the growth in every direction, and, extending along the portal vein for a considerable distance beyond the point of constriction, render its walls thick and inelastic.

"Microscopically, the large nodule attached to the portal vein is made up of the fibrous tissue already mentioned, granular hyperplastic cells, and oil-globules. The central portions of the growth are in a more advanced stage of fatty and cheesy metamorphosis.

"There can be little doubt that we have here to deal with a mass of sclerotic tissue, the condensation and retraction of which have led to the partial stenosis of one of the branches of the portal vein and the occlusion of the adjacent biliary ducts; so that the latter can be readily traced to the surface of the organ, where they at times are dilated to the size of a crow's quill.

"No traces of a lymph or glandular structure could be discovered in any part of the growth. Whether the hyperplastic mass was irregularly called forth by syphilis or some other irritant the clinical history of the case perhaps may disclose, but, until the contrary is proved, your committee are inclined to regard it as a *gummata*."

---

29. *Epithelial cancer of rectum.*

By Dr. Leonardo S. Clark, for Dr. Abraham S. Gerhard.

Mrs. Christine S., æt. 52 years; a widow for four years; housekeeper; native of Würtemberg, Germany; had borne four children; no miscar-

riages; no previous disease of consequence; past the climacteric six years; no carcinoma in family from grandparents down, so far as known; suffered from lateral curvature of the spine (to the right) from childhood, the cause of which is not known; she has children aged respectively thirty-two, thirty, twenty-four, and sixteen years, all healthy; husband died of general carcinomatous degeneration of lungs, pancreas, and mesenteric glands.

Mrs. S. was of phlegmatic temperament, had blue eyes, light-brown hair, and a gentle disposition. The peculiar cachectic appearance was well marked.

Nine years ago she first noticed a lancinating pain in the rectum. She never mentioned it for a period of nearly seven years, although she suffered greatly at times. Two years ago she complained to one of her daughters that "her womb was forced down." The fact was communicated to her physician, but, on account of her great diffidence, no personal examination was made until about one year ago, when it was found, upon both vaginal and rectal examination, that the womb was retroverted and prolapsed, and that this displacement of the organ was caused by a large tumor of the rectum above it, which tumor was to the touch hard, nodulated, and cartilaginous. *Cancer of the rectum* was immediately suspected, and the diagnosis was subsequently confirmed by Drs. Goodman and Merklein.

The symptoms from that time until death were those of sharp, lancinating pain through the pelvis, great difficulty in defecation, accompanied with excessive tormina and tenesmus, partial protrusion of the uterus and posterior portion of bladder, with general failing of strength. On New-Year's day she paid a visit to her physician, although in great pain and distress, and on the morning of the 2d of January she died with symptoms of obstruction of the bowels, although there was no stercoraceous vomiting.

The *post-mortem* examination was made by me, twelve hours after death.

Rigor mortis was well marked; the body was emaciated, and the belly enormously distended with gas; its integument was partially decomposed. Upon dissection, the peritoneum was found to be universally injected, and there were a few pelvic adhesions. The small and large intestines were greatly distended with gas and fecal matter, which had to be evacuated before the pelvic organs could be removed.

Upon removal of the latter, the uterus and bladder protruding through the vulva, a hard, cartilaginous, nodulated mass was found occupying the rectal walls for a distance of about six inches in length and two and a half inches or more in diameter, starting from within three inches above the

sphincter ani. To this was adherent a portion of the small intestine. All the other pelvic and abdominal organs appeared to be normal, except that there was some erosion of the os uteri.

A longitudinal section of the diseased part showed the canal to be pervious, the mucous membrane near the centre of the diseased mass to be ulcerated and of a dark congested appearance. The knife, in passing through the morbid tissue, grated, and the part felt dense. The cut surface was white and streaked.

The President inquired of the surgeons present whether the submucous form of cancer of the rectum, of which this appeared to be an example, was more frequent in their experience than that attended by outgrowths from the mucous membrane encroaching upon the lumen of the canal. His own experience furnished more of the latter variety than of the former.

Dr. John Ashhurst, Jr., said that no doubt, in the majority of cases, the growths ultimately involved the mucous membrane and projected into the bowel, but in the early stages the mucous membrane might not be involved. In the case just reported, he thought that the fatal result was due not so much to the existence of cancer as to the presence of some independent source of obstruction (such as a volvulus), as shown by the fact that after death the bowel was found pervious. Probably had this patient lived longer, and the disease thus been allowed to run its course, the mucous membrane would have become implicated, and the growth would have protruded into the gut, perhaps itself eventually producing fatal obstruction.

Dr. R. M. Bertolet was inclined to agree with Dr. Pepper that cancer of the rectum most frequently manifested itself in a protrusion of the mucous membrane towards the lumen of the tube. Indeed, Billroth has pointed out that the rectum is the favorite seat of that form of epithelial growth known as adenoma, which, beginning as a hypertrophy of the follicles of the mucous membrane, involves the outer portions of the bowel secondarily.

The President said he had been impressed with the difference in the appearances produced by cancerous infiltration of the submucous tissue in different parts of the alimentary tract. Thus, at the pyloric orifice the disease very often goes on to extreme obstruction without ulceration, and especially without formation of growths projecting from the mucous surface. In cases of cancer of the rectum, even in its early stages, on the other hand, it had seemed that there was much more frequently, in addition to submucous thickening, more or less of such free growth.

He desired also to know whether it did not coincide with the experience of the members where death has ensued during organic disease of the bowel to find at the *autopsy* a greater degree of apparent perviousness than was anticipated before death, when, indeed, the bowel might seem to be almost completely obstructed.

Dr. Ashhurst said that the remarks of the President were no doubt correct. As he (Dr. A.) had already remarked, he did not doubt that in this instance the fatal obstruction was due to a twisting of the bowel or to some similar cause, and that the patient therefore actually died from intestinal obstruction, and not from cancer. *January* 15*th*, 1875.

Report of the Committee on Morbid Growths:

"The rectal tumor presented by Dr. Clark is an epithelial carcinoma.

"The peripheral portions of the growth show not only a regular cylindrical arrangement of the epithelial elements, but also a distinct limiting membrane or tunica propria. In the more central portions of the tumor the arrangement is less suggestive of a glandular structure; the tunica is absent, and the connective-tissue stroma is more richly developed, but not to such an extent as to warrant the designation of scirrhus."

February 11*th*, 1875.

---

30. *Multiple hernia.*

By Dr. De F. Willard.

The specimen was obtained from A. B., a woman æt. 40. She has had femoral hernia for eight years, wearing a truss, and suffered no serious inconvenience until 6 A.M. on the 27th of January, 1875, when she found that the intestine had protruded and could not be returned. Pain commenced about 8 o'clock, soon after which unsuccessful efforts at taxis were made by a physician. She was admitted to the Presbyterian Hospital at 1 P.M. on the same day. Dr. H. Lenox Hodge attempted reduction, both before and after drawing off the gases by an aspirator, but both efforts proved unavailing, and by 9 P.M. the loop of intestine had again become greatly distended. The pain, vomiting, etc., became more and more serious, and at 1 A.M. the ordinary operation for the relief of strangulated femoral hernia was performed by Dr. H. It being necessary to open the sac, the bowel was found deeply congested, but its vitality was good, and it was carefully returned into the cavity of the abdomen.

The patient reacted well, but in twelve hours tympanites appeared, the pulse became rapid and feeble, while nausea, vomiting, and the usual symptoms of peritonitis soon supervened.

Upon the second day she aborted of a two-and-a-half months' fœtus,* after which the symptoms grew rapidly worse until she died, about forty hours after the operation.

Upon examining the cavity of the abdomen, a small amount of effusion was found present, but the existence of general peritonitis was evidenced by lymph glueing together all the intestines and covering in the uterus. The loop of intestine was still in the bent condition in which it was returned, being held loosely by soft lymph, but its calibre was perfectly patulous, and, though congested, it was not all gangrenous. The internal crural ring was blocked by a mass of fresh lymph, but bore no evidence of being the centre of inflammatory action.

Upon examining the opposite side, it was found that a large loop of the omentum had passed through the left internal abdominal ring, and was fastened in the canal; while at the thyroid foramen existed another epiplocele, the omentum having passed out alongside the obturator vessels to the extent of one and a half inches. *March 25th*, 1875.

---

31. *Verbal communication on intestinal obstruction caused by huge thrombus resulting from rupture of the abdominal aorta.*

By Dr. Wm. Pepper.

The patient was an old man, æt. 82, who had long suffered with a right inguinal hernia. For some time before his last illness he complained of pain in that region. When seen first by Dr. M. Woods, his attending physician, he was complaining of considerable abdominal uneasiness, and there was obstinate constipation. This continued despite the use of large enemata and full doses of powerful cathartics. When first seen in consultation, there had been no fecal evacuation for at least ten days. There was frequent hiccough, but no actual vomiting. There had been, however, very little food taken during that time. The patient was delirious, and difficult to restrain. The pulse was frequent and small; the radial arteries very atheromatous. There was no hernia detectable in

* This accident was entirely unlooked for, as she had been a widow for five years.

either groin. The abdomen was distended, and the walls enormously fatty, so that careful palpation was impossible. The amount of urine secreted was difficult to estimate, as it was passed in the bed. Digital examination of the rectum showed that this part of the bowel was clear. Attempts were made to give large injections by a syringe, which was found impossible. By employing hydrostatic pressure (gained by pouring water from a height of about six feet above the body through a flexible tube furnished with an olive-shaped end) about one and a half pints of water were forced into the bowel; when this escaped, it brought several pieces of hardened fæces. It was again attempted, but it was impossible to make the bowel contain as much the second time, and no result was obtained. The diagnosis, therefore, was readily arrived at, notwithstanding the complication of the case with an old hernia, that there was some increasing obstruction low down in the bowel, and probably in the sigmoid flexure of the colon.

Death ensued forty-eight hours later, from exhaustion. At no time had the obstruction been so complete as to prevent the passage of some flatus.

At the *post-mortem* examination the right inguinal canal was found much dilated, but containing no hernia. The cause of obstruction was sought by following the intestines downwards from the stomach. There was no trouble in the course of the small intestine, which was, however, very unequally distended, some parts being very full, others almost empty, small, and compressed-looking. On reaching the descending colon, it was found to be strongly adherent to and much compressed by a large mass which occupied the left lumbar region. This mass was about nine inches long, four and a half inches wide, and three inches thick. On incision, it was found to be an enormous clot of blood, evidently of some duration, being blackish, firm, and infiltrating the fatty and cellular tissues of the part. The aorta was imbedded in this clot, and on discovering and laying open this vessel its walls were found in a state of such intense atheromatous degeneration that they had given way, and several ruptures had occurred in the inner and middle coats of the vessel. The huge clot above described was, therefore, in part a dissecting aneurism, and in part depended on the escape of blood through the adventitia infiltrating the surrounding cellular tissue. No distinct aneurismal sac could be detected. The obstruction of the intestine was entirely due to the pressure of this mass, and was most marked low down in the sigmoid flexure of the colon, thus agreeing closely with the seat as determined by previous examination.

April 8th, 1875.

32. *Cancer of the liver.*

By Dr. O. H. Allis, for Dr. Mixsell, of Easton, Pa.

P. R., æt. 50, hotel-keeper, sedentary habits. Dr. M. was called to see him January, 1875. He had then been sick one month. The pulse was found normal, tongue clean, and bowels regular; urine markedly albuminous. There was œdema of the extremities, with serous accumulation in the serous sacs, three pints of turbid serum being drawn from the abdominal cavity. Death occurred in April, possibly from starvation.

Autopsy.—The liver was enormously enlarged; the heart, lungs, and stomach were displaced, and the peritoneal cavity filled with pus and serum.

April 22d, 1875.

---

33. *Biliary calculi impacted in the left branch of the hepatic duct, attended with numerous cystic formations in the corresponding lobe of the liver.*

By Dr. R. M. Bertolet.

The specimens were obtained at the obduction of J. G., æt. 65, who was admitted into the Philadelphia Hospital in a semi-comatose condition upon May 20th, 1875. No previous history of the case was obtainable; death ensuing in less than twenty-four hours. The clinical records are also very unsatisfactory. There was noted a moderate jaundice; high temperature; hurried respiration; hypostatic dulness, and vomiting.

Autopsy.—The lungs were œdematous; bronchi filled with a frothy serum; heart slightly enlarged; the left ventricle hypertrophied; semilunar valves thickened; aorta atheromatous. The stomach presented several small patches of erosion and ulceration of the mucosa. Towards the pylorus the serous membrane was intensely injected, and had formed slight adhesions to the hepatic organ. The mesentery and the serosa covering the small intestines were likewise, at points, strongly injected, with here and there ecchymotic blotches. A very small quantity of flocculent serum was found in the abdominal cavity. There were no intestinal ulcerations. The spleen was flaccid, reduced to a soft, almost pulpy, mass, somewhat reduced in size. Kidneys were enlarged, soft, with cortical cloudy swelling of the convoluted tubules; the capsule separating very readily.

The liver was of normal size, very much softened, with a slightly rough-

ened capsule. In the left lobe a number of cysts were seen bulging above the level of the convex surface. Upon removing the viscus, one of these thin-walled cysts was ruptured, and a quantity of yellowish, creamy matter escaped into the abdominal cavity. Probably a similar escape of pus took place during life, thus giving rise to the slight peritoneal inflammation. Examining the liver more minutely, it is seen that the left lobe throughout presents numerous cystic patches, which communicate with one another. These cysts vary in size from a small pea to that of an almond. They are filled with thick, yellowish, turbid fluid, often mingled with numerous small, black and ochre-colored concretions. In the transverse fissure of the liver two cylindrical-shaped biliary calculi, each about the size of a marble, were felt completely occluding the left branch of the hepatic duct. When first removed, the outer layers of these concretions appeared soft and crumbly; the interior nucleus being much firmer in consistence and darker in color. There was decided thickening of the walls of the left branch of the hepatic duct; while at the same time the surrounding connective tissue was hypertrophied to such a degree as firmly to bind down these two calculi in their position in the hepatic duct. The index-finger could be readily inserted into this portion of the biliary tube after removal of the calculi. Immediately beyond the point of constriction ampullar-like dilatations began to be developed, attaining their maximum size, however, in the ultimate twigs of the biliary ducts towards the periphery of the organ, where the least resistance presented itself; there forming the numerous cystic distentions seen strewn over the entire left lobe.

The gall-bladder was filled with a thin, yellowish secretion, free from concretions. The ductus communis choledochus, as well as the cystic and hepatic duct, excepting its left branch, were found to be freely pervious.

That these cysts, so closely resembling in appearance multiple hepatic abscess, are the resultant of the obstructions in the hepatic duct, is evident from the fact that they contain a greater or less number of small biliary concretions, and that their walls at points still present the remnants of a columnar epithelial lining. Further proof of such an origin is afforded, should any be required, in the microscopical appearances presented by the hepatic parenchyma even at a considerable distance from the cysts.

The ultimate radicles of the bile-ducts are microscopically seen to be filled, at a few points actually dilated, with a fine granular biliary coloring matter. Often entire meshes are formed by these blackish lines of pigment in the biliary capillaries, each inclosing a single liver-cell; so that we have before us the finest picture of a natural injection of the gall-capillaries,

excelling by far the famous Chronszczewsky artificial preparations. This pigment-matter marks not only the periphery of each lobule, but extends into the very centre of the acini; and here and there are also found single large fragments of gall-pigment lying between the hepatic cells. The latter are undergoing atrophic changes and disappear under the encroachments of the cysts. The hepatic cells in this specimen are unquestionably undergoing fatty degeneration, nor do I believe that this condition is entirely attributable to post-mortem changes, as Heinrich Mayer* claims. This experimenter succeeded in filling the biliary radicles with granular pigment, by ligating the ductus choledochus of various animals, but states that gall stasis is not attended with fatty degeneration.

Leyden,† on the other hand, concludes from his experiments that fatty infiltration of the hepatic cells does occur, which eventually leads to the atrophy changes.

Wyss also noted the same phenomena where the hepatic duct had become closed by a carcinomatous nodule. It will be seen without further citation that there is a certain amount of conflicting evidence as to the processes which cause the dissolution of the secreting parenchyma, and I desire to place this case on record as one attended with decided fatty infiltration. It is generally admitted that the disappearance of the hepatic cells is not due to any solvent action of the retained biliary secretion itself.

Without going into minute details, I can fully confirm the statement of Mayer, that the protracted stasis of gall causes an increase of the connective tissue of the liver, not only around the blood- and biliary vessels, but also in the centre of the lobule, where the sustentacular substance is increased to such an extent as to push the secreting cells asunder.

The presence of calculi in the hepatic duct is an extremely rare occurrence. But a comparatively limited number are recorded, and of these many were kept back by the simultaneous filling of the common duct with calculi. Although in this specimen we find the concretions firmly clasped in position, yet upon their removal the biliary duct is not stenosed, and it is a difficult matter to explain, in the absence of new growths or other obstructions, how they came to be retained in this site, where the tube is decidedly much wider than any of its branches. No account seems to have been hitherto taken of the part that is probably played by the numerous blind ramifications in the transverse fissure of the bile-duct, now generally designated by histologists as *vasa aberrantia*.

---

* Wiener Med. Jahrb., 1872.

† Beiträge zur Pathologie des Icterus, 1866.

These receptacles for bile, which are quite numerous around the hepatic duct, may, in a yet undetermined manner, account for the arrestation of calculi in this site. Biliary cysts due to mechanical obstruction and stenosis of other portions of the gall-duct have been frequently recorded, and they seem to be often met with in sheep afflicted with distoma hepaticum. Rupture and escape of the cystic contents into the peritoneal cavity occasionally happen. The clinical picture presented by these cases is not yet as sharply delineated as desirable, and I regret that this well-marked case does not enable us to learn anything in this respect. *May 27th*, 1875.

---

34. *Multiple cavernous angeioma of the liver.*

By Dr. R. M. Bertolet.

This unusually fine specimen, unique among the presentations to this Society, was removed from Patrick S., a laborer, æt. 50, a native of Ireland. He died upon April 30th, two days after his admission into the medical wards of the Philadelphia Hospital. He was carried off by an acute croupous pneumonia of the right upper lobe; during his illness there was no hepatic tenderness, nor any jaundice, or other symptom manifested to call especial attention to the liver.

The *autopsy*, however, disclosed six large dark-bluish spots of considerable size, some of them measuring over an inch and a half in diameter, scattered through both lobes of the liver. These growths are seated in both the anterior and posterior surfaces, most abundantly towards the lower free margin. Their conical or wedge-shaped appearance upon section, as well as their peculiar coloration, led them to be mistaken upon first sight by the resident physician for hemorrhagic infarctions. This mistake is, no doubt, frequently made, since the liver is unquestionably the most favorite seat for these tumors; yet in this site they so far remain unrecorded in our proceedings. A careful inspection with the unaided eye, however, suffices to show that they are actual new growths, with a thin, whitish, reticulated net-work running through them and forming small angular meshes, the cavities of which are filled with dark, coagulated blood; the whole giving to the cut surface an appearance not unlike the alveolated structure of the lungs. The blood can be readily squeezed out from the spongy, cut surface, when the reticulated structure becomes still more evident. In this specimen the tumors, although most of them are

directly under the capsule, do not project or bulge above the general level of the surface, excepting one of the largest, which is seated in the lower border, and there presents slight elevations both upon the anterior and posterior surfaces. The centre of each growth further presents a dense, broad band, looking not unlike an obliterated and thickened blood-vessel.

Formerly, the term "fungus hæmatodes seu spongiosa" was applied to these growths, but it has also been bestowed upon cancerous, sarcomatous, and other malignant tumors whenever they presented an unusually vascular appearance, thus leading to much deplorable confusion. Virchow was the first to designate these growths as *angeiomas* which are formed by a hyperplasia and ectasia of the capillary loops of the blood-vessels in a circumscribed locality. When, as always happens in the liver, these vessels are so distended as to form large sinuses or mere vascular spaces, then we have presented a structure the physiological paradigm for which is found in the corpus cavernosum of the penis, and which is now designated as the *cavernous* form of angeioma.

Microscopically, the accompanying slides present an appearance so closely corresponding with the admirable delineation given by Frerichs* that I doubt whether a more accurate drawing for these specimens could have been made. Under higher powers, it becomes evident that the vascular spaces are lined with a single layer of endothelial cells; while the meshes are seen to consist of a dense fibrillated connective tissue, with few cellular elements. Smooth muscular fibres and a certain amount of elastic tissue also aid in forming the bulk of the whitish septa. Enormously dilated blood-vessels, whose thickened walls together with connective tissue form the irregularly-shaped meshes, may, therefore, be said to constitute these tumors. The peripheral portions are by far the most interesting, for we are enabled not only to observe how the adjacent hepatic cells undergo fatty metamorphosis and gradually disappear under the encroachments of the tumor, but here, also, the actual steps in their development can be readily studied. The larger growths in this specimen are not surrounded by well-defined capsule, as sometimes happens, and as is the case in the numerous small cystic angeiomas to be referred to presently; but there are seen, here and there, bands of connective tissue extending between the acini. These bands, both in position and appearance, resemble the cicatricial tissue observed in advanced cases of cirrhosis, with this difference, that the one is circumscribed, while the other is diffused.

The offsets from these angeiomas are extremely vascular; even in them

* Klinik d. Leberkrankheiten, Atlas., Taf. VI. Fig. 5.

the capillaries are beginning to widen. This teleangeiectasic condition is also possessed in common by the cirrhotic tissue, as has been recently pointed out by Cornil* and Rindfleisch.† A localized interstitial hepatitis is, therefore, the preliminary process, while the granulating connective tissue formed thereby, being unusually rich in blood-vessels, presents the most favorable conditions for the subsequent development of the angeiomatous growths. This predisposition to the formation of sclerotic tissue is, in this specimen, certainly a localized one, for sections made through the hepatic tissue at some distance from the tumors fail to reveal even the earliest stages of indurative interstitial hepatitis.

From injections that I have formerly made upon other specimens of hepatic angeiomas, I am fully convinced of the correctness of the disputed statement that they can be filled only from the branches of the hepatic artery and portal vein, and that the lumen of the branches of the hepatic vein becomes compressed and obliterated. The multiplicity of these growths is a very ordinary occurrence, but it is extremely rare for them to attain the size of a walnut,‡ which is certainly exceeded by several of the tumors in this specimen.

The interest in this liver, in addition to the tumors already mentioned, is heightened by the presence of numerous (I have counted over fifty) small cystic formations. These vary in size from that of a pin's head to a small pea. They are generally filled with fluid blood; have a distinct limiting capsule; are clothed with endothelium, and frequently present slight ridges upon their interior surfaces.

These cysts are scattered over the entire surface of the organ, and but few of them are concealed beneath the surface. Their endothelial covering, alongside of their contents, indicates their origin from the blood-vessels, perhaps by simple dilatation, but more probably also by the atrophy of the septa, the remains of which are seen as ridges upon the inner walls. Such an interpretation has been given by R. Volkmann,§ in a case of *angeioma cavernosum hæmatocysticum nymphæ*, and I think can also be accepted here. The minuteness of some of these cysts led me to hope that it would be possible to ascertain in what part of the territory of the acini they first begin to develop. Unfortunately, this could not be definitely determined in the absence of any injection, which had been rendered impossible by previous mutilation.

---

* Archiv. de Physiologie, Mars et Mai, 1874, p. 272.

† Lehrbuch d. Path. Gewebelehre, 2 Aufl. S. 417, Fig. 145.

‡ Virchow, Geschwülste, Bd. iii. S. 392.

§ Archiv f. Klin. Chirurgie, Bd. xv. p. 568.

Clinically, it is, of course, impossible to diagnose these hepatic angeiomas, and Frerichs states* that he knows of no case in which they have given rise to local or general disturbances. Angeiomas sometimes, however, lead to the development of melanotic sarcoma, and then become highly malignant, a by no means rare occurrence when they are seated in the skin.

The President believed that the specimen was the first one of angeioma of the liver ever presented to the Society,—at least with a definite description of the lesion. It is very rare, at least, to find multiple lesions of this kind. He was able to recall two cases, in both of which the tumor was at the border of the liver, and triangular in shape. One was at least two inches in diameter, the other smaller, but both projected beyond the surface of the organ. The resemblance to hemorrhagic infarctus was more superficial than real, as the surface on a fresh section reveals to even slight examination the characteristic reticulum.

Dr. Bertolet said that eight days ago he had met with a single angeiomatous tumor in the liver, also in a male subject of advanced years. Out of an equal number of *post-mortem* examinations, he thought they were more numerous in a late than in an early period of life. He recalled but one or two cases recorded where there were any decided projections from the surface of the organ; but, as a rule, the seat was somewhat depressed. Those which caused a protuberance were seated in the lobus Spigelii.

The President replied that the protrusion was not excessive; but in passing the hand over the convexity of the liver it was appreciable. He thought that the surface of the growth was one-third of an inch above the surface of the hepatic tissue. The reticulum was very loose, and the meshes exceedingly large. *May* 13*th*, 1875.

---

* Leberkrankheiten, Bd. ii. S. 214.

III.—THE VASCULAR SYSTEM.

1. *Disease of the mitral and aortic valves.*

By Dr. J. E. Mears.

The specimen was removed from a patient of Dr. R. R. Taylor.

The patient had been confined ten days previous to the attack. On that day she was exposed to cold, and symptoms of pulmonary congestion rapidly manifested themselves. The heart's action was markedly increased, the pulse attaining 130 beats per minute.

On auscultation, *no mitral murmur* could be detected. The pulmonary sounds and the extremely rapid movement rendered the aortic murmur very indistinct,—almost inappreciable. Arterial sedatives were employed without effect, as well as remedies both internal and external to relieve the congestion; the patient dying on the second day of the attack, from exhaustion.

Post-mortem examination revealed disease of both mitral and aortic valves. A mass, apparently of vegetations, covered the auricular surfaces of the mitral valves, leaving an opening between the auricle and ventricle about the size of a crow's quill. The nature of this mass was not determined by microscopic examination. The aortic valves exhibited structural changes, but to a much less extent.

A question of clinical interest presented itself in reference to the absence of a mitral murmur, with the valves in the condition observed, and with the extremely rapid action of the heart. *January 8th*, 1874.

---

2. *Advanced mitral disease of the heart, conjoined with disease of the kidneys.*

By Dr. James Tyson.

Case I.—Mary K., 39 years of age, married, was admitted to the Philadelphia Hospital on November 15th, 1873. Both of her parents suffered

from rheumatism and subsequent cardiac disease, and her mother died with dropsy, which came on after confinement. The patient herself had several attacks of rheumatism, but in other respects enjoyed fair health until about five months before admission, when she began to notice shortness of breath on exertion, together with œdema of the legs and ascites. At that time she was five months advanced in pregnancy. These symptoms grew slowly worse up to the time of her confinement, after which they continued to increase even more rapidly. Her labor was quite normal, and took place five weeks before her admission to the hospital. At admission her abdomen was enormously distended, the lower three-fourths were absolutely flat on percussion, and a marked sense of fluctuation was communicated to the fingers on palpation; the lower portion of the abdomen rested upon the thighs, and the friction of the opposed surfaces had caused extensive excoriation. The legs, from the feet upwards, were œdematous, and there was also some œdema of the hands and arms. The dyspnœa was so great as to render it almost impossible for her to lie down in bed; the respirations in the upright position numbered sixty per minute.

There was no evidence of any disease of the lungs or pleura. The area of cardiac dulness was increased, and a double mitral murmur, with an aortic systolic murmur, could be distinctly heard. The pulse was feeble and frequent, beating one hundred and fifteen times a minute. The urine was found to be diminished in quantity, high-colored and acid in reaction, and to contain a large quantity of albumen, the precipitate by acid and heat being equal to at least three-fourths of the bulk of the fluid tested. The microscope revealed numerous *hyaline* and *fatty* casts. Her general health was much reduced, desire for food was almost absent, and her bowels were constipated.

She was ordered half an ounce of Basham's mixture* three times daily, twenty drops of tincture of digitalis, repeated according to its action on the pulse, small doses of elaterium to relieve the constipation, and a nutritious diet, with a small quantity of whisky (f℥ij in twenty-four hours). Under this treatment the abdomen became somewhat less tense, a larger quantity of urine was passed, and the number of respiratory movements fell to thirty per minute, but the pulse remained frequent, and seemed to be unaffected by the digitalis, although its administration was pushed to the limit of safety.

---

* ℞ Liq. ammon. acetatis, f℥iij;
Tr. ferri chlor.,
Ac. acet. dest., āā f℥ii;
Curaçoæ vel syrupi q. s. ad fac. f℥vi. M.

This improvement was but temporary, and on November 20th it was decided to perform paracentesis. Six pints of a highly albuminous fluid were allowed to flow from the abdomen, when the canula was withdrawn and the aperture allowed to remain open. Two hours after the operation, the pulse, which had been beating one hundred and twenty per minute, fell to fifty, then to forty-six, and became dicrotic. The dicrotism was evidently cardiac in its origin, being produced by a second effort at systole on the part of the left ventricle. The patient was, however, in every respect better; indeed, felt quite comfortable. The effect on the heart and general condition was attributed to the digitalis, which was now, however, suspended.

November 24th, the pulse was seventy-two, somewhat irregular, though entirely free from dicrotism; the respiratory movements were reduced to twenty-six, and were much more free, while the œdema was greatly diminished. She passed, on an average, three pints of urine each day. At this date the latter was found to contain an unusual number of mucous corpuscles, some spherical epithelium from the bladder, and a *few hyaline casts;* the amount of albumen was reduced to one-sixth of the bulk of the urine tested. Since the operation a large quantity of fluid, estimated at six pints, had trickled from the orifice in the abdomen. Quinine was added to the treatment.

Nothwithstanding the continued use of diuretics (bitartrate of potash and infusion of juniper, infusion of scoparius, and free doses of digitalis), the ascites slowly increased, and on December 12th she was again tapped by Dr. Bruen, the resident physician, and one hundred and thirty ounces of fluid were removed. This was again followed by amendment, the œdema continuing to diminish. By December 22d the opening of paracentesis was closed, the *urine was free from albumen, and no casts were found after prolonged and careful examination.*

On December 24th, after exposure to cold, she became much worse, and by December 25th the legs were again swollen almost to bursting, and had assumed an erysipelatous hue. The respirations were hurried, the skin was hot and dry, and the urine was so charged with albumen that it became almost solid on the application of heat and nitric acid. Paracentesis was performed for the third time, fifty ounces of fluid being removed. No relief was experienced from this operation: in fact, the dyspnœa steadily increased, and the pulse became so feeble that it could scarcely be counted at the wrist.

At 3 P.M. on December 27th the pulse at the wrist was extinct and no cardiac impulse could be felt, but on auscultation the heart was found to

be beating one hundred and thirty-nine times a minute. Upon extending the examination to the other parts of the chest, the physical signs of pleuritic effusion were detected on the right side. At 6 P.M., as a last resort, this side of the chest was tapped, and twenty-eight ounces of liquid removed; immediately afterwards the patient felt easier, but soon began to sink, and died at 9.30 P.M.

The general plan of treatment remained the same as that already mentioned throughout the course of the illness, although, as the indications varied from time to time, the quantity of digitalis used, as well as the form of its administration, was changed: as stated, other diuretic preparations, such as acetate of potash, juniper, sweet spirit of nitre, etc., were also tried.

At the *autopsy*, which was made twenty-four hours after death, a quantity of fluid, eighteen ounces by measurement, was found in the right pleural cavity, and the upper part of the parietal and visceral portions of the pleura was covered by a moderately thick layer of fresh lymph. The right lung was congested and somewhat depressed, but not at all inflamed. There was nothing abnormal in the left lung or pleura. The heart weighed fifteen and a half ounces. The left ventricle was dilated and hypertrophied. The leaflets of the aortic valve were thickened; this alteration was most marked along the edges of the leaflets and in the corpora aurantii; the latter were increased in size, being about as large as a split pea. Both leaflets of the mitral valve were thickened, and they were fused along their edges so as to form a funnel-shaped projection into the cavity of the left ventricle, with only a slit-like opening through which the end of the thumb could scarcely be passed; the valve thus coalesced was the seat of calcareous deposit. The right ventricle was also moderately dilated and hypertrophied; the pulmonary and tricuspid valves were healthy.

The liver weighed ninety-seven ounces, and was very fatty. The kidneys were lobulated, and weighed, together, fourteen ounces: they were, therefore, somewhat enlarged, and also congested; but in other respects they appeared normal to the naked eye. On microscopical examination, the renal tubules were in part lined with healthy epithelium, or with epithelium which was only slightly granular; in other portions, however, the epithelium was highly fatty. There was also slight increase in the interstitial fibrillar tissue. No trace of amyloid degeneration could be detected by the iodine test.

Case II.—William ——, 51 years of age, was admitted to the medical wards of the Philadelphia Hospital on November 1st, 1873. He had for a long time been an attendant about the hospital, and was very intemperate. At the time of admission he was suffering from dyspnœa, œdema

of the legs, and ascites; and on examining the heart a double aortic murmur was detected. His urine, which was bloody and highly albuminous, contained casts filled with broken-down epithelial cells, granular casts, and casts containing blood-corpuscles. He died in one week: previous to this event, however, the amount of albumen and blood in the urine had greatly diminished.

The *post-mortem* examination revealed great thickening and calcareous degeneration of the leaflets of the aortic valve, while the aorta itself was extensively atheromatous. The liver was cirrhotic. The kidneys were turgid with blood, and therefore a little heavier than in health: in other respects they were normal, with the exception of a slight increase in the interstitial fibrillar tissue.

When the lesions brought to light by the *post-mortem* examinations are considered in connection with the symptoms observed during life and with the previous histories, there can be no doubt that in each of these cases cardiac disease was primary, and that the alterations in the kidneys were brought about by the disturbance of the circulation thus produced. When the mitral or aortic valves are diseased, especially when the valvular leaflets become rigid or contracted so as to allow of regurgitation, there is always a tendency for the blood to accumulate on the venous side of the heart. Under these circumstances the movement of blood through the kidneys is retarded, these organs become greatly congested, and, although it cannot be said that an inflammatory process is set up, the simple increment of pabulum in the augmented supply of blood must encourage the production of an increased amount of interstitial connective tissue. This may in time undergo contraction. At any rate, these kidneys are but little enlarged. They may remain normal in size, or may even be smaller than natural. When enlargement is present it is not usually more than can be accounted for by the large amount of blood present by engorgement. If the kidneys be smaller, this condition interferes with the entrance of arterial blood, reacting upon and causing further alteration in the heart, which in its turn produces greater structural change in the kidneys. Thus the change of action and reaction continues until the patient is carried off by the combined disease.

When the alteration in the kidneys is far advanced, the epithelial cells lining the renal tubules, being deprived of their proper amount of healthful nutriment, undergo fatty degeneration. This change, however, is rarely met with in comparison with the condition of increased connective tissue and contraction.

Further, a kidney which is constantly engorged with blood is much more liable to attacks of acute inflammation than one which is in a normal state. This fact explains the frequency with which, in cases of this nature, the urine becomes suddenly bloody and highly albuminous and filled with epithelial casts and blood-casts, even after very slight exposure, such as would produce no effect in a healthy individual. In the intervals between such attacks the blood-casts disappear entirely from the urine, and the epithelial and granular casts also become much less numerous and often disappear, the granular continuing longest. When the kidneys are so far degenerated that fatty casts appear in the urine, it is extremely rare for them to be absent at any time throughout the course of the disease. The patient whose history I detailed to you first is the only one in whom I have ever known fatty casts to disappear entirely, except in the albuminuria of pregnancy, in which it is not uncommon for all casts to disappear after labor. Another interesting feature in the same case was the more ready absorption of the digitalis after paracentesis was performed, and the prompt appearance of its physiological effect. This is to be explained on the well-known principle that osmosis is facilitated by diminished pressure. I have also observed this increased action of digitalis when venesection has been practised during the administration of the drug; quantities which had apparently no effect before the operation displaying promptly, and even in an alarming degree, their effect upon the heart.

The President said that such extreme degrees of mitral obstruction from coalescence of the leaflets of the valve comparatively rarely make their appearance in adult life. More frequently the symptoms show that the lesion dates back to an early age, and it is probable that in some cases it may arise during fœtal life. *January 8th*, 1874.

---

3. *Aneurism of the aorta.*

By Dr. J. H. Hutchinson.

The specimen is presented for Dr. Bodine, of Trenton. It was removed from a man aged 29 years, who was six feet high and weighed two hundred pounds. He died suddenly while at work in the shoe-shop of the New Jersey State Prison, where he had been for six years. He had had constitutional syphilis in a mild form. There were no symptoms

of aneurism during life, and the disease was, therefore, unsuspected. He had been engaged during a part of his imprisonment in working one of the shoe-pegging machines, an occupation which is sufficiently laborious to have had something to do with causing the aneurism.

January 22*d*, 1874.

---

4. *Congenital malformation of the heart, contraction of the pulmonary artery, deficient septum ventriculorum, with origin of the aorta from both ventricles; no cyanosis.*

By Dr. Geo. A. Rex.

The specimen was obtained from Matthew B., æt. 6 years. There was no history of any acute attacks of cardiac disease, but from an early age there had been signs of an embarrassed circulation, without any cyanosis.

Physical examination showed markedly extended impulse of the heart, with the apex-beat at the fourth rib just below the nipple; it was accompanied by a strong thrill.

On auscultation at the base, a strong systolic murmur was heard, which was transmitted to the apex, and was also heard over the pulmonary artery and along the aorta into the large arteries.

Three weeks before death, several hemorrhages from the lungs took place. General œdema set in, with effusion into the pleura, causing embarrassed respiration which lasted until death.

On *post-mortem* examination there was found considerable effusion into the pleural cavities, with little or none in the pericardial sac.

There was extreme hypertrophy of the walls of the right ventricle; while the left ventricle was small, with comparatively thin walls.

The aorta was healthy, and its valves were well formed and healthy; but it was situated immediately over the septum of the ventricles, which was imperfect, so that the aorta communicated directly with both ventricles. The cavity of the left ventricle was in great measure occupied by a firm clot, so that it evidently had taken but a small part in carrying on the circulation.

The orifice of the pulmonary artery was contracted, and its valves contracted and adherent, so that but a small slit-like orifice remained, through which the blood could pass only with difficulty. The ductus arteriosus

was closed. The valve of the foramen ovale was large enough, but was unattached at a small point, leaving a communication between the auricles as large as a goose-quill. *January 22d*, 1874.

---

5. *Specimens from Dr. Levis's case of aneurism of the subclavian artery treated by the introduction of horse-hairs.*

By Dr. Morris Longstreth.

James M., æt. 47, was admitted to the Pennsylvania Hospital with a large aneurism of the right subclavian artery. It had been recognized only three weeks previously, although he had had pain in the right chest and arm for nine months. A pulsating tumor with distinct aneurismal thrill was seen jutting above the clavicle, and below that bone another swelling was felt, in which the thrill was almost absent. Horse-hair was introduced through a fine needle canula; no difficulty was experienced in its introduction, and twenty-four feet nine inches of it were safely stowed away in the aneurism. The tumor became hard, and pulsation in it and in the radial ceased. No local irritation occurred in or about the swelling after the operation, nor any inconvenience from the arrest of the circulation.

The patient died November 16th, 1873, with symptoms of engorgement and pressure on the upper lobe of the right lung. The expectorated mucus was darkly colored with blood.

The *autopsy* was made some hours after death. There was some œdema of the axillary and pectoral regions, as well as of the right arm.

On the removal of the pectoral muscle, the whole region around into the axilla and under the scapula was fluctuating.

On opening the thorax, the upper lobe of the right lung was found solid, of a dark-red color, and pressed close up to the mediastinum. The margins of this lobe, however, were still crepitant and of their normal color.

The lower lobe was collapsed.

The right pleural cavity contained a small amount of blood-stained serum, but there were no evidences of inflammation.

The aneurism commenced in the second portion of the subclavian artery, at an inch and three-quarters from the bifurcation of the innominate. The wall of the vessel had given way upwards and downwards.

The upper dilatation was about an inch and a half in diameter, and

reached above the clavicle, partially covered by the fibres of the scalenus anticus muscle. It contained a dense white clot.

The opening on the lower wall of the vessel was oval-shaped, about an inch in its greater diameter. The margins of this opening were smooth and quite regular.

On dividing the upper lobe of the right lung, there was found a mass of black clotted blood behind it and extending beyond the line of the ribs, especially in the axillary region immediately below the clavicle, nearly two inches. In the upper portion of this soft clot a dense white clot was found attached around the lower aneurismal opening in the subclavian.

In the posterior part of the fibrinous clot were found the horse-hairs.

The lung appeared to have been pressed forward and inward by the increasing mass of blood behind it. Its vessels and the bronchial tubes had been occluded by its condensation. The lung-tissue in contact with the clotted blood resembled the condition of a lung in hydrothorax.

It was found that the first and second ribs had almost entirely disappeared; from the third to the fifth the ribs had been stripped of their periosteum; on the inner surface of the sixth rib the process of stripping was seen going on, the pleura and periosteum were slit for about an inch, and the blood had forced its way underneath them and almost surrounded the bone for this distance. The third, fourth, and fifth ribs maintained their normal position, but the blood extended through the costal interspaces, so that the clot in the thorax communicated with the fluctuating mass found beneath the pectoral muscles. Hence it will be seen that the fluctuating tumor in the axilla was covered with the dense fibrous tissues of the pleura, intercostal muscles, and costal periosteum, which had been pressed outward by the blood accumulating in the thoracic cavity. The intercostal vessels were found lacerated.

An experiment was made to determine whether or not the blood-current in the subclavian communicated with the black clot found in the thoracic cavity, but it was found that water poured into the aneurismal dilatation of the vessel was perfectly retained, none escaping into the thoracic cavity. On very careful dissection, this fact was proved, for it was found that the mass of fibrinous clot in the dilatation varied from a half-inch to two inches in thickness on the circumference.

Diligent search was made for coats of the dilated vessels, but it was impossible to trace them beyond half an inch from the margin of the opening. The cavity in the fibrinous clot was about two inches and a half in diameter, extending downward and outwards from the opening of the vessel, having the horse-hairs imbedded in its posterior walls. In the fresh

condition this cavity was filled with a recent black clot, mingled with a little white fibrin connected with the fibrinous clot in the dilatation above the clavicle, but not attached to the fibrinous wall of the lower dilatation.

The clot in the dilatation above the clavicle extended across the calibre of the vessel, and prevented the flow of blood into the axillary vessel.

It should have been mentioned that the upper lobe of the lung was attached to the thoracic wall at the level of the seventh rib from the spine around to the sternum. In the thoracic aorta, atheromatous disease was very marked; the calibre of that vessel was irregularly dilated, and in parts the coats were quite thin. The other arteries, with the exception of the innominate and right subclavian, were normal. The cords of the brachial plexus of nerves were intimately connected with the upper portions of the tumor, and were pressed against the under surface of the clavicle.

The subclavian vein was found stretched over the upper dilatation, and its calibre was so encroached upon that the return-blood was markedly obstructed.

The other organs were entirely normal.

The aneurism commenced in the second portion of the subclavian, and reached slightly into the third portion of the vessel. (This statement is made approximately, as the guiding-mark, the first rib, had disappeared.) The dilatation of the vessel was not uniform; the upper and the lower walls alone seem to have participated in the bulging.

The lower dilatation descended into the thorax, eroded the first and second ribs, and depressed the apex of the lung, becoming a *diffused* aneurism, after the manner described by Erichsen.

At the operation, therefore, it is probable that the aneurism had no true sac, but was bounded by the lung-tissue, pressed downwards from its normal position and condensed, and by the muscular tissues around the apex of the thoracic cavity.

The horse-hairs were thrust into this cavity, and their effect was good, resulting in a marked decrease of the pulsation and thrill felt below the clavicle, although there was no decrease of the pulsation in the tumor above the clavicle.

It was not until the third day after the operation that the clot began to interfere markedly with the circulation, sufficiently to interrupt the radial pulse. After this day the tumor above the clavicle began to harden, through the extension of the clot from below upwards, and this coagulum barred quite completely the passage of the blood into the axillary vessel,

but did not absolutely prevent its entrance, for it is recorded in the notes that the recumbent position slightly restored the radial pulse. Simultaneously with the hardening of the tumor above the clavicle, the return of venous blood from the arm was interfered with by pressure on the subclavian vein, which, at the *autopsy*, was found stretching over the anterior face of the upper dilatation.

Now, the formation of this clot, which only partially obstructed the vessel, and which from the position of the upper dilatation was connected with the clot in the lower opening only at its distal portion, directed the full force of the blood-current into the proximal portion of the lower opening against the new-formed clot, which, from its position, had no connection with the clot in the upper dilatation. The effect of this strong blood-current was to hollow out a new cavity in the site of the former aneurism. Inspection of the walls of the cavity shows this result very clearly, for on its walls are found a loop and two ends of hair protruding into the newly-formed cavity.

The formation of the clot in the lower sac was producing a cure of the aneurism, similar to results seen in the natural cures of sacculated aneurism, by the deposit of laminated clot in the sac, leaving a passage for the blood through the vessel behind it. If the sac had been well supported by firm tissue, and not, as was the case, been allowed to descend farther into the thoracic cavity by the receding lung, all might have been well and a cure resulted.

It has been shown that there was no communication between the sac of the aneurism and the mass of dark clot found in the thoracic cavity. Whence, then, came this blood, and what force was it that compressed the lung and stripped the ribs of their covering, and pressed out the tissues in the axilla? The first cause that acted to compress the lung and denude the ribs was the sac of the aneurism; and this pressure must certainly have caused an adhesion to take place between the two pleural surfaces, and when the new cavity was formed in the laminated clot it again began to press down in the thoracic cavity, tearing apart the lung and pleura, stripping the ribs of their covering, and compressing the lung. The process of tearing the pleura lacerated the intercostal vessels, as they were found lacerated at the *autopsy*, thus supplying a source for hemorrhage,—hemorrhage that was not likely to cease, hemorrhage that was likely to be very gradual, but still of an increasing character, as each rib and its intercostal artery suffered in succession as they were found to have suffered. No hemorrhage from a ruptured aneurismal sac or from a lacerated lung would have been so slow in its progress, nor would the force of an

increasing accumulation of blood from either of these sources have been applied in such a manner as to push outwards the periosteum of the ribs and their intercostal muscles. The force must have proceeded from the line of ribs, and worked in both directions, compressing the lung one way, and pushing the tissues of the costal wall in the other direction.

The notes of the case show that the accumulation in the thoracic cavity was very gradual, that there was no rupture of the aneurismal sac and consequent sudden depression of the circulation, and that there was no sudden laceration of the lung with its attendant copious hæmoptysis.

The symptoms show a gradual compression of the lung, and that when the upper dilatation of the vessel hardened, and the clot obstructed completely the flow of blood into the axillary artery, an increasing fulness in the axillary and subclavian region showed that the laminated clot in the aneurism was being forced downwards, and from that time a gradually increasing dulness of percussion was found posteriorly and laterally, corresponding to the position the blood occupied in the thoracic cavity.

And further, the tumor in the axilla was never a fluctuating mass during life; it was always tense, showing the great pressure the blood in the thoracic cavity was under, and the great force it was capable of exerting; after death, the axillary tumor was soft under pressure.

The stridulous breathing noted before death was undoubtedly caused by the pressure of the encroaching blood-mass narrowing the calibre of the bronchi, and possibly the trachea. *February* 12*th*, 1874.

---

6. *Atheromatous and calcareous degeneration of the aorta.*

By Dr. James H. Hutchinson.

The specimen was removed from the body of an old man, 75 years of age, who died at the Pennsylvania Hospital with symptoms indicating obstruction to the circulation. During life no murmur was heard in any part of the chest, although a physical examination was repeatedly made; the symptoms appearing to indicate valvular disease. The man had also suffered in early life from rheumatism. A calcareous plate, an inch in length, was found in the upper wall of the arch of the aorta and in other parts of the vessel; its inner coat was the seat of extensive atheromatous changes.

Occasional murmurs were absent when all the physical conditions neces-

sary for their production appeared to be present. In this case the examination of the heart was rendered difficult in consequence of the œdema of the walls of the chest, and of the existence of mucus in the bronchi, giving rise to mucous rales. *March 26th*, 1874.

---

7. *Aneurism of the arch of the aorta.*

By Dr. J. H. Hutchinson.

The patient from whom it was removed was an Irishman, æt. 53, and a coachman by occupation, who was admitted into the Pennsylvania Hospital February 27th, 1874. His history was obtained with difficulty, but it appears that three years ago he was overcome in consequence of the inhalation of irritating gases in a chemical laboratory in which he was at that time employed. After the illness which followed this, he suffered from habitual dyspnœa. Two days before his admission he had a chill, accompanied by pains in different parts of his body, and followed by swelling of the face, neck, and upper part of the chest. Although he denied it, it was discovered that he was addicted to drink; but he had never had rheumatism. When admitted, in addition to the swelling already alluded to, he presented a marked cyanotic discoloration of the face and neck. He had some dyspnœa, and an excessively feeble radial pulse. A physical examination showed dulness on the right side of the chest, continuous with the cardiac dulness, extending two inches from the sternum, and from the second to the fifth rib. In the same position a double murmur was heard; the diastolic murmur being harsher and of higher pitch than the systolic; these murmurs were so loud that they were heard all over the chest. A decided impulse could be felt, but at no time could a thrill be discovered. There was no dysphagia, no dropsy, and no albumen in the urine. The pulse at the wrist was weak, but perfectly regular, and no difference could be detected between the beats of any of the corresponding arteries of the body. The symptoms increased in severity from day to day, the congestion becoming more decided, and giving rise to a very œdematous condition of the upper part of the body, especially on the right side; the cutaneous veins of the chest were enormously dilated. Around the lower part of the thorax these dilatations presented an arborescent appearance, and completely surrounded the body, like a girdle. On the 10th of March, the day of the patient's death, the whole of the right side

of the chest anteriorly was dull on percussion, the dulness being sharply limited laterally by a line continuous with the posterior fold of the axilla. In the dull region the breath-sounds were feeble and distant, and there was an absence of vocal fremitus. Death occurred at 11 P.M., rather suddenly.

The *autopsy* was made twelve hours after death. The *rigor mortis* was well marked. There was no emaciation; the veins of the upper part of the body were enlarged. The right pleural cavity in front was filled with serum and clotted blood, which had been prevented from sinking to the lowest part of the cavity by the presence of adhesions. In the median line, above the pericardial sac and partly to its right side, was a large aneurismal sac, taking its origin apparently from the commencement of the transverse portion of the arch of the aorta, about three inches above the sigmoid valves, where the walls of the artery on the right side came to an abrupt termination, presenting an appearance very much as if they had been cut with a sharp knife. The aneurism, which appeared to have begun as a dissecting aneurism, and to have become diffused not long before the fatal termination,—probably at the time when the chill occurred,—extended from the arch of the aorta to the pericardium, resting upon the diaphragm, and partially compressing the right lung. The rupture was found in the wall of the sac on the right, near its upper part. The vena cava descendens was compressed by the aneurism.

The external coat of the aorta appeared to line the whole of the aneurism except at its lower part, where it was seen to terminate by a ragged edge. I wish to call attention to the fact that the patient, although troubled with some shortness of breath, had been able to do his work up to two weeks before his death, when the chill occurred, which was followed by the symptoms caused by pressure on the cava descendens.

The case is remarkable because the other pressure-symptoms were absent. Thus, although dyspnœa had at one time existed some time before the patient came under observation, there was no evidence that either bronchial tube was compressed. There was no dysphagia, and the pupils were of equal size, and reacted to light. The most curious feature of the case was the venous girdle, which recalled in its disposition herpes zoster, but differed from this in completely surrounding the body. It made its appearance in a single night; at least, it was absent at one visit and present at the next. *March 26th*, 1874.

8. *Aneurism of the abdominal aorta.*

By Dr. H. B. Reed, for Dr. H. B. Hare.

The specimen was derived from T. W., æt. 44, married, who was admitted to the Episcopal Hospital April 8th, 1874, suffering from severe pain in the epigastric region.

It was difficult to get a satisfactory history from him, but so far as could be learned he had enjoyed average health until the summer of 1873, during which he suffered from time to time from some abdominal uneasiness. He had been in the habit of drinking moderately, though not to excess, and attributed his slight symptoms to dyspepsia, arising possibly from this cause.

Towards the end of the summer, in attempting to move a piece of furniture, he thought he felt "something give way inside of him," and suffered slight pain, which soon wore off, leaving no great impression on his mind.

In the early autumn he found his strength failing, though, except the slight abdominal distress, no particular symptom attracted his attention, and in the month of October (1873) he was admitted to the hospital, where a diagnosis was made of cirrhosis of the liver,—a diagnosis fully borne out by the *post-mortem* appearances.

He stayed in the hospital at that time but a few days, leaving it of his own accord, and returned to his business of tailor. Gradually he became unable to attend to this, and by Christmas would have occasional paroxysms of sharp pain at the epigastrium. These increased in frequency and violence, and he noticed by the end of January that they were apparently induced or aggravated by taking food. About this time, also, but not, so far as could be learned, before, slight pain in the *lumbar* region was felt.

Gradually the pain in the epigastrium increased, until at length by March the paroxysms became at times almost unendurable, and he acquired the habit of taking large doses of opium to allay them, which it would do. His appetite, which had been fair up to this time, decreased, and he became emaciated. He had no pain of any kind except at the epigastrium, where it was paroxysmal, and in the lumbar region, where it was almost constant and dull.

On admission he was quite emaciated, sallow, and low-spirited. Examination of the epigastric region revealed a spot about an inch square, at which a thrill was perceived at the slightest touch. Under this spot, it

afterwards appeared, the left lobe of the liver was forced up against the abdominal parietes by the aneurismal sac. Elsewhere firmer pressure was needed to detect the thrill, but on auscultation a very loud blowing sound was heard, most marked at the epigastrium, but audible over the whole anterior surface of the abdomen. There was some prominence of the abdomen, and abnormal firmness at, and for a few inches below, the epigastrium. Posteriorly no thrill of any kind could be detected, but careful auscultation revealed a very faint blowing sound to the right of the spinal column and on a level with the twelfth dorsal vertebra. This sound could not be detected anywhere else posteriorly.

No change of any kind was detected until the afternoon of his death, three days after admission, when he was attacked by violent pain in the region of the heart; and while the resident physician was endeavoring to relieve this the man began to sink. He died shortly afterwards. Before his death, palpation showed that the tension of the abdominal wall over the aneurism had been removed; this occurred about three minutes before his death.

Autopsy by Dr. H. B. Reed, twelve hours after death.

The *heart* was fatty, and contained some fibrous clots. The lungs were congested, and there were pleuritic adhesions.

A broad, thin, fibrous clot hid from view all the abdominal viscera, with the exception of the liver; the left lobe of this organ was folded upon itself, and held in that position by adhesions.

After the removal of this clot the intestines were exposed to view. They occupied "in toto" the left iliac and left lumbar regions, being forced into this position by a large clot of blood which occupied the corresponding regions of the right side. This clot, caused by the rupture of the aneurism, contained the right kidney. The pelvic cavity was filled with serum. The spleen, intestines, and left kidney were, to the appearances, in a healthy state, but anæmic. The spleen was, however, much smaller than natural.

The situation of the aneurism was over the eleventh and twelfth dorsal and first lumbar vertebræ. In character it was sacculated, springing from the posterior wall of the abdominal aorta. The eleventh and twelfth dorsal and the first lumbar vertebræ were eroded by the pressure of the aneurism.

April 23*d*, 1874.

9. *Aneurism of the arch of the aorta, with enormous hypertrophy of the heart.*

By Dr. James Tyson.

The specimen was removed from a Canadian, a baker, aged about 55 years, who had been under my observation for five or six years. He was the subject of a double rasping murmur of great loudness, which could sometimes be heard at some distance from the body. There was also a very marked upheaving impulse, which influenced the entire anterior wall of the thorax. He was subject to attacks of extreme dyspnœa, in one of which he died.

At the *post-mortem* examination there was found to be no rupture, and perhaps the most striking feature in connection with it was the small size of the aneurism, which the physical signs led one to expect to be large. This involved the extreme upper portion of the arch of the aorta, but was a true sacculation of all the coats, large enough to receive a good-sized walnut, and slightly constricted at its entrance into the vessel. The aorta was atheromatous.

The extreme size of the *heart* was also striking. It weighed thirty-five ounces, and was evidently the direct cause of the upheaving impulse so marked before death. *May* 14*th*, 1874.

---

10. *Aneurism of the abdominal aorta.*

By Dr. J. C. Wilson.

J. J., æt. 24, a muscular, well-developed negro man, by occupation a waiter, was seen for the first time in the evening of April 23d. He was suffering intense abdominal pain, which he stated to be paroxysmal and to have been present only six or seven days, but not severe enough to interfere with his work until the day before I saw him. The focus of this pain was in the epigastrium; it was also referred to the lumbar region and to the left chest posteriorly. It was aggravated by lying on either side, was unaffected by cough or deep inspiration; there was slight general tenderness of the abdomen. The bowels were somewhat constipated, tongue covered with a thick whitish fur. The patient had no desire for food, and no vomiting after taking it.

No thrill or marked pulsation was observed in palpating the belly. Pulse 60, rather tense. No cardiac murmur. The patient stated that he had

occasionally had similar attacks, but that they had never before been so severe. The hypodermic use of morphia allayed his suffering. The next day he had less pain, and rose, having taken, at his own request, a bottle of the solution of citrate of magnesia, which purged him gently.

On the morning of April 25th, after a night of great suffering, he sank suddenly and died.

The diagnosis had not been made out. After his death, it was ascertained from his friends that he had suffered for some months pain in his belly, but had never given up work on account of it. He often spoke of having strained himself in lifting, and associated the pain with that fact. He had had malaria, and had, some few years ago, venereal sores, followed by a single suppurating bubo. There was no history of constitutional syphilis. *Sectio cadaveris* revealed at once the cause of death. The peritoneal cavity was filled with fresh blood-clots. This blood had escaped from a longitudinal rent in the wall of a sacculated aneurism of the abdominal aorta, situated opposite the lower dorsal and upper lumbar vertebræ, and between the crura of the diaphragm. The opening in the wall of the artery was about one inch and a quarter in length, and was opposite the twelfth dorsal vertebra; the tumor itself was three inches and three-fourths long and two inches wide, and was developed anteriorly and upward, so that a portion of the right pleura was adherent to its upper extremity. Its long diameter corresponded with the course of the aorta, and its middle point was opposite the eleventh dorsal vertebra. The trunk of the cardiac artery and the superior mesenteric were given off from the sac, which in its upper part was occupied by a moderately firm clot the size of a hen's egg. The heart was hypertrophied; there was some bloody serum in both pleural cavities. The remaining viscera were blanched from loss of blood, but otherwise healthy. As the aneurism was developed anteriorly, there was no erosion of the bodies of the vertebræ. Some old inflammatory adhesions existed between the peritoneal covering of the tumor and that of the stomach. No atheromatous patches were to be seen upon the thoracic aorta; the valves of the heart were normal. There were, however, to be observed near the seat of the aneurism small, faintly-marked patches, showing slight local change in the middle coat and in the deep layers of the inner coat of the aorta,—probably commencing atheroma.

It may be not without interest to the members of the Society to state that this specimen has been kept since April 25th in a solution of hydrate of chloral, gr. xii and f℥i, as recommended by Dr. Keen. The preservation is in every way most excellent as to texture, color, and the absence of any trace of the odor of decomposition. *May 14th*, 1874.

11. *Extensive atheroma of the circle of Willis and cerebral arteries.*

By Dr. Wharton Sinkler.

The patient from whom the specimen was removed was a man 47 years of age, single, who for some years had been employed in the post-office as letter-carrier and clerk. For twelve years he had served in the British army in India, and during the late war he was in the United States army. He had always enjoyed good health, and was temperate in the use of tobacco and liquor. He had never suffered from any constitutional malady.

There was no cardiac disease, nor were there any atheromatous changes in the radials.

About three years ago he had an attack of left hemiplegia. The paralysis was not absolutely complete, he being able to move slightly the hand and foot, and in about six months was able to return to light work. He could walk fairly well at the end of this time, could use the arm to some extent, and there was no contraction of the flexors on the paralyzed side.

For several months he continued to improve. Once, however, he had an attack of vertigo, which was followed by an increase of weakness for a few days.

Rather more than a year after the first attack he had a second. He did not become unconscious, but he was extremely difficult to rouse. The face was flushed, the breathing stertorous, and the speech thick. He complained of intense pain in the head. The loss of power was on the right side, but it was not so complete as it had been on the left side in the previous attack. There was no facial palsy. It was two or three months before the patient was able to walk even a few steps. The muscular power of the limbs seemed to have returned, but the difficulty was in co-ordination. The power of locomotion in time returned to some extent, but he was never able to walk any distance, even with assistance. His gait was uncertain, and if his attention was called to anything while he was walking he was apt to fall. In fact, there was a sort of choreic condition of the limbs which was induced when voluntary effort was made, and unless he carefully observed his movements he tottered or fell.

During the next few months he had several attacks of vertigo, followed by severe pain in the head, loss of appetite, and obstinate constipation. After these attacks there was always increased difficulty in walking. For several months before death the expulsive power of the bladder became weakened, and urination was often delayed many hours.

On May 7th, 1874, while sitting on the commode and endeavoring to

urinate, he suddenly fell forward unconscious. He was caught, however, before striking the floor. There was no convulsive movement, but the body became rigid and the eyes were rolled up. Consciousness returned in a few minutes, but on recovering he felt as if he were choking. He could not swallow, and respiration was labored. Speech was thick and almost inarticulate. For a few days before this he had been unusually heavy and inclined to sleep most of the time. In a few hours he was able to take into the stomach some liquids; but the next day the inability to swallow returned, and the respirations became more frequent and difficult. The bladder was emptied by the catheter, and the urine examined and found to be free from albumen.

His condition from this time grew steadily worse. The surface became congested from insufficient aeration of the blood, everything that was attempted to be swallowed was regurgitated through the nose and mouth, and the patient died on May 12th.

There was no increase of paralysis in the extremities, and consciousness remained almost to the last.

Post-mortem, forty-eight hours after death.—The body was in a good state of preservation, having been kept in ice. The veins of the scalp were full. The skull was brittle, a corner breaking off when the calvarium accidentally dropped on the floor. Dura mater not unusually congested. In the superior longitudinal sinus was a firm white clot extending almost its entire length. Its arachnoid was opaque over its convexity, but was more especially so at the base. A white clot occupied the right internal carotid. The vessels of the circle of Willis were enlarged and extensively atheromatous. The right middle cerebral artery was almost double the normal size, and stiffened with atheromatous changes; the left was in very much the same condition, and in the under surface of the middle lobe, where the vessel rested, was a spot of softening the size of a pigeon's egg. On section of the brain, the puncta vasculosa were prominent and some serum exuded. There was a moderate amount of fluid in the ventricles. In the left corpus striatum was a patch of softening as large as a filbert. No change in the right. In the right crus cerebri was a small spot of softening, which presented a dark color with many almost black points. A fragment of this was kindly examined by Dr. Tyson, who found only pigmented cells and no hæmatoidin crystals. There were adhesions and recent lymph in the right pleura, and the base of the right lung was somewhat congested. The liver and kidneys were gorged with blood, but otherwise healthy.

May 14th, 1874.

12. *Hypertrophy of the heart; pericarditis, with enormous thickening of the pericardium.*

By Dr. Wharton Sinkler.

The specimen is from A. B., admitted to the Episcopal Hospital July 8th, 1874. He complained of pain in the back and around the base of the chest. There was no tenderness over the liver, but the area of hepatic dulness was lessened. There were anorexia, nausea, and at times diarrhœa. The emaciation was extreme, but there was no dropsy. Patient acknowledged to having been a hard drinker of undiluted spirits. There was no cardiac murmur detected, and the heart's impulse did not appear to be increased. A diagnosis of cirrhosis of the liver was made. He gradually lost strength, and a few days before death the gastric derangement increased and there was some diarrhœa.

On August 26th he was confined to his bed, and complained of weakness. On the 28th he was delirious, stupid, and disposed to sleep. He refused all food except small quantities of punch. The symptoms increased in severity, and death supervened on September 4th, the patient having been comatose for forty-eight hours previous.

The *post-mortem* was made five hours after death. The lungs were firmly attached to the walls of the thorax by old adhesions, and there were scattered tubercles throughout both. The kidneys were large, but appeared healthy. The heart was hypertrophied. The pericardium was attached to the lungs. Both layers of pericardium were greatly thickened, and presented the appearance of fatty degeneration. Binding these layers strongly together was a thick deposit resembling a partially organized clot, of a reddish color and of firm consistence. The thickness of the pericardium, including the deposit of new tissue, was five-eighths of an inch. The left ventricle was three-fourths of an inch, and the right one-half inch thick. The length of the heart was seven inches, and its greatest circumference ten and a half inches. The liver was somewhat contracted, and was a well-marked specimen of cirrhosis. *September* 10*th*, 1874.

Report of the Committee on Morbid Growths:

"The thick pericardial covering upon the heart, presented by Dr. Sinkler, is composed of laminæ of corpuscular elements (leucocytes) enclosed in the meshes of the interlacing, delicate fibres of organized fibrin. This covering is therefore to be regarded as an inflammatory product."

September 24*th*, 1874.

13. *Patulous foramen ovale, and thickened and attached pericardium.*

By Dr. Wharton Sinkler.

The specimen was obtained from Mrs. L., æt. 60, who was admitted to the medical wards of the Episcopal Hospital February 18th, 1874. She was suffering from dyspnœa, anasarca, and showed a constant disposition to sleep. The circulation was sluggish, and a general venous turgescence existed. The urine contained albumen. The patient died July 28th. At the *autopsy* the kidneys exhibited the characters of the contracted granular kidney. The lungs were healthy. The pericardium was firmly attached to the heart throughout, and was thickened. There was a communication between the auricles through a patulous foramen ovale. The opening was valvular, and it is not likely that during life there was any passage of blood from one auricle. *September* 10*th*, 1874.

---

14. *Extensive disease of mitral valves; auricular vegetations.*

By Dr. Wharton Sinkler.

Maggie L., æt. 16, was admitted to the Episcopal Hospital January 13th, 1874. She had suffered from a severe attack of acute articular rheumatism, and on admission had violent dyspnœa on the slightest exertion. There was a dry cough. The heart was hypertrophied, and an unusually loud murmur was heard all over the præcordia, with the systole and diastole. The murmur was loudest at the apex, and was heard with distinctness at the inferior angle of the scapula. It diminished in intensity towards the sternum.

On August 24th she had another attack of articular rheumatism, and complained of pain in the præcordia. Death occurred on the 30th.

On *post-mortem* the left lung was found bound down by old adhesions, and there was a tubercular deposit at the apex. The pericardial sac was obliterated by a recent formation of lymph. The tricuspid valves were partially adherent. The leaflets of the mitral valve were thickly covered with vegetations of a calcareous nature, and extending into the left auricle were extensive villous vegetations, the lower half of the anterior surface of the endocardium being covered by the vegetations. Aortic valves healthy. *September* 10*th*, 1874.

15. *A case of rupture of the heart, and post-mortem muscular spasms.*

By Dr. W. W. Keen.

The specimen was obtained from Mrs. S., æt. 68, who had been in general poor health for some years, and a year ago had been cautioned as to exertion on account of a fatty heart.

September 16th, 1874, in the morning not feeling very well, and her hands and feet being cold, as her daughter noticed, she did not rise till near noon. Up to this time she had had two or three attacks of vomiting and retching, not more than usually severe, and apparently caused by taking some medicine, as it followed each dose. At 1 o'clock P.M., having been about the room for some time, she said she felt rather worse and would lie down. In a few moments she sat up in bed, retched again, suddenly threw herself back without a word, and was dead. I was hastily called (I had never seen her before), and after listening over the heart and lungs, feeling for the pulse, finding the pupils immobile, and noting the color and coldness of hands, feet, and face, I pronounced her dead. This was some ten or fifteen minutes after death. About half an hour after death, on going into the room, I noticed with surprise that one of the feet seemed to move under the sheet. To assure myself that it was not possibly the shaking of the floor, I uncovered the feet and hands and sat by the body to watch. The movements were not constant, but were very frequent, probably from two to three times a minute at first to once in three to five minutes towards the end, and they did not cease for over an hour and a half after death. There were sometimes spasmodic movements of the whole foot, but by far the most frequent nearly complete flexion of the great toe alone, or of the first two or three toes, or of all of them together. No other part of the body moved. The movements were so marked that I made one or two subsequent examinations to assure myself of the extinction of life.

The examination after death was a very satisfactory proof that they were purely *post-mortem* phenomena.

Sectio cadaveris, forty-eight hours after death.—The *rigor mortis* was well marked. The subcutaneous fat about one inch thick. The heart only was examined. About eight or ten ounces of clotted blood and serum were taken out of the pericardium. On removing the heart, the valves were competent, as was proved by testing them with water. The aorta and the mitral valves showed the beginning of atheroma, but only slight. The cause of death was found in a rupture in the walls of the

left ventricle. The external orifices were mere slits three-sixteenths and one-eighth of an inch long respectively, one-fourth inch apart, one-half inch from the septum ventriculorum anteriorly, and two inches from the apex, respectively. Internally, there was but a single opening, hidden completely by the columnæ carneæ, as shown by two probes passed from the exterior. The walls of the right and left ventricles were three-sixteenths and five-eighths of an inch thick, were not fatty to the eye, and were not at all torn or undermined in any way by the rupture. The heart contained no clots, save one, quite small, entangled in the columnæ carneæ at the internal opening, and composed of two parts, one-half of white fibrin, the other half of more recently coagulated blood. On microscopical examination, the muscular tissue was found very fatty, the striation being plainly visible, however, at most points, but the fibres everywhere broke up longitudinally into fibrils on the slightest violence. The specimen is in the Museum of the College of Physicians.

September 23d, 1874.

---

16. *Acute pericarditis: hypertrophy of heart from previous disease.*

By Dr. Wm. Pepper.

James —, æt. 9; was admitted to the Children's Hospital on September 21st. Only very imperfect information of his past history could be obtained. It was stated that he had had symptoms of rheumatism two weeks previously, and that on former occasions he had had attacks of that disease. No symptoms of heart-trouble had been noticed. On admission, there was no swelling or tenderness of any of the joints. There were orthopnœa, great præcordial distress, complete anorexia, and marked general prostration. The pulse was small, quick, and irregular, averaging from 140 to 160 per minute. There was slight præcordial bulging; the area of cardiac dulness was greatly extended, reaching from third rib down to line of apex in sixth interspace, and extending from right margin of sternum to left of line of left nipple. This was evidently due to hypertrophy of the left ventricle, as the impulse was heaving and extruded and reached as far as the lowest limit of dulness. A thrill was felt near left border of sternum. On auscultation, a strong systolic mitral murmur was detected, together with very marked churning and rubbing friction-sounds, whose seat of greatest intensity was along left border of sternum.

He was treated with small doses of calomel (gr. $\frac{1}{4}$ to gr. $\frac{1}{2}$) frequently

repeated and pushed to mild salivation; tr. digitalis, gtt. v every four hours; blisters to præcordia, absolute rest, nutritious fluid diet, and f℥i brandy four times a day. He improved quite rapidly, and in the course of ten or eleven days was able to sit up in a chair, with quite easy breathing, pulse of 85 to 90, fair appetite, no præcordial pain, and diminishing murmur and friction-sounds. Unfortunately, owing to a sudden change in the weather, or to imprudent exposure, he contracted pleuro-pneumonia of the left side on the twelfth day, and died in forty-eight hours.

At the *autopsy*, a moderate amount of pleuritic effusion was found on left side, with consolidation of lower lobe of left lung. The pericardial sac was greatly enlarged: on being opened, it was found to contain four fluidounces of blood-stained effusion. There were signs of intense pericarditis; around the apex and for a distance of one and a half inches up the body of the heart, the two serous layers were matted together by grayish glutinous lymph. The rest of the serous membrane was coated with false membrane, for the most part not very thick, and with reticulated arrangement. Corresponding to seat of most intense friction-sound were two large patches (one on each layer of the pericardium) of firm lymph, arranged in parallel transverse ridges. The *heart* was greatly hypertrophied, weighing, with the pericardium attached, over eighteen ounces. There was marked thickening of walls of left ventricle, with considerable dilatation of cavity. The mitral valves were thickened, and their edges fringed with small vegetations. The aortic valves were competent, but were slightly thickened, and had a row of small vegetations on their ventricular surface, near the free border of the leaflets.

October 8th, 1874.

---

17. *Aneurismal perforation of the trachea.*

By Dr. R. M. Bertolet.

Annie S., æt. 34, was admitted to the Philadelphia Hospital but a short time before her death. She was suffering with chronic bronchitis; had a dry hacking cough; slight expectoration, at times tinged with blood; voice very hoarse, often completely aphonic. No radial pulse could be detected in left wrist. Upon September 10th the resident physician, upon his visit, found her sitting in a chair, complaining of feeling a little indisposed. Shortly afterwards, she suddenly fell to the floor, and was expiring by the time the physician—still in the ward—reached her. Spasmodic

respiratory efforts were made at long intervals, with blood flowing from her mouth and nostrils. She was dead in less than two minutes.

Autopsy had to be limited to the thorax. Internal surface of the manubrium of the sternum is slightly eroded by the pressure of the aneurismal sac. Lungs are apparently healthy; smaller bronchi filled with clotted blood; valves of the heart competent. The aorta is atheromatous. An aneurismal sac, about the size of a hen's egg, filled with laminated coagula, arising from the transverse arch of the aorta, and partially involving the innominate branch, has greatly compressed and flattened out the anterior wall of the trachea, one inch above the bifurcation. Several of the cartilaginous rings are eroded at this point, and the underlying mucous membrane is perforated. A large clot, extending into the bronchi, is found adherent to the margins of the ulcerations. The tracheal and bronchial mucous membranes are highly inflamed and thickened. A secondary dissecting aneurismal tumor, of nearly the same size as the first, has formed upon the ascending portion of the aorta, and is likewise filled with a clot. The right recurrent laryngeal nerve is firmly adherent to the aneurismal tumor. Most probably its compression was attended with paresis of the right vocal cord, thus accounting for the troubles in phonation. Unfortunately, no laryngoscopic examination was made.

Dr. H. Allen said that the specimen was one of a very interesting class. He alluded to a case reported by Mr. Fullerton, in which an aneurism of the arch of the aorta passing up between the trachea and œsophagus actually ulcerated into both. Hæmatemesis and hæmoptysis had occurred during life. *October 8th*, 1874.

---

18. *Aneurism of the aorta, with supposed rupture of the heart.*

By Dr. John Guiteras.

As the nature of the case was not suspected during life, the history I have been able to obtain from the attending surgeon, and the notes on the *autopsy*, are necessarily very imperfect.

H. M., æt. 40, admitted into the medical wards of Blockley Hospital on the 4th of November, 1874. No careful examination was made of his condition; and, as he had a sore on his face, he was transferred the next day to the surgical ward. Here he was treated for syphilitic necrosis of the nasal bones. Besides this, he rather frequently called for relief in attacks of bronchitis, which soon yielded to treatment, and never made

necessary a physical examination. Nevertheless, the man was weak, and indisposed to move. He was short of breath, and kept a good deal to his bed. To get a good night's sleep he required anodynes, and preferred to lie with the shoulders elevated.

On the 13th of January he felt better than usual, and did not take his evening dose of morphia. At 11 o'clock the night-nurse heard him blowing as if to spit up something. A few minutes after, the doctor found him tossing about in the bed, and gasping for breath. He was able to utter short, interrupted sentences. The skin was purple, cold, and clammy. No pulse could be felt, except, perhaps, at the carotids. Though the movements of the patient prevented all attempts at auscultation, the condition was diagnosed as one of heart-failure, and was treated accordingly. At 1 o'clock A.M. he died in a condition of syncope. The urine removed before death was not albuminous.

Autopsy.—The cartilage-knife was made use of to cut the costal cartilages over the heart. In removing the sternum, a piece of the pericardium, about two inches in diameter, was shaved off; a considerable amount of blood ran out, and a clot was seen bulging through the opening. This clot filled up the pericardial sac, was half an inch thick, measured six by five inches, and weighed eight and a quarter ounces. It was recent, as shown by its dark color and jelly-like consistency. On removing it, a small projection from it appeared to be entangled in the cardiac walls. On grasping the vessels at the root of the neck, blood was seen to well out of a small slit in the anterior wall of the left ventricle. When the thoracic viscera were removed, it was found that the arch of the aorta was dilated into a large aneurism, the upper wall of which was left in the body.

I saw the specimen a few days after its removal, and was led to doubt the existence of cardiac rupture. Examining it carefully, I find that the heart is enlarged. The deposit of fat around it is abundant, especially about the right ventricle. Less than one inch from its origin, a large dilatation of the aorta begins, and extends somewhat beyond the origin of the left subclavian. It might hold a large orange. Its outer surface is very ragged; the inner surface is covered with irregular layers of fibrin, which have broken down in some places, leaving the sac-walls very thin. On its anterior wall, in the ascending portion of the arch, there is a place where the thrombus is deeply excavated, and at the bottom of this excavation the adventitia seems to have been perforated. On filling this portion with water, the liquid leaks, drop by drop, through the opening.

The left ventricle is moderately dilated and hypertrophied, its walls measuring half an inch. The right ventricle is not dilated, and its walls

measure from one-sixth to one-eighth of an inch. Just to the left of the interventricular septum, and one and a half inches from the apex, the slit is found. It is directed downwards and outwards, and measures less than half an inch. Its edges are perfectly smooth, very much resembling an incision. The upper end runs straight into the cavity, whilst the lower end runs slanting to meet the upper one; thus leaving a very small opening on the endocardial surface, so small that it was only detected by pushing a director from the outside.

The valves are slightly thickened, but the endocardium in the cavities and at the seat of puncture is perfectly healthy. There is no lesion of the cardiac walls about the opening. The muscular fibres present the usual slight fatty degeneration common to all cases of hypertrophy with dilatation.

In regard to the slight attachment of a portion of the clot to the viscus, it must be remembered that it did not lead to the discovery of the opening, but it was brought to mind after the slit had been found.

The following reasons seem to disprove the existence of rupture of the heart:

1. The presence of an aneurism of the arch of the aorta, a lesion which is so apt to terminate by rupture into the pericardium. The walls of the sac are very poorly organized, and at one spot an opening seems to have occurred during life.

2. The pericardium, endocardium, and the muscle itself present no acute or chronic lesion that could have caused a rupture. The deposit of fat around the heart is not more than what I have seen in a good many cases.

3. The features of the slit. It is a perfectly clean cut. The upper end leads perpendicularly down into the cavity of the ventricle, whilst the lower end slopes gradually almost to meet the upper one; thus representing the shape of the blade of a knife. Experimentally, I used the knife in cutting the costal cartilages of another subject, without being careful to avoid the heart, and I produced a slit similar in every respect to the one in our specimen.

4. I also think that I found the trace of the knife in the clot; but this had been handled a good deal.

The perforation was rendered particularly easy in this case by the clot of blood distending the pericardium, and by the layer of fat covering the anterior surface of the viscus; both circumstances tending to diminish the resiliency of the structures to the knife.

Dr. James Tyson said he had seen the specimen immediately after its removal from the body of the patient. At that time a probe had been introduced through the opening of supposed rupture, but he was at once

impressed with the resemblance of the orifice to that produced by a knife, such as often occurs when opening the chest rapidly. He was informed, on remarking upon this resemblance, that the orifice, when discovered, was covered by a huge clot of blood which appeared to render such an origin impossible. Dr. T. had no doubt that the orifice was produced by the knife at the *post-mortem* examination, and that the clot was probably due to a rupture of the aneurismal sac. *February* 11*th*, 1875.

---

19. *Dilated heart; pleuritic effusion in a patient who had yellow fever two years previous to death.*

By Dr. John H. Packard.

Mr. R., æt. 63, first came under my care in October, 1874, on account of asthmatic trouble, with rapid, enfeebled, and irregular action of the heart. He had never been in perfectly good health since an attack of yellow fever, according to his statement a very severe one, which he had had, some two or three years ago, when in Mobile. Some years before that he had had some form of ophthalmia, by which, or, in his opinion, by the severe treatment adopted, the sight of both his eyes had been totally lost.

The symptoms above mentioned were in a great degree relieved by the use of tonics and digitalis; but in February they recurred, and proved less amenable to treatment. On the 1st of March he was attacked with congestion of the lungs and hæmoptysis. The right lung was more seriously affected than the left. This congestion passed off entirely within a week, but the marked debility which had attended it remained, and steadily increased until his death, March 31st.

During the continuance of this congestion, and to some degree after it had subsided, there was dulness on percussion over the right back, and the liver could be plainly felt extending below the ribs, its surface being nodulated. The urine was albuminous, but not highly so. A week or more before his death, an anasarcous condition of the legs, which had been gradually increasing, suddenly became very marked; and during the last three days of his life gangrene began in the columna and tip of the nose.

An *autopsy* was made thirty hours after death, by Dr. John M. Keating. Body in ice; *rigor mortis* scarcely perceptible.

In opening the thorax, the cartilages of the ribs were found very firmly

ossified, so that they had to be sawn through. A large effusion of serum existed in the right pleura, perfectly limpid except in the neighborhood of an old adhesion posteriorly, where there was a long ragged flake of lymph. The lung was somewhat emphysematous above and in front, but below and posteriorly there was a focus of very marked congestion, a portion of the tissue sinking in water. In the left lung the same appearances existed, except that the congestion was less marked and seemed to be merely hypostatic. There was no effusion in the left pleura.

The heart was very largely dilated, its tissue far advanced in fatty degeneration, its valves all healthy, as were also the large vessels. The auricles and ventricles were full of blood, liquid in the right cavities, softly clotted in the left.

In the abdomen there was found a good deal of fat in the subperitoneal areolar tissue, extending along the suspensory ligament of the liver, which organ was roughened or finely nodulated on the surface, and seemed to be fatty. A curious arrangement of the gall-bladder was noticed; it was very long, full of fluid bile, and curled up around the anterior edge of the liver, so as to have its fundus directed towards the diaphragm.

The omentum was strongly adherent to the underlying viscera, and numerous adhesions and slight deposits of lymph existed between the coils of intestine. Nothing abnormal was noticed in the condition of the alimentary canal. The pancreas was somewhat bulky, but not perceptibly diseased.

The spleen was rather a small one, very firm, and of a dark plum-color on section.

The kidneys were not enlarged, perhaps somewhat contracted; their surfaces were lobulated, and the section seemed to the naked eye to indicate cirrhosis.

Portions of the spleen, liver, and kidneys were submitted to Dr. R. M. Bertolet for microscopical examination.

The question as to the agency of the attack of yellow fever in inducing the pathological changes above recorded is one upon which those more accustomed to the study of purely medical disorders may be able to pronounce a ready judgment; to my own mind, the history the patient was able to give to me seemed too vague and incomplete to permit me to do so.

The chain of morbid conditions leading to death in this case seemed to be as follows: the dilated and fatty heart was of inadequate power to drive the blood against the disadvantage of imperfect aeration in the emphysematous lung; upon the occurrence of congestion of the lung from a casual chilling of the cutaneous surface, the sluggish circulation aggravated

it, and gave rise to dropsical effusion into the right pleural cavity, this being the side on which, from the position of his bed, he habitually lay; this condition mechanically hampered the action of the lung, and further embarrassed the weak heart, promoting the occurrence of slight ascites and anasarca; all these circumstances, with the imperfectly performed functions of the liver and kidneys, constituting a total of depression under which the muscular tissues of the heart failed altogether.

Dr. R. M. Bertolet had made an examination of a small section of the heart, and found in a marked degree the fatty degeneration of its muscular structure. The cirrhosis of the liver and kidney had not yet reached the latter stages, but was present, as evidenced by a hypertrophy of the connective tissue about the blood-vessels, the Malpighian capsules, and the membrane of the tubules.

Dr. Pepper said the extent to which the liver and even the kidneys are implicated in yellow fever makes the condition of these organs, in cases where recovery has taken place, an interesting one. He thought that the characters of the disease were such that they need not lead necessarily to cirrhosis of these organs; while the frequent existence of emphysema of the lungs, fatty degeneration of the heart, and cirrhosis of the kidneys in cases where no yellow fever is previously present makes the question a very obscure one. He asked Dr. Bertolet whether he was aware of any facts bearing on the question of the liability of the kidneys and liver to organic disease subsequent to recovery from yellow fever.

Dr. Bertolet replied that he had never had the opportunity of making a *post-mortem* examination in a case of yellow fever, and, although much had been written upon the subject, he felt that the pathology of the disease was still ill determined. He thought the condition of the liver and kidneys ordinarily met with in yellow fever by no means necessitated, and it was doubtful if they even favored, the development of cirrhosis in these organs. Fatty infiltration of a glandular tissue did not necessarily imply its destruction, nor is the atrophic liver always a resultant of a sclerotic process or so-called cirrhosis. Should we admit the occurrence of cirrhosis as a sequel of yellow fever, we must first carefully exclude all other causes of the same state, as alcohol, intermittent and other fevers, before we could be certain it was produced by yellow fever. *April 8th*, 1875.

20. *Aneurism of the innominate artery; obstruction in the larynx: tracheotomy.*

By Dr. John Guitéras.

I owe to the kindness of Dr. Ludlow the opportunity of presenting to the Society this specimen of aneurism of the innominate artery; the case having been under his care in the Philadelphia Hospital.

John M., æt. 35, moderately intemperate and of a healthy family, was admitted in February of 1874, complaining of marked dyspeptic symptoms, some dyspnœa, and a severe dry cough, which could not be accounted for, as there were no abnormal pulmonary physical signs.

Treatment by expectorants, by general and stomachic tonics, failed to relieve him, and he was discharged suspected of being an impostor.

In November of 1874 he was readmitted with the new symptom of constant dyspnœa, frequently aggravated by paroxysms. He had more or less constantly in the trachea the sensation of a foreign body, which he tried to cough up, expectorating nothing but a little tenacious mucus. Both the inspiration and expiration were labored, and during the paroxysms attended with crowing and rattling sounds. The voice was not hoarse, but his speech would often terminate in a labored whisper, as if there was not enough air passing to throw the vocal cords into vibration. His hands and face were always purplish. A laryngoscopic examination revealed slight thickening of the ary-epiglottic folds. During the last days the expectoration became looser and tinged with blood.

The presence of an intra-thoracic tumor was evident, and at one time Dr. Ludlow, after quieting the circulation and respiration of the patient, was enabled to detect a very soft, feeble murmur at the upper portion of the sternum. He diagnosed an aneurism, and with this view he undertook the treatment of the case.

Since that time I often examined the case carefully, and never found any pulsation or thrill in the chest, or at the root of the neck. No murmur was present, nor abnormal percussion-sound. The pupils and radial pulses were alike. There were no evidences of pressure except upon the trachea. Nothing pointed to disease of the arterial coats except a very doubtful syphilitic history.

Frequent doses of Hoffmann's anodyne gave temporary relief. The iodide of potassium, the cardiac sedatives, leeches to the base of the neck, blisters over the larynx, were made use of.

The paroxysms continued until, on the morning of the 16th of April,

it became apparent that death was inevitable if immediate relief was not afforded. The resident physician, Dr. McDonald, having previously obtained the consent of Dr. Ludlow to operate in case of emergency, and believing that at the time much of the obstruction was seated in the larynx, performed the operation of tracheotomy, after consulting with the rest of the resident staff. The operation was almost bloodless, and was followed by marked relief. The tube escaped several times, and a larger one was ordered. In the different attempts to replace them it was found that a good deal of bloody mucus was filling the trachea. In the evening the patient died, choked, I believe, by the increasing hemorrhage.

Autopsy, twelve hours after death.—The left pleural cavity contained about two pints of serum, and the upper lobe presented chronic adhesions, so that the lung, itself in a state of splenization, was much torn when removed. The right lung was not adherent, but emphysematous and congested. The bronchi, especially of the left lung, contained a good deal of blood.

The *aorta*, closely adherent to the trachea, together with the heart, constitute the specimen presented before the Society.

The heart-walls are flabby and rather light in color. The cavities and valves are normal, the mitral only presenting a slight thickening in the anterior leaflet.

The ascending portion of the arch of the aorta is slightly dilated and atheromatous. The innominate is uniformly dilated, and presents, almost at the origin of the inner wall, a small opening, leading into a sacculated aneurism. The tumor is of the size of a small egg, and rises to one inch below the thyroid body. Its thickened walls are closely connected with the innominate and with the trachea. The lumen is filled with a soft clot, and the walls are lined with a thick thrombus distinctly stratified, but not very closely adherent to them.

The mucous membrane of the larynx was somewhat œdematous and thickened. One inch and a half above the bifurcation of the bronchi, and on the anterior aspect of the trachea, the mucous membrane presented an opening large enough to admit a probe. It led directly into the aneurism, and presented elevated edges. The aperture towards the sac was obscured by the thrombus. There was hardly any obstruction of the trachea apparent.

The incision involves four of the tracheal rings, extending from the thyroid body above almost to the walls of the aneurism below.

The character of the opening and the condition of the lung indicate to me that the aneurism had been leaking for a day or two before death.

April 22d, 1875.

21. *Aneurism of abdominal aorta.*

By Dr. James Graham.

H. S., æt. 26 years, married, was a strong, well-made man, a stoker at the gas-works, whom, some four years ago, I attended for chancre and bubo. Since then he married, and has had three children, all of whom suffered from syphilis.

On the 8th of this month he consulted me in relation to a pain shooting around from the lumbar region to the groin, on the right side, with which he had been troubled for upwards of a month; it was irregularly intermittent, sharp, shooting in character, severe enough to prevent him from working, yet he had not applied for any medical treatment. Six weeks before he had returned from a trip to Antwerp, having worked his passage over as a sailor, and back as a stoker.

As he lived in a malarious section of the city, I put him on quinine, and ordered him to report at my office in a few days; but on the following day I was called in great haste, and found him pale, remarkably cool and clammy over the entire body, with feeble pulse and violent pain in the præcordial region (severer, he said, than anything he had ever suffered in his life before), shooting to the left shoulder and down to the elbow; also great burning in his stomach. It had come on suddenly while at stool, at nine o'clock in the morning. Stimulants were given freely, heat and mustard-poultices applied externally, and the pillows removed from under his head. He rallied a little, and was more comfortable up to six o'clock in the evening, when the pain again increased in violence; he had to be supported in the semi-erect posture, and he continued in great agony until his death, at three o'clock the next morning.

Post-mortem examination, fifty-eight hours after death.—*Rigor mortis* well marked. In the thorax nothing abnormal was found, but on opening the abdomen an immense clot of blood was discovered, hiding all the viscera, and reaching from the diaphragm into the pelvis. All the organs were normal, except the kidneys, which were somewhat enlarged. The cause of the hemorrhage was found to be a ruptured aneurism, the size of an orange, connected with the front part of the abdominal aorta, just above the origin of the cœliac axis: it was injured in exposing it, so that the size of the rent could not be determined. The great omentum was distended with blood, and hung down like a bag in front of the intestines. It was uninjured, and we concluded that after the blood had broken into and filled the cavity of the great omentum, it had flowed through the

foramen of Winslow into the general peritoneal cavity so slowly as to prolong life for a number of hours.

April 22*d*, 1875.

---

22. *Aneurism of the abdominal aorta.*

By Dr. W. G. Porter.

The specimen was obtained at a *post-mortem* which I made for a fellow-practitioner about three weeks ago. The history was as follows:

He was called to see the patient, a man about 57 years of age, about a week before his death, and found him suffering from tympanitic distention, colicky pains, constipation, and vomiting. Under treatment the vomiting and constipation were relieved, but the tympany, though somewhat modified by treatment, still remained, and the patient, who was an old drunkard, sank, and died exhausted.

Post-mortem.—The whole aorta from the heart downwards was the seat of extensive atheromatous change, the artery feeling more like an egg-shell than anything else. Just below the diaphragm a large aneurism was found, almost filled with laminated fibrin; it had eroded three of the vertebræ, and, rupturing on its posterior aspect, had formed a large false aneurism, and had filled the whole of the left side of the pelvis.

May 13*th*, 1875.

---

23. *Punctured wound of chest-wall, with incised wound of aorta.*

By Dr. Edw. L. Parks.

F. R. was stabbed in the back with a long, pointed knife. He fell upon the floor, blood poured plentifully from the wound, and in a very short time, probably not more than three minutes, he was dead. There is no history of a stab elsewhere, though another was found after death.

The notes of the examination are,—

Post-mortem discoloration on the posterior portion of the body. A wound was seen two inches above the inferior angle of the left scapula, and two and a half inches from the median line. This wound was three-fourths of an inch in length, and ran obliquely downwards and outwards. On removing the flap of skin covering this part of the body, a large coagulum was observed lying between the skin and underlying tissues. The

wound in this position was one inch long, and one-half inch from the spine, and penetrated the chest between the seventh and eighth ribs. The lower border of the seventh rib was sharp, caused by contact of the wounding instrument. On the anterior left aspect of the body, about six inches above the anterior superior spinous process of the ilium, and between the tenth and eleventh ribs, a wound was found, extending obliquely downwards and inwards. On removing the flap of skin covering this portion of the body, the external wound was found to correspond to a point immediately above the tenth rib, and about four inches from its anterior free margin. It had no connection with the thoracic or abdominal cavities. Had this wound penetrated deeper it would have passed into the abdominal cavity under the diaphragm.

There was an escape of bloody serum from the mouth, but no marks of violence about the head.

Pupils somewhat dilated, balls of eyes normal.

Firm pleural adhesions over both lungs, of old standing. Lung-substance normal. The left pleural cavity contained a clot, as well as some fluid blood.

Pericardium firmly adherent to the heart. Heart normal.

An incised wound was found to sever almost the half of the ascending arch of the aorta, in a line directly opposite the seventh and eighth ribs, and opposite the external wound on the posterior left lateral part of the body, as before described. *June 24th*, 1875.

---

24. *Rupture of external iliac artery—death on twelfth day from internal hemorrhage.*

By Dr. John Ashhurst, Jr.

A. R., an engineer, 39 years of age, and a native of this country, applied for admission to the Episcopal Hospital on June 15th, 1875, saying that one week before, he had, in trying to board a railway train, slipped and fallen backwards, striking a rail of the adjoining track, and receiving a severe blow in the region of the lumbar spine. But slight inconvenience from the injury was experienced at the time, but the next morning the patient felt stiff, and had a good deal of pain in his back,—these symptoms becoming more, rather than less, marked during the following days, though even when admitted to the hospital he walked without difficulty, and con-

sidered himself, and was considered, to be suffering merely from a contusion or sprain of the lumbar muscles.

This was on Tuesday. On the following day the patient was in much the same condition, and gave no evidence of having received any serious injury. His bowels were moved by a mild laxative.

On Thursday, June 17th, I found the patient in a cold sweat, and then learned that a similar "sinking spell" had occurred on the preceding day, but had passed off in a short time, and had been, apparently, of a trivial character. The patient now complained of pain in the left side as well as in the back, but there was no great tenderness manifested on palpation, and nothing was discovered to throw any further light on the case. The left common femoral artery was observed to be pulsating with great force, but the pulsation was not expansile in character, and a slight fulness which existed below Poupart's ligament was evidently due to an enlargement of several lymphatic glands. There was no abnormal pulsation nor tumor in the course of the iliac artery.

On Friday, June 18th, the patient was almost in a state of collapse, bathed in a profuse cold sweat, with rapid respiration, and with a pulse running at the rate of 120 or more beats in the minute; he had more pain, still referred to the back and left flank (rather in the hypochondriac than in the iliac region), and vomited a little after taking food, though his diet was limited to milk, mixed with lime-water, and a moderate amount of stimulus. There was no tympanites and no general abdominal tenderness, and the tongue was, as it had been throughout, moist and clean. The pulsation in the common femoral artery was now rather feeble; but there was, on the other hand, a marked pulsation in the epigastric region, perceptible both to sight and to touch; auscultation, moreover, revealed a bruit, not, however, of a very decided character, and not propagated for any great distance along the course of the aorta. There was no bruit in the iliac region. Careful palpation failed to discover a tumor in any part of the abdomen, though there was a slight fulness in the left flank, such as is sometimes observed at an early stage of psoas abscess.

As elucidated by the results of the *post-mortem* examination, the signification of the various symptoms now seems plain enough; but at the time I confess that I felt some hesitation in making up my mind as to the precise nature of the injury. Three conditions presented themselves to my consideration as possibly present,—viz., internal strangulation, latent peritonitis, and internal hemorrhage. The supposition that strangulation existed was negatived by the state of the patient's tongue, and by the absence of constipation; the same circumstances, together with the total

absence of febrile excitement, contradicted the notion of peritonitis; and by a process of exclusion, therefore, I was led to think that the symptoms observed were due to internal bleeding. The source of the hemorrhage was next to be considered. The constant pain in the left flank suggested the existence of rupture of either the spleen or the left kidney; but a careful examination of the patient's urine, made by my very competent house-surgeon, Dr. Rudderow, failed to detect the presence of either blood or albumen, and I could hardly believe that a splenic rupture, of sufficient gravity to prove fatal, could have existed more than a week without giving evidence of its presence. I had, indeed, seen lacerations of the spleen which produced no symptoms during life, and which were only discovered after the death of the patient from other causes; but a rupture so extensive as to endanger life by hemorrhage would certainly have proved fatal at an earlier period. Here, again, then, by a process of exclusion, I was led to believe that the patient was bleeding from a large artery, which had undergone partial rupture at the time of the original injury, and that the efforts of nature to repair the lesion, though temporarily successful, had ultimately allowed the occurrence of profuse hemorrhage. Thus far my opinion was proved correct by the results of the *autopsy*, but I was misled —and, I think, naturally misled—by the absence of pulsation or bruit in the iliac region, and by the presence of both in the epigastrium, to infer that the injured vessel was either the aorta itself, or one of its large abdominal branches.

On Saturday, June 19th, I found the patient almost moribund. There was now a good deal of tympanites, but no general abdominal tenderness; the patient's tongue was still clean and moist; vomiting had ceased, and the administration of a simple enema had produced three copious fecal evacuations. That which the day before was only a fulness in the left flank, now appeared to form an elongated tumor; but the tension of the abdominal muscles on this side was so great that in the patient's prostrated condition no accurate examination was possible. The left-sided pain and tenderness were still increased, and to my former diagnosis of internal hemorrhage I now added that of localized peritonitis. The patient died a few hours after my last visit.

A *post-mortem* examination was made the next day by Dr. T. H. Andrews, one of the coroner's physicians. On laying open the abdomen, recent peritoneal adhesions were found upon the left side, and beneath the peritoneum were found an enormous clot filling the left vertebral gutter from the pelvis to the diaphragm, and above turning inwards and compressing the aorta. The clot having been removed, the source of bleeding

was found in a rupture of the left external iliac artery, about half an inch below the bifurcation of the common trunk; both ends of the torn vessel were retracted, though held together by a portion of the external coat of the artery, and the distal end was partially occupied by a well-formed coagulum. The abdominal viscera, so far as examined, presented a normal appearance.

The symptoms presented in this case were now readily explained. An incomplete rupture of the external iliac artery no doubt occurred at the time of the patient's injury, but either the external coat of the vessel remained intact, or, if it was involved in the rupture, a clot was formed, and the bleeding was temporarily arrested. Hemorrhage began or occurred on

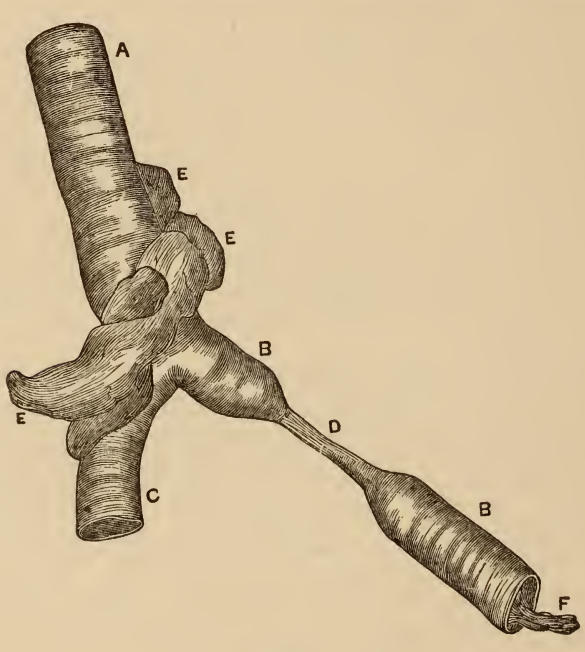

Fig. 3.

A. Common iliac artery.
B. External iliac artery.
C. Internal iliac artery.
D. Position of rupture.
E. Clot overlying common trunk.
F. Clot protruding from distal end of external iliac artery.

the eighth or ninth day, and on account of the anatomical relations of the vessel, bound down as it was by the iliac fascia, the blood found its way

upwards, dissecting up the peritoneum, and finally impinging upon the aorta, thus by pressure producing the pulsation and bruit which misled me as to the situation of the lesion. The femoral pulsation noted on June 17th showed that at that time blood was passing freely through the injured vessel, and was no doubt the forcible pulsation often observed in the arteries of a part from which secondary hemorrhage has occurred or is about to occur. As the bleeding went on, the clot formed about the injured artery exercised a certain amount of compression, and the violence of the pulsation was diminished. With the consequent enlargement of the coagulum, the peritoneum was more and more separated from its attachments, giving rise to steadily increasing pain, and ultimately leading to localized peritoneal inflammation. The arterial rupture was too extensive to permit the formation of a traumatic aneurism, and when secondary hemorrhage occurred the patient literally bled to death.

I have said nothing as to the treatment adopted in the above case, for, in the absence of any certain knowledge as to the nature of the injury, it was, of necessity, purely empirical, and directed to the relief of symptoms; and though it may have prolonged life for a few hours, it of course exercised no influence for either good or evil, as regards the ultimate termination of the case. Had it been possible during life to determine the exact source of bleeding, the propriety of attempting the application of ligatures to the injured vessel would have had to be considered.

June 24th, 1875.

---

25. *Rupture of the aorta.*

By Dr. W. G. Porter.

On the 11th of March I was requested to make a *post-mortem* examination of the body of a colored man, about 40 years of age, who had suddenly died while at work two days before. He was an unusually strong and well-developed man, who had followed the sea until about eight years ago, when, while in the harbor of Galveston, Texas, he was severely injured by a fall from the mast-head to the deck. He was laid up in the hospital at that place for several weeks, but the nature of his injuries it was impossible to ascertain at the time of the *post-mortem*. After the accident he had been working in this city, most of the time being employed as a 'longshoreman; for the last few weeks, however, he had been driving a dray. On Thursday evening last he visited a neighboring drug-store, complaining

of a stitch in the right side, for which he procured a warming-plaster. On Friday he worked as usual; on Saturday, while at work, he suddenly went and sat down on a box, his head fell forward on his breast, and before anything could be done for him he was dead.

Post-mortem examination.—The body was that of an unusually muscular man. On opening the pericardium it was found that it was filled with clotted and fluid blood, and on careful examination an extremely minute opening in the aorta was found on the anterior surface of that vessel immediately above the base of the heart. No atheromatous deposits were found in the aorta, and the other organs were all healthy, with the exception of a slight pleurisy on the right side.

Dr. John M. Guitéras said that there had evidently been some chronic disease going on here. The aorta is very much thickened, and the heart is probably fatty. There had been a thinning out of the walls at the point of ulceration until the adventitia had bulged out and finally ruptured. This process was also indicated by the ragged edges of the inner opening. This case he thought corroborated the opinion he had expressed with regard to a similar case which he had presented two weeks ago, in which rupture of the heart was suspected to have occurred, but where he thought there was really a rupture of the aorta, the heart having been accidentally wounded during the *autopsy.* *March* 11*th*, 1875.

Report of the Committee on Morbid Growths:

"The atheromatous process of the aorta, presented by Dr. Porter, has ulcerated through the inner and middle coats of the vessel, immediately behind the point of insertion of one of the semilunar leaflets, and there formed a small aneurismal pouch in the adventitia which extends like a diverticulum into the pericardial cavity. The walls of this aneurism are unusually thin, and microscopically nothing but connective-tissue fibres were detected. Upon opening the sac, a small clot was found in its interior. The hemorrhagic effusion found in the pericardium no doubt ensued through the rupture of this small aneurism."

March 25*th*, 1875.

IV.—THE RESPIRATORY SYSTEM.

1. *General tuberculosis, with enlarged lymphatics.*

By Dr. Joseph G. Richardson, for Dr. A. Fricke.

The specimens were removed from a German girl æt. 21 years, admitted into the German Hospital on November 17th, 1873. The principal symptoms upon admission were slight cough, headache, pain in the lumbar region and also upon the inner side of the limbs. Her own expression was that she felt tired, and only wished to get into bed. Her clothing was wet; her feet were very cold and wet. The most noticeable feature was great enlargement of the cervical glands. The lymphatics in other portions of the body were also enlarged, as was found upon subsequent examination. At the very first, symptoms of a typhoid character began to manifest themselves. During the second twenty-four hours after her admission she gradually became unconscious. No food whatever, liquid or concentrated, would she swallow. This condition continued, gradually becoming more grave, until she died on November 27th, 1873, ten days after admission.

A *post-mortem* examination was made; it was found that all or nearly all of the organs were more or less infiltrated with tubercles. There were evidences of violent inflammation of the brain: tuberculous deposit at the base, and considerable exudation into the ventricles. The lungs were studded with small abscesses. The liver was affected also, as was the spleen. The mesenteric glands were greatly enlarged; also, the deep lymphatics of the abdomen and pelvis. *February 12th*, 1874.

---

2. *Papillomatous growths in the larynx of a child.*

By Dr. R. M. Bertolet.

I am indebted to Dr. Mears for this fine specimen of laryngeal papillomata. Unfortunately, we have only the left lateral half of the larynx and

trachea to exhibit; the other half of the organ is said to have presented about the same development of the papillary excrescences. The vocal cord is entirely concealed, and the Morgagnian ventricle is nearly filled by these finely-fringed growths, which are also seen covering the ventricular band and extending down over the subglottic region. From such an extensive invasion, which must have almost completely filled up the glottic fissure, it is easy to surmise the symptoms of croup, aphonia, and dyspnœa that must have manifested themselves during life.

The only history obtainable in the case is to the following effect. A male child, 2½ years old, about three months ago became hoarse, and soon presented symptoms of croup, for which it was unsuccessfully treated by a young medical student, until death by asphyxia occurred. No laryngoscopic examination being made during life, no attempt to remove the growths was made. Tracheotomy was not performed. It cannot be ascertained whether the child presented any evidences of hereditary syphilis: the father, however, is said to have marks of constitutional syphilis.

The microscopic appearance of this specimen does not differ from that ordinarily seen in these growths; most of the papillæ are covered with several layers of tessellated epithelium, but at some points a layer of long cylindrical cells is seen covering the entire papillæ. Ciliated epithelium, however, is not formed. These epithelial cells are supported upon a very thin column of connective tissue, with small blood-vessels in the centre of each papilla.

The aggregation of a number of these papillary growths forms the papillomatous tumors of the larynx, presenting the well-known cauliflower appearance. In this region these growths do not differ from those formed upon other situations of the mucous membranes; they closely resemble the hypertrophied papillæ of the cutaneous surface as met with in condyloma and verruca. They are by far the most frequent variety of tumors found in the larynx. Of one hundred growths in the larynx, Mackenzie found no less than sixty-seven belonging to this class. They have been observed much more frequently in the male than in the female. The vocal cords seem to be their seat of predilection. Papillomata of the larynx are also more apt to occur at an earlier period of life than the other varieties of neoplasms. In the forty-eight cases of congenital laryngeal growths and in those occurring during infancy collected by Dr. Causit, nearly all, when examined microscopically, were found to belong to the non-malignant papillomata.

This makes the third case of laryngeal growth occurring during childhood that I have as yet seen and had an opportunity of examining micro-

scopically. One was exhibited by Dr. William Pepper to the Philadelphia Pathological Society in 1871. The other is an unpublished case, which I desire to report briefly in this connection, since its microscopical appearances so closely resemble those of the preceding case that one description and illustration will serve for both. It was also the first instance in which I resorted to the freezing process to induce local anæsthesia of the larynx. This method and its practicability, it will be recollected, were fully detailed at the last meeting of the Society, in connection with the removal of the tracheal growths then exhibited.

E. M., æt. 11 years, was referred to me by Dr. Pepper in November, 1871. One and a half years previously the boy first began to grow hoarse; this gradually increased until he was no longer able to speak above a whisper. Upon attempting to speak loud, he complained of a painful sensation in his throat. When quiet and resting, the patient's breathing was always noisy, accompanied with prolonged inspirations. It became more hurried and difficult after any active exertion. He was frequently aroused from his sleep with more or less pronounced dyspnœa,—"sitting upright and gasping for breath." The aphonia was so pronounced that he was unable to speak loud enough for his teacher at school. No marked general or local affection appeared to have ushered in the hoarseness in this case; the mother and attending physician imagining that the boy was merely suffering with a protracted cold.

The attacks of dyspnœa, accompanied with lividity of the features, also occurred occasionally during the day-time. The mother stated very positively that these paroxysms had very often appeared for several years prior to the commencement of the aphonia, thus pointing to a very early period at which the papillomata first made their appearance. The general health of the patient was undisturbed.

The laryngoscope showed the mucous membrane lining the epiglottis and larynx to be congested and of a deep-red color. The anterior third of the rima glottidis was filled up with a large, uneven mass of papillary growths, of a reddish-white color. They arose from the mucous membrane covering the parts inserted in the receding angle of the thyroid above the vocal cords; a second smaller mass was subsequently observed arising from the under surface of the left vocal cord, also near its point of insertion into the thyroid cartilage. The movements of these growths during forced respiration were very slight.

The larynx was found to be extremely irritable, so that a spasm of the ventricular bands and vocal cords would ensue whenever any instrument

was introduced. This irritability was in a great degree overcome by frequently catheterizing the parts, yet not sufficiently to permit of the evulsion of the growths. Local anæsthesia by means of the chloroform and morphia pencillings, owing to the youthfulness of the patient, was not deemed advisable. The freezing process, however, was applied, and, after several ineffectual attempts, finally permitted the parts to be manipulated with the greatest freedom. At first the pain caused by the rhigolene was too great to be endured for any length of time. Subsequent applications were better borne. The growths were removed by means of the wire écraseur and the crushing laryngeal forceps of Mackenzie, and the points of attachment subsequently cauterized with solid nitrate of silver. The patient being very regular in his attendance, the treatment extended over a period of nearly one year: he was dismissed as cured in October, 1872, a slight roughness only remaining to the voice. The patient would curiously titillate either of his ears; referring the pain to the ear corresponding to the side of the larynx which had been seized upon by the forceps. A number of trials were made of this curious phenomenon by many of my colleagues, in which the patient invariably referred the pain to the ear of the same side as that of the larynx touched. An intense ringing noise, lasting from one to two minutes, would be complained of in the ear, which the patient said was the reason for the insertion of his little finger into the external meatus. *February* 12*th*, 1874.

---

3. *Hydrothorax, from chronic subacute pleurisy; fatty degeneration of the heart, and incipient cirrhosis of the kidneys; paracentesis, followed by great relief; return of pleurisy; death from ulceration of colon.*

By Dr. William Pepper.

J. L., æt. 72, a huckster by occupation, and much exposed to inclement weather, was first admitted to the Philadelphia Hospital in 1863, with acute rheumatism, and was discharged cured in eight weeks. In 1866 he was admitted to the out-ward department, and remained there, in fair health, though somewhat troubled with weakness and occasional palpitation of the heart. In the winter of 1871–2 he contracted a severe cold from sitting in a draught, and soon afterwards began to complain of increased weakness, feverishness at night, pain in the right side, shortness of breath, frequent, dry cough, and soon afterwards of swelling of the feet and legs. The symptoms increased, and he was readmitted to the hospital

on April 26th, 1872, with œdema and ascites, and marked dyspnœa, and palpitation and irregular action of the heart. Upon physical examination, there was flatness upon percussion, with great increase in sense of resistance from the third intercostal space downwards upon the right side. The level of dulness varied markedly with alterations in the position of his body. There was decided enlargement of the right side of the chest, with bulging of the lower intercostal space. The respiratory movements were greatly impaired, and vesicular murmur was absent over the area of dulness. There was, however, a transmitted bronchial breathing-sound over the entire lung. The apex-beat of the heart was pushed considerably to the left. He was placed upon the use of tinct. digitalis, gtt. xij to xv, with spts. juniperi comp., f ℥ss thrice daily; and later there was added to this, potassii acetatis, gr. xij, and potasii iodidi, gr. iii, thrice daily. Tincture of iodine was daily painted over the seat of effusion.

His digestion was greatly disturbed, and the above treatment appeared to diminish his power of taking food, while the symptoms of disturbance of respiration and circulation became so urgent that, on June 3d, a fine trocar was introduced immediately above the eighth rib, in a line with the anterior border of the axilla, and one hundred fluidounces of clear serum were withdrawn through an india-rubber tube attached to the canula, the free end being carried below the surface of water. No suction-pump was used. The operation was productive of immediate and great relief, and was followed by no rise of temperature, or any unfavorable symptom. The apex-beat of the heart returned to its normal position. The lung expanded; the transmitted bronchial breathing disappeared, and vesicular murmur became audible over the upper and front portions of the chest, while dulness on percussion and feeble bronchial breathing persisted in the most dependent posterior parts of the chest.

There was subsequently so much improvement that he left the hospital again, though with evidences of pleural thickening and with some effusion in the left thorax.

He came under observation again in October, 1873, more than a year afterwards. He was then quite weak, with poor appetite and digestion, and constant tendency to diarrhœa. Heart's action irregular and feeble; circulation sluggish, and œdema of feet appearing during day and disappearing at night. There was no valvular murmur.

The following notes of physical signs were made:

"*Right chest* moved much less in infra-clavicular and mammary regions than the left side. Below the lower part of the mammary region down to the lower border of the ribs there is a sinking on each inspiration quite marked

when compared with the left side. Vocal fremitus increased; from the sixth rib to the lower border of the thorax there is a marked depression anteriorly; posteriorly, the conformation of the two sides is alike. Percussion anteriorly is resonant from the clavicle to the fifth rib, below this it becomes flat; posteriorly it is resonant above and for a short distance below the spine of the scapula, below this it is flat. Auscultation, posteriorly, at the upper part of the chest reveals bronchial breathing which becomes fainter as the lower part of the lung is reached, and low down can be just heard.

"Anteriorly, bronchial breathing can be heard as low down as the fifth rib; below this there is with each inspiration a creaking sound; none on expiration. Expiratory murmur can be heard; vocal resonance increased on this side.

"Left chest, very resonant anteriorly and posteriorly; respiratory murmur increased over whole of lung; chest just below the clavicle is slightly fuller than on the other side. In inspiration the whole of this side seems to be lifted upward; movements much more free than on the right side. He has no cough, but some dyspnœa, though not enough to prevent him sleeping on his back.

"There is well-marked arcus senilis around each eye, and vision is impaired.

"Liver-dulness does not extend below the border of the ribs.

"Urine passed very freely; has to get up several times during each night to pass it; quantity large. It is normal in color, and contains no albumen; sp. gr. 1008.

"His treatment consists in digitalis, tincture of chloride of iron, and quinine, with application of iodine to the chest.

"January 6th, 1874.—Since the last note he has been gradually sinking, especially during the last three weeks; he has lost flesh rapidly; there has been much diarrhœa, sickness of stomach, and vomiting. The stools have been very watery, varying from a light to a dark color, and sometimes numbering as many as fifteen to twenty in the twenty-four hours. The matters vomited have consisted of food mixed with a yellow liquid, and have at no time contained any blood. His piles, which he has had for a number of years, have been very troublesome lately. His pulse has been very irregular and intermittent, and so very feeble as to be scarcely perceptible at the wrist."

Every means was taken to keep up his strength, and to stop the diarrhœa and vomiting; but on January 6th, at 8 o'clock A.M., he died.

Autopsy, made four hours after death.—There was a marked depression

on the antero-lateral part of the right chest, at the seventh, eighth, and ninth ribs, over a space about six inches wide and four inches long. The point of puncture was in this area. The scar left by the trocar in the skin was barely visible, and there were no adhesions between the skin and intercostal tissues. Upon the costal pleura there was a minute opening, one-sixth of an inch in diameter, still visible. On opening the thorax, the right lung was found to be compressed, and the pleura tightly adherent. The adhesions were firm all over the pleural surface, but most so at the lower part, where they were very dense, and about half an inch thick. The attachments were so firm that the lungs were with difficulty removed. The adhesions were thickest at the position of the depression of the ribs, above stated; just behind this point there was a small cavity, containing serous liquid, circumscribed by the thickened adherent pleura. The right lung was dark and congested, but still permeable to air. The left lung was normal, but somewhat congested. At the apex of this lung there were some moderately firm pleuritic adhesions; there were none over the rest of the lung.

Heart flabby; much fat on the outside; tissue soft and fatty; no valvular lesion, except some slight thickening of the edges of the mitral valve; heart did not retain its shape when placed on the table; no excess of liquid in the pericardium.

Liver fatty; spleen small; kidneys small and contracted. Extensive ulceration of the large intestine, most marked at the sigmoid flexure.

March 26th, 1874.

---

4. *Pseudo-membranous laryngitis.*

By Dr. Oscar H. Allis.

I present the larynx from a case of *pseudo-membranous laryngitis* in a child 14 months old, removed twenty-four hours after death. The child was taken suddenly ill on Sunday, March 22d, about midday. It had been ailing for a few days with a slight cough, but its symptoms were hardly sufficient to attract attention. The first cause of alarm was extreme dyspnœa, simulating croup. I saw the case late in the afternoon. The child was then extremely restless, presenting every symptom of obstructed breathing,—forty respirations per minute, and with each the chest above the clavicle and below the sternum was deeply depressed. With the inspiration was a harsh and somewhat shrill or hissing sound.

The anterior nares were filled with a hardened mucus, and gave evidence of the presence of a slight catarrhal affection. The tongue was dry (the child was breathing with open mouth), and covered with dark-brown fur. The fauces and pharynx were inflamed, but there was no evidence of inflammatory deposit. There was no unusual heat of skin; no special evidence of fever, save excessive thirst. There was no pulmonary complication. The child lingered thirty hours, with no amelioration of these symptoms.

Autopsy, twenty-four hours after death.—Larynx swollen, with covering of distinct pseudo-membrane. Dyspnœa due probably to the swelling and amount of œdema, rather than to the abundance of pseudo-membrane. Membrane distinct in trachea below the cricoid cartilage, and could be easily floated off by a stream of water. Lungs healthy.

There were two circumstances prejudicial to surgical interference:

1. *The age of the child.*—This, as has been stated, was 14 months. Though few children survive the operation under four years, yet there are fourteen successful cases recorded under 24 months, and five cases under 14 months. The youngest case I have found recorded was by Barthez, at 7 months.

2. *The surroundings.*—The child was an inmate of a "home for children," and it is needless to speak at length either of their condition at these "homes," even under the most favorable circumstances, or the privation and wretchedness from which those residing in them have been transplanted. *March 26th*, 1874.

---

5. *Lungs from a case of acute catarrhal pneumonia with secondary miliary tuberculosis of the pleura.*

By Dr. James Tyson.

The specimens were removed from J. W., aged 33, an Irishman and a seaman of rather intemperate habits. He had descended from healthy parents, and had himself always been well up to two months before admission to the Philadelphia Hospital on March 11th, 1874. About January 1st, 1874, after exposure while drinking heavily, he contracted the illness from which he died. This began with a cough, some dyspnœa, and white expectoration. At first he did not think much of it; but, having lost a good deal of flesh, and beginning to have chills, flushes of heat, and

sweats, he determined to enter the house. There has never been any hæmoptysis.

On admission, March 11th, 1874, he was somewhat emaciated, but not very anæmic; his tongue was coated; he had no appetite, and his bowels were loose; except that he was weak, he said he felt very well, coughing scarcely any, but with some white expectoration. There was, however, fever. He was ordered quinine, counter-irritation by a blister, and opium to control his bowels.

On physical examination there was observed more motion of the left side throughout than the right. In front there was no difference in the vocal fremitus, nor at the sides of the chest. Percussion on right side revealed diminished resonance as far as the fifth rib anteriorly. Left side, resonance was normal in front and at the side.

Auscultation.—Left lung in front and side is normal; some harshness at the very apex. Right lung in front—distinct blowing breathing at apex, becoming almost normal as we reach the base; on forced inspiration, crepitant râle is heard from the third rib upwards.

Posteriorly.—Left lung, supplemental breathing throughout. Right, from spine of scapula down, broncho-vesicular; but above, a dry crackling is heard, and prolonged, almost blowing expiration.

March 18th.—Another blister to the right apex. Ordered yesterday milk-punch, his pulse being weak—114. He was ordered on admission, besides his quinine, a mixture of liq. potassæ, ℥v; syr. tolu, tinct. digitalis, āā gtt. v, and liq. potassii citrat. Bowels yet somewhat loose, though easily controlled by Dover's powder given at night. Coughs very little; expectoration continues white and frothy.

March 19th.—The alkaline cough-mixture was stopped, and gr. iii of quinine, j of digitalis, and ¼ of opium given four times daily.

March 22d.—Bowels are regular; feels very weak. Quinine and punch continued, with a mixture of liq. ammonii acetat., ammonii carbonat., gr. v; tinct. opii, gtt. v, tinct. digitalis, gtt. vj, every two hours.

On March 21st was noted a marked disposition to drowsiness.

April 6th.—Condition continues about the same; temperature ranges from 100° to 101$\frac{3}{5}$°, and pulse 120.

April 10th.—Is failing; ordered a cough-mixture containing bicarbonate of sodium, hydrochlorate of ammonium, and syrup of ipecacuanha, hoping, if possible, to *thin out* the deposit in the lungs; also a large poultice over his chest.

April 16th.—Is undoubtedly better since the institution of last treatment. Temperature 100$\frac{4}{5}$°, pulse 117. Skin moist. On auscultation,

the crepitant râles seem to have disappeared from the right apex and the axilla. Posteriorly, however, the crepitation is distinctly heard in the right supra-spinous fossa. In the left lung anteriorly are heard coarse bubbling sounds, and posteriorly, some sibilant rhonchus. Treatment continued.

The amendment referred to was not permanent: he continued gradually to grow weaker, and died May 12th, 1874.

Post-mortem examination.—On opening chest-cavity the pleuræ of both lungs were thickened; that of left to the extent of three lines; the right one less markedly. The external surface of right pleura dotted throughout with gray granulations; pleura of left lung, which exhibited the most marked thickening, has no gray granulations; diaphragmatic pleura (right side) also covered with these granulations; and so, too, the external surface of pericardium. Old cavities in each apex, the larger one ($1\frac{1}{2}$ inches in diameter) in left apex; the smaller one, with breaking-down walls, in the right one. A solid, cheesy deposit occupying whole upper half of right lung and nearly as large a portion of the left lung. Few miliary gray granulations scattered throughout lower part of lung; but none apparently in the left. In extreme lower part of left lung, in contact with pleural base, was found a little nest of cheesy deposit, three-quarters of an inch in diameter. No miliary gray granulations in brain-membranes, peritoneum, or pericardial sac. Liver very large and fatty, weighing five pounds two ounces. Kidneys passively congested, but otherwise normal.

A study of the temperature-record carefully kept throughout his illness, but too lengthy to be introduced here, reveals the striking difference between the morning and evening temperature so characteristic of acute catarrhal pneumonia. Although the case was carefully watched to this end, there was no change or symptom to which we could point as indicating the onset of the miliary tuberculosis. The symptom of drowsiness was once noted as one likely to indicate this complication; but the absence of tubercle from the membrane of the brain proved this suspicion to be unfounded. *May* 14*th*, 1874.

---

6. *Chronic pleurisy with phthisis.*

By Dr. De F. Willard.

The specimens are derived from a case of chronic tubercular pleurisy with large effusion, from A. B., male, 28 years of age; admitted to the Presbyterian Hospital May 23d, 1874. Walked to the hospital, and did

not complain of much fatigue. The only history gleaned from him was to the effect that he had had what he called an attack of "pneumonia" (undoubtedly pleuro-pneumonia) about three months previously, which detained him in bed for several weeks. His health had been failing for some months previous to this attack, but since that he had been totally unfit for work, although he has not been under a physician's care. On admission, his left thoracic cavity was found full of liquid, but no further examination was made that night. The next day he was seized with violent dyspnœa, and died within less than twenty-four hours from the date of admission. Just before and immediately subsequent to death a large amount (a pint) of thin frothy fluid was discharged from his nose and mouth.

Autopsy, at which time he was first seen by myself.—In the left pleural cavity were found three and a quarter quarts of serum and pus intermixed with flakes of lymph. The lung was compressed into a mass about the size of two fists, and was firm and dense. Both the parietal and visceral layers of the pleura were greatly thickened, and the former could be easily detached from the inner surface of the ribs without tearing. The entire pleural surface was covered with a dense layer of whitish, tough, semi-organized lymph, with large fringes and folds which hung loose and floated in the liquid, filling the cavity. At one or two points, small, feeble bands were stretched across the space from the surface of the visceral pleura to the parietal layer. The lung, when opened, revealed a large cavity at the apex, filled with pus, and the entire condensed portion was filled with cheesy masses in various stages of degeneration. No healthy lung-tissue existed. The right lung contained a small cavity at the apex, and the upper and middle lobes were quite thickly studded with miliary tubercles. The whole lung was filled with an effusion of serum, which was undoubtedly the cause of his dyspnœa and sudden death. The heart, liver, kidneys, and other organs were comparatively healthy in their superficial appearances. The operation of tapping had been considered, but the crippled condition of the left lung was such as to have prevented any expansion even had the pressure been removed. *May* 28*th*, 1874.

7. *Albuminoid expectoration.*

By Dr. Wm. Pepper.

I desire to call attention to a morbid discharge which I met this morning for the first time. It is the condition known by the French writers as albuminoid expectoration, which presents itself sometimes after paracentesis of the chest. I have, in connection with Dr. Thos. J. Yarrow, drawn off from the chest of a patient with hydrothorax, probably connected with tuberculous disease of the pleura, seventy-five ounces of serum. The operation was easily performed with the aspirator, and gave the patient great relief; but towards the end of the operation there was grating of the roughened pleura against the canula, which caused me to desist. There also occurred, subsequently, some troublesome cough, which was, however, relieved by deodorized tincture of opium. The fluid drawn off promptly coagulated, the latter portion becoming semi-solid, like soft jelly.

In about eighteen hours after the operation he began to expectorate very freely a peculiar matter, consisting of an abundant muco-fibrinous coagulum floating in a straw-colored serum, the amount raised in twenty-four hours being at least three gills. It resembled so closely the fluid drawn off from the chest as to attract the notice of the family. This peculiar expectoration corresponds with what has been described, especially by the French physicians. The amount which is reported to have been expectorated in some cases much exceeds what occurred here. Various explanations have been offered for this phenomenon, but no one seems to have entirely established itself. Some have attributed it to laceration of the lung and the escape of some of the pleural effusion through the bronchi, but such did not occur in this instance, since there was no hæmoptysis, pneumothorax, or other evidence of puncture of the lung-tissue.

It has also been suggested that this expectoration depends upon a rapid collateral œdema or transudation into the bronchi, which occurs while the lung is expanding and returning to its original state; and this appears the most probable view of the matter.

The patient had a dangerous syncopal attack six or seven hours after the operation, from which he was, however, aroused by stimulants.

June 11*th*, 1874.

8. *Portion of lung from a case of pulmonary phthisis, with cavities (bronchiectatic?), hæmoptysis, death from asphyxia. Enormous clot of blood in a large cavity in right lower lobe.*

By Dr. Wm. Pepper.

Mrs. C., æt. — years, with disposition to phthisis inherited from her mother, enjoyed excellent health until the early part of 1873. Cough then set in, at first slight and dry, but later attended with abundant nummular purulent sputa. There was but moderate hectic, no hæmoptysis, but quite rapid emaciation and great prostration. Menstruation continued regular. She was under the care of various physicians, and first consulted me in April, 1874. There were then the physical signs of several small cavities along the anterior surface of the right lung, and of a larger one at the angle of the right scapula. In the left lung there were several points of softening in the upper lobe. The lungs were evidently emphysematous. There was extreme prostration, with marked dyspnœa.

The treatment consisted chiefly of quinia and iodide of iron. On June 17th there occurred a profuse hæmoptysis. This was soon checked, but was followed by increased prostration and frightful dyspnœa, with greatly diminished cough and expectoration. The sputa became more and more free from blood, and for forty-eight hours before death were of a light chocolate-color. Respiratory sounds in the right lung were less clear, and associated with diffused moist and sonorous râles. Death occurred from asphyxia on the 23d.

At the *post-mortem* examination, there was marked emphysema of the lungs. In the left one there were several small cavities, varying in size from one-third to three-fourths of an inch, and deeply seated. These cavities communicated with bronchi, and were lined with smooth membrane. Elsewhere there were several nodules of caseous matter.

On right side there were several small cavities in anterior part of lung, but the largest was on posterior surface, about level of angle of scapula. This vomica was fully three inches in diameter; it was very superficial, lying immediately beneath the somewhat thickened pleura, which was adherent to the costal pleura over this space. The cavity itself was limited by a distinct fibrous capsule, which could be dissected away from the surrounding lung-tissue as though it had been a heterogeneous cyst. Two bronchi of considerable size entered it. Its lining membrane was slightly roughened and granular; in places a faintly-marked trabecular appearance was visible. On lower wall of cavity there was a button-like prominence

three-eighths of an inch in diameter and one-fourth of an inch high. Probably the hemorrhage had proceeded from this spot. The entire cavity was filled with a solid, dark clot of blood, weighing not less than half a pound. None of the other cavities contained blood. The bronchi were filled with thick muco-purulent matter. There were also scattered nodules of cheesy matter, some firm and partially fibroid, others disintegrating. These were usually circumscribed by a fibrous capsule. There was no diffused bronchiectasis. The heart was healthy. The abdominal organs were not examined. It is not unlikely that the hemorrhage proceeded from this small projection into the cavity. *June* 25*th*, 1874.

Report of the Committee on Morbid Growths on the button-like prominence upon the inner wall of the cavity, presented by Dr. Pepper, June 25*th*, 1874:

"This body has been hardened and sections made. The central portion of the node is occupied by a firmly coagulated blood-clot, while the thick limiting membrane is made up of a layer of fibrinous connective tissue, succeeded by a stout layer of non-striated muscular fibres arranged in longitudinal and transverse rows; thus at once suggesting the middle and outer coats of an artery. No traces of the tunica intima are discernible, nor could any communication with the lumen of the blood-vessels beyond be satisfactorily established. Your committee are undecided whether to regard this prominence as an aneurismal dilatation, or as the stump of a larger artery formerly traversing the vomica and now filled with an embolus. In either case it probably proved the source of the fatal hemorrhage."

September 10*th*, 1874.

---

9. *Cast from a bronchial tube.*

By Dr. J. Solis-Cohen.

This specimen was expectorated in my presence a few days before by a male office-patient, 34 years of age, suffering from pneumonic and laryngeal tuberculosis. It is about two inches in length, tapering towards each end; one end being smoothly rounded, and the other having an impress from the angle of a branching tube. It was one-fourth of an inch in diameter in its thickest portion. Atropia was being successfully administered at the time, for night-sweats.

Dr. R. M. Bertolet said the cast was composed of exudation-corpuscles, some organized fibrin, and a few epithelial scales. The latter were much less numerous than usual in these cases. *September 23d*, 1874.

---

10. *Abscess of the lung.*

By Dr. John Guitéras.

The specimen was derived from F. W., æt. 26; colored. Was admitted on the 30th of March into the wards of Blockley Hospital. His friends stated to the nurse that he had been ailing with some chest-trouble for about two years.

On the 29th, the day before admission, he had a very severe chill, and on the evening of the 30th his temperature was 103°. On the 31st, morning temperature 100°; evening temperature 101°. On April 1st, morning temperature 99½°, pulse 105; evening temperature 100°. On the 2d, morning temperature 97°, pulse 84; evening temperature 98⅕°, pulse 80. This day I saw him for the first time, and found him very drowsy, so that the only information I could obtain from him was that he had been ailing for two months, but had only become very ill the last week. His skin was cold and clammy. He had commenced to expectorate large amounts of a brown and extremely fetid fluid.

The respiratory movements were impaired, and the vocal fremitus was increased throughout the right side. Percussion over the upper lobe in front elicited a tympanitic, low-pitched resonance at the apex; farther down and towards the axilla the note became higher pitched, but more metallic. Complete dulness was developed over the whole right lung posteriorly. Auscultation revealed a loud, harsh, inspiratory sound, with a prolonged expiration at the apex. Towards the axilla the sounds became fainter, until they were absolutely lost in the axillary line. Here they were substituted by a crackling, which sounded sometimes like a large moist râle, at others like a friction-sound; it had at the time no cavernous or metallic echo. I imagined that there was very little if any air moving in and out of this cavity at the time of his examination. Posteriorly there was well-marked bronchial breathing. The left lung gave evidences of vicarious function throughout.

Not finding any evidences of chronic disease of the lungs, I thought

that the breaking down of the pulmonary tissue must have been acute,—either abscess or gangrene of the lung.

The diagnosis of the physical condition—viz., a large cavity near the anterior surface, surrounded above by lung-tissue pervious to air, and below by consolidated tissue—was confirmed by the *autopsy*. On the 3d, morning temperature $97\frac{1}{5}°$, pulse 90; evening temperature $99\frac{3}{5}°$, pulse 96. On the 4th, morning temperature $99\frac{1}{5}°$, pulse 99, respiration 36; evening temperature 100°. On the 5th, morning temperature 97°, pulse 136, respiration 60; evening temperature $98\frac{1}{2}°$. At the time of death, 8 P.M., the temperature was $96\frac{4}{5}°$.

Autopsy.—The subject was a very muscular and well-nourished negro. The upper lobe of the right lung was firmly adherent to the chest-walls. The lower lobe was separated from them by a small quantity of fluid. The diaphragmatic pleuræ were adherent. The left lung was simply congested and œdematous, almost to the extent of splenization. The right lung presented in the upper half of the superior lobe, and towards the antero-lateral surface, a large cavity occupying about one-half the volume of the lobe. Its walls presented excavations in different directions, and they were lined in some places with a smooth membrane; at others, ragged pieces were seen floating from the surface. Evidently the extension of the necrobiotic process had been arrested in some places, though the cavity still contained a considerable amount of the brownish fluid that he expectorated so freely. The apex of the right lung was still pervious to air; but around the cavity and elsewhere through the lobe the tissue was in a condition of purulent infiltration, readily breaking down under the finger. The lower lobe was in the stage of red hepatization. Nowhere was there any evidence of chronic inflammatory change of the pulmonary tissue, or of deposit of caseous matter.

The specimen answers very closely to the descriptions given by authors, both of gangrene and abscess after the process of destruction is arrested. I leave it, however, with the Society to decide whether I am right in entirely rejecting any chronic element from the process of destruction in the present case.

Dr. Pepper said the patient was in his wards at the Philadelphia Hospital, but that, on account of unavoidable absence extending over a few days, he did not have an opportunity to examine him. But he thought from the description of the lesions that at least we must admit two separate stages of disease, or perhaps two diseases which had originated at different periods. He thought it scarcely possible that the acute inflammatory condition of the lower lobe, and the lower portion of the

upper lobe surrounding the abscess, could be of the same date as that part of the disease which had led to the production of the anfractuous cavity with smooth lining membrane. Dr. Pepper remarked that an abscess (cavity?) in the lung could exist for some time, and that the lung could be attacked by an acute destructive process leading to gangrene and purulent infiltration of the tissue surrounding the cavity; that this was a more reasonable supposition than one which explained the condition by a single process which should have passed so rapidly through acute inflammation to acute gangrene of the lung, while the appearances of the cavity and the adhesions of the upper lobe to the pleura would suggest some morbid action of long standing.

Dr. Guitéras said there was no disease whatever of the opposite apex, and he had never seen a case in which chronic disease had advanced so far on one side without being attended by some disease of the other lung. Further, the patient was what might be called a typically-healthful and remarkably well-developed negro, so far as the external evidences of health were concerned.

Dr. Pepper replied that the points raised are those which give to the case its unusual interest, and perhaps render uncertain the exact determination of the stages of development of the lesion. It is to be regretted that there had been no opportunity for previous examination of the lung. It is to be remembered, however, that it is not uncommon to see cases of chronic cavity in one lung, the subjects of which are in apparently good condition (though liable to intercurrent disease, or sudden outbreak of tuberculous deposition), and that in such cases it is not rare for the disease to be limited to one apex for a long time. *April 8th*, 1875.

---

11. *Tubercular ulceration of the larynx and trachea.*

By Dr. R. M. Bertolet.

Considerable diversity of opinion has for a long time prevailed among pathologists, and even exists at the present day, as to what actually constitutes the morbid process which underlies and induces the extensive ulcerations of the laryngeal and tracheal mucous membranes so frequently marking the termination of pulmonary phthisis. Modern research has dissipated many so-called tuberculous masses. Thus, the "crude tubercle" of Laennec has been resolved into simple caseous pneumonia; while

"phthisis renalis" has been proven to be, in the majority of cases, minute capillary embolism, or inflammatory foci; the miliary tubercle being something altogether accidental.* This same tendency to limit strictly the term "tuberculous" to cases in which the actual presence of the miliary granulum is clearly demonstrable has likewise been applied to the affections of the larynx, with the result that now many deny *in toto* the eruption of tubercles in this site of the body.

The unusual activity which has been awakened in the study of diseases of the throat since the invention of the laryngoscope places it beyond a shadow of doubt that much of what was formerly designated as laryngeal phthisis has no connection whatever with tuberculosis. Yet I think the mark has been over-reached by those who disclaim entirely the tuberculous character of all laryngeal ulcerations. The proneness which tubercle, when seated in the laryngeal mucous membrane, exhibits towards necrobiosis explains, in a measure, the fact why, in this site, it so often escapes detection; tubercle being no longer recognizable as such when once it has undergone caseation and softening. There is nothing characteristic in the broken-down *débris* of tubercle.

In the literature on this subject we find two views entertained,—one group of authors maintaining that tubercle does not occur in laryngeal ulcerations, while the others ascribe an important *rôle* to tubercle in these affections. Among the former may be cited Rühle,† who, after years of diligent search, found but two specimens of miliary tubercle among hundreds of laryngeal and tracheal ulceration of phthisical patients. Most frequently simple catarrhal or follicular ulcerations were observed; the latter especially at those points of the larynx where the racemose glands are aggregated,—namely, upon the posterior surface of the epiglottis, upon the upper portion of the posterior laryngeal wall, and in the Morgagnian ventricles. Türck,‡ also, and with him many others, adopt the view of their mode of origin which was first studied and promulgated by Rheiner.§ The catarrhal inflammation which forms the basis for the ultimate loss of substance is characterized as a destruction of the epithelium, and a thick cellular infiltration of the mucous and submucous tissues. This infiltration Rheiner regards "as a uniform proliferation of pre-existing elements." The margins of the ulcerations are usually pale, and thickened by a serous

---

* Ebstein, Nierenkrankheiten; Ziemssen, Handb. d. spec. Path. u. Therapie, Bd. ix. S. 35.

† Kehlkopfkrankheiten, Berlin, 1861, p. 261.

‡ Türck, Klinik d. Krankh. d. Kehlkopfes, Wien, 1866, S. 263, 355.

§ Cannstatt's Jahrb., Jahrg. 1853, Bd. ii. S. 55.

or œdematous infiltration. Papillæ, which, according to Rheiner, do not normally occur in the larynx, appear in the vicinity and upon the margins of old ulcers.

Rindfleisch* very graphically describes the various pathological appearances induced by the chronic infiltration of the laryngo-tracheal glands, and asks, "If the weightiest and gravest disturbances of the larynx and trachea are alone induced by catarrhal inflammation and ulceration, what is left for tuberculosis to perform? Do tubercles at all occur in 'phthisis laryngea,' and what *rôle* do they play?" This author, while admitting having found cellular foci in still intact portions of the connective tissue recalling the appearances of miliary tubercle, ascribes to them no higher value than that of a permanent irritant, and thus accounts for the persistency and tendency to recur which is so characteristic of these catarrhal inflammations.

Of those who, on the contrary, view the lesions in question as decidedly tuberculous, we need but mention Virchow and Rokitansky. According to the latter,† tubercles occur in the laryngeal mucous membrane, as in most other mucous membranes, in the form of small granulations or massive infiltrations. From their destruction ulcerations appear, which are, therefore, of positive tubercular nature. These often extend into the submucous tissue, have hard, raised, undermined edges, often having "papillary vegetations" covered with excessive epithelial formations. In the vicinity occur injection, redness, swelling, and œdema. This is the mode of the development of the primary tuberculous ulceration, which by confluence with others, and partly by the breaking up of fresh tubercles upon the margins, brings about the secondary ulcer.

Virchow‡ as positively asserts the presence of tubercles in the larynx, and further points out that when seated very superficially in the membrane they are apt to soften and form small, shallow, simple, tubercular ulcerations without even having ever undergone caseation or attained a size appreciable to the naked eye.

After excluding the catarrhal ulcerations, which have been so often mistaken for tuberculous, there still occur a limited number of ulcerations in which it is possible to demonstrate the existence of miliary tubercles in those parts of the mucous membrane where the mucous glands and their ducts remain unaffected. In one of the three specimens of the human

---

* Lehrb. d. Pathol. Gewebelehre, Zweite Aufl., S. 329.

† Rokitansky, Lehrbuch d. path. Anat., Bd. iii. S. 27.

‡ Virchow, Geschwülste, Bd. ii. S. 644.

larynx and trachea which are herewith presented to the Society, this is very notably the case; the extensive loss of substance is remarkably limited to the mucous membrane directly covering the tracheal rings and the vocal cords, and although a number of the tracheal cartilages are laid bare by the ulcerative process, yet we find the inter-cartilaginous spaces, the posterior surface of the epiglottis, Morgagnian ventricles, and other points which are most abundantly supplied with mucous glands, unaffected.

In the two other specimens, the ulcerations are more extensive, but limited principally to the glandular localities; yet at certain distances from the œdematous and papillary margins I have also found in them unmistakable miliary tubercles beneath an attenuated epithelial covering. All of these specimens were obtained from exquisitely pronounced cases of tuberculosis. I will not delay to give their clinical histories, save a brief synopsis of the first case, which is interesting not only from the fact that it is eminently a tubercular and not a follicular process, but illustrates the probable manner of infection (auto-inoculation), and the extreme rapidity with which these ulcerations may be developed.

J. W., æt. 36, a laborer, native of Bavaria, was admitted into the German Hospital March 19th, 1875, and died upon the 25th of the same month. He had been an inmate of the institution upon two former occasions during the last year and a half, then presenting all the physical and subjective symptoms of chronic pneumonic processes in the apices. The troublesome cough and abundant expectoration were successfully combatted upon both occasions, and the patient, rapidly regaining his strength, was enabled to resume his ordinary labors, which subjected him to much outdoor exposure. No laryngeal complications presented themselves in his earlier attacks, but upon his last admission there was marked aphonia; hoarseness only developed a few days before. The sputa were muco-purulent, but not very abundant.

There were at once detected all the physical signs of small vomicæ in the apices, and increased vocal fremitus, and impairment of the resonance, extending posteriorly to the base of the lungs. Subcrepitant râles, both anteriorly and posteriorly, were heard upon auscultation; cavernous respiration in the infra-clavicular region. The heart-sounds were normal. The urine was of a high specific gravity, loaded with urates, but free from albumen.

The patient had been actively employed until within a week previous to his entrance into the house, and presented a robust appearance, which was far from indicating the serious malady with which he was affected.

However, the previous history, together with the rapid pulse, the hurried respirations, and the extremely high temperature (never under 100° F. during the entire six days) left little doubt that acute tuberculosis had supervened upon the breaking down of old caseous foci seated in the lungs.

The patient very rapidly lost strength and emaciated; the bodily temperature continued excessive in spite of large doses of quinine and other antipyretic remedies. There were, as is ordinarily observed in these cases of tuberculosis, marked morning exacerbations, the temperature exceeding by three or four degrees that noticed in the evening. The febrile disturbances were attended by digestive derangements, and, upon the last few days, profuse diarrhœa set in; stools slightly tinged with blood.

A laryngoscopic examination showed a congested condition of the entire laryngeal mucous membrane, with a few punctiform yellowish prominences upon the posterior surface and margins of the epiglottis. Only the most superficial ulcerations could be detected upon the upper and inner surfaces of the vocal cords. No satisfactory view of the trachea was obtained, and, not desiring to fatigue the patient, all further attempts at examination were discontinued.

Autopsy.—The body was noted as considerably emaciated; firm pleuritic adhesions existed over the upper lobes; about an ounce of serous effusion in both pleural cavities. A caseous infiltration partially solidified both the upper lobes; disseminated throughout these, and less uniformly in the lower lobes, were numerous gray miliary tubercles. A cavity the size of an English walnut, with ragged walls, had formed in each apex. There was peribronchial induration of the adjacent bronchioles, which at many points were dilated and plugged with yellow, cheesy masses, while the mucous membrane was inflamed and at many places ulcerated. There was hypostatic œdema in the posterior and pendent portions of the lower lobes; bronchial glands enlarged. There were numerous equatorial ulcerations of the small intestines, the mesenteric glands being moderately enlarged. There was considerable intumescence of the liver, spleen, and kidneys, the former being fatty, and the latter showing cloudy swelling of the cortical epithelium. No miliary tubercles were detected in these organs.

The larynx and trachea obtained from this case, as previously stated, exhibit very extensive destruction of the mucous membrane covering many of the tracheal rings, and superficial erosions upon the vocal cords. Portions of this and of the other specimens were frozen, and thin sections made of them in the fresh condition, while other parts were hardened in a solution of chromic acid. The result of the microscopic examinations

may be briefly summarized as follows: a diffuse cellular infiltration of the tissues around the mucous glands and their ducts, extending from the margin of the ulcerations far into the adjacent mucous membrane, giving it a finely granular appearance. Under higher powers this resolves itself into a lymphadenoid tissue with cells of a roundish shape, usually having a large nucleus. A finely reticulated net-work, generally fibrillated, or else minutely granular, separates the cells. Often the glands are hypertrophied and their ducts occluded with secretion; yet this peculiar net-like tissue is also found around follicles which present a normal appearance. It is also found at points, but always sub-epithelial, where no ulcerations have yet occurred, the mucous membrane being still intact. Very often, however, the epithelial covering is elevated and attenuated, beneath being found a circumscribed mass with a large, compact, granular centre. The readiness with which the periphery of this nodule takes up carmine, its multinuclear giant cells, its reticulum, and its entire appearance, leave room for no other interpretation than that of tubercle. Confirmatory observations of these appearances, with most excellent microscopic illustrations, have been made by Wahlberg,* who, in his exhaustive studies upon this subject, also minutely describes the various alterations occurring in the squamous and cylindrical epithelium. Wahlberg ascribes the localization of this peculiar adenoid infiltration in the parts around the mucous glands and their ducts to the fact that they are surrounded by an extremely well-developed capillary net-work.

I have been very much interested in noting the liability, in this and in a great many other specimens where the tubercular and not the catarrhal processes predominated, of the mucous membrane covering the sharp projecting edges of the tracheal rings and vocal cords to become involved first. If we consider how nearly uniformly successful the attempts at inoculation with tuberculous material have proven, the sputa alone of tuberculous patients sufficing, to say the least, it cannot but appear plausible that the same matter should possess equally infectious properties whilst still remaining in the human body, especially so when the circumstances attending its engrafting are so unexceptionably favorable. The tenacious sputa clinging to the tracheal walls and exerting their greatest pressure and friction upon the projecting ridges not only exercise a deleterious influence upon the epithelium, but also cause a hyperæmic condition of the underlying capillaries; the moment arrives when the sputa are loaded with tuberculous elements, some of them still, perhaps, possessed of amœboid movements,

* Medicinische Jahrbücher, 1872, Taf. VII.

and the ground for this tubercular seed is in excellent tillage, and freely supplied with running streams of lymph and blood.

Another reason suggesting and favoring this view of a local infection by the direct contact is the infallible precedence of a tubercular process in the lungs. This statement is only apparently at variance with the ground held by many of the best laryngoscopists, that tuberculous laryngitis may be developed before there are any lung-complications, since they are disposed to designate by this same term ulcerative laryngitis even when dependent upon mere chronic follicular inflammations; and I doubt very much whether a rigid discrimination beyond the mere site of the ulcerations is possible, for miliary tubercles are not recognizable as such by the laryngeal mirror.

In all the autopsies where I have succeeded in detecting true tubercular ulcerations of the throat and windpipe, I have invariably found tubercles existing in the lungs. Should this view of their growth in the trachea and larynx by local inoculation be corroborated by further observations, then the statement made by Louis, that the sharp secretions of the sputa excoriate the mucous membrane, is after all not quite so absurd. Curiously enough, however, Louis denied the tuberculous character of all laryngeal ulcerations. *April 8th*, 1875.

---

12. *Lungs from a case of empyema.*

By Dr. F. P. Henry.

Virginia S., æt. 24, was admitted to the Episcopal Hospital on September 27th, 1874. Her illness, which has lasted about a year, began with a chill, followed by pain in the left side, cough, and swelling of feet and legs. She suffered from *chills and fever* during the entire summer.

On admission, she presented the following symptoms and signs: Decided emaciation, dull expression of countenance, pallor, and profuse perspiration night and day. Sputa copious, tenacious, and yellowish, and emit a faint disagreeable, sickening odor. Flatness over the entire left thorax up to the supra-scapular region, and to a corresponding line in front; above that point, dulness. Respiratory sounds absent in the region of flatness. In the region of dulness there is a high-pitched, almost musical sound, attending expiration; this sound is prolonged, and is heard much less distinctly in front. The inspiratory sound in the region of dulness is bronchial. At the right apex there is a blowing expiratory sound, and dulness on percussion. Below, the resonance and respiration are normal.

The heart's apex-beat is under the right nipple.

The decubitus is constantly upon the left side; any attempt to lie upon the right side invariably brings on an attack of coughing, which does not cease until the original position is resumed.

There is too great an amount of œdema upon the left side to make it possible to decide whether there is any bulging of the intercostal spaces. In the early part of October, measurement showed the left semi-circumference of the thorax to be an inch greater than the right.

The treatment of the case was at first purely medical, and consisted of measures to promote absorption of the effused fluid, the nature of which at that time could not be determined with certainty.

On November 13th, the fluid having in the mean time increased in quantity, I requested the attending surgeon, Dr. Packard, to perform paracentesis. This was done at the eighth interspace, and three-fourths of a pint of pus was withdrawn by means of the aspirator. I was surprised at the result, as it was evident there was a much greater amount of fluid in the pleural sac. The position of the heart remained the same, and no expansion of the lung could be detected. Nevertheless, there was a decided improvement in the general condition of the patient after the operation, and her respiration was free. This improvement was of not more than a week's duration.

On December 19th I tapped in the seventh interspace, and removed four pints of pus with the aspirator. The improvement was this time somewhat more permanent, but about January 1st the unfavorable symptoms began to return. The dyspnœa became more urgent, the cough more troublesome, and the sweating more profuse, in spite of large doses of belladonna, which had previously held it in check. At this date the patient was taking thirty ounces of milk-punch (one-third whisky) and sixteen grains of quinia in the twenty-four hours.

January 3d, 1875, morning.—Temperature, 98½°; pulse, 100; respiration, 28.

Evening.—Temperature, 99°; pulse, 98; respiration, 26.

January 4th, morning.—Temperature, 101½°; pulse, 108; respiration, 40.

This sudden increase in pulse, respiration, and temperature may be attributed to agitation of mind at the prospect of another operation. On this day Dr. Ashhurst, the attending surgeon, tapped in the eighth interspace, removed five quarts of thick, greenish-yellow pus through a trocar, and introduced an india-rubber drainage tube.

Evening.—Temperature, 100¾°; pulse, 116; respiration, 44. Since

the operation about a pint and a half of pus has drained away. The air which passes in and out of the pleural sac, with a loud rattling noise, at each respiration, renders it impossible to determine whether the lung has expanded to any extent.

January 5th.—Feels better. A.M., pulse, 94; temperature, 98°; respiration, 27. P.M., has some nausea, and diarrhœa. Pus continues to drain away at about the rate of a pint in twenty-four hours. Pulse, 120; temperature, 102½°; respiration, 38.

January 6th.—Passed a restless night, and is very weak. Milk-punch disagreeing, plain milk and brandy and egg are substituted. Pleural cavity was washed out, first with tepid water, afterwards with a dilute solution of liq. iodin. comp. (ʒi to Oiss), and, lastly, with tepid water. Pulse, 104; temperature, 101°; respiration, 48. About 3 P.M. there was vomiting of a greenish fluid, and soon after the patient passed into a state of collapse, and died about 4 o'clock.

The *autopsy* was made twenty hours after death, by the resident physician, Dr. Merrill.

Liver somewhat enlarged, and fatty. Intestines, mesenteric glands, kidneys, and spleen normal. The heart was pushed far over to the right side, where it had contracted adhesions. Some recent lymph was observed upon the visceral layer of the right pleura, and some fluid in the corresponding cavity. A few caseous nodules at the right apex.

The left lung was compressed into a firm oblong mass, not much larger than the fist, and lay in the upper and back part of the cavity, being closely bound down to the vertebræ. The pleura was greatly thickened, and the lung was covered with a layer of inspissated pus.

There are two depressions in the lung-tissue which at first sight might be regarded as communications between the pleural sac and the bronchi, but water could not be forced through them by injection from the left bronchus. They appear to be abortive attempts at perforation of the lung. There are two firm and large circular bands of adhesions between the two pleural layers. *March* 11*th*, 1875.

---

13. *Larynx of a man strangled with a piece of meat, together with the bolus.*

By Dr. Edw. L. Parks, for Dr. F. F. Maury.

P. M., about 50 years of age, after a hurried dinner, seated himself in an eating-saloon. Soon violent symptoms of strangulation followed,

which failed to dislodge the foreign body, and in about five or ten minutes he died.

The notes of the *examination* are, "External appearances normal, except a slight scratch over left eye. Slight *post-mortem* discoloration. Pupils natural."

The trachea and larynx being removed, a large bolus of meat, weighing about ʒiv to ʒvi, was found impacted in the larynx.

June 24th, 1875.

V.—THE GENITO-URINARY APPARATUS.

a. KIDNEYS, BLADDER, ETC.

1. *Cystic kidneys; tubercular phthisis; ulceration of stomach and intestines.*

By Dr. De F. Willard.

The specimens were removed from Mrs. A. B., æt. 68, admitted to the Presbyterian Hospital with a history of long-standing cough and diarrhœa. She was supposed, some years since, to have an ulcer of the stomach, but nothing further is known in regard to her history. On admission she had abundant expectoration and frequent, profuse, and offensive stools, and sank rapidly.

Autopsy, twelve hours after death.—Body in ice; amount of *rigor mortis* consequently uncertain; emaciated.

Right lung.—Small cavity at apex. Lung filled throughout entire extent with patches of miliary tubercles. Softening taking place at several points.

Left lung.—Apex occupied by a large cavity, containing an ounce of purulent fluid. At numerous points in both upper and lower lobes small cavities were encountered, while scattered through all the substance of both these lobes were abundant tuberculous spots of the miliary variety. Both apices firmly adherent to parietal layer of pleura. Small excess of fluid in pleural cavity.

Stomach.—Near the pylorus was found an ulcer three-quarters of an inch in length by one-half of an inch in breadth, extending through the mucous membrane into the submucous tissue. The edges were steep, and the base occupied by a dark material resembling ecchymosed blood.

Intestines.—From the duodenum to the rectum there were from one hundred to one hundred and fifty ulcers, of size varying from that of a pin's head to an inch in diameter, and presenting various stages of ulceration and healing action. Some were apparently entirely healed, and in their cicatrization had so drawn upon the mucous membrane that it presented a peculiar appearance, with folds radiating from their centres in

every direction, the membrane being puckered longitudinally, transversely, and obliquely.

These ulcers were most numerous in the lower portion of the ileum, the cæcum, and the ascending colon, but were quite abundant in every portion of both small and large intestines.

The *liver* and *spleen* were normal.

Kidneys.—Right: hypertrophied, but normal relation preserved between the cortical and medullary portions. Left: densely indurated, and with the capsule so adherent to the surrounding fat that it was removed only with great difficulty.

The secretory substance was apparently entirely destroyed, and its place occupied by six or seven cysts, containing a thick purulent fluid. One cyst, near the upper end, was filled with a peculiar white, pasty, and nearly solid substance, which resembled plaster of Paris when prepared for making casts, but was unctuous and smooth. *June* 25*th*, 1874.

Report of the Committee on Morbid Growths:

"The cystic kidney presented at the last meeting has been examined by your committee; the thick walls of the cysts are made up of a dense, fibrillated basement-membrane, and are lined upon the inner surface with flat polygonal epithelial cells. The surrounding uriniferous tubules are greatly displaced, often entirely obliterated, by the excessive proliferation of the interstitial connective tissue; their epithelial covering is seen in the various stages of fatty infiltration and disintegration, while their lumen is not unfrequently occupied by fibrinous cylinders; here and there, however, traces of a secreting parenchyma are visible.

"As to the soft, cheesy, white mass contained in the large cystic cavity of the cortical substance, it is found to be made up in greater part of fat- and pigment-granules, of epithelial detritus, colossal cholesterin tablets, and amorphous granular matter; the latter, consisting of carbonate of lime and a colloid substance, yielding the albuminoid reactions. It contains no uric acid or other crystalline products of the urine."

September 10*th*, 1874.

---

2. *Cirrhotic kidneys, with enormous hypertrophy of the heart.*

By Dr. James Tyson.

D. H., æt. 63, was a native of Ireland, who entered the Philadelphia Hospital on the 28th of January, 1874, completely unconscious. He is

said to have been feeling badly for some days, in the out-wards or alms-house department, but tried to conceal his condition to avoid coming to the hospital. He was suddenly seized with convulsions on the morning of the 28th, and was brought to the wards at half-past 10 o'clock A.M.

When Dr. Guitéras, the resident physician, saw him, his respirations were 28 a minute, deep, and the regularity of their rhythm was only interrupted every five or eight minutes by convulsions which began with twitchings of the left side of the face, and extended all over the left side of the body, shaking the bed under him, and at times also involving the right lower extremity. The respirations during the fit became jerking, his face purplish, and he foamed at the mouth. There was no œdema, no effusion into chest or abdomen. A full inspiratory murmur was heard over anterior of lungs. The pupils were normal, and responded to changes of light. He could not swallow. *His urine was examined, and found to contain about one-half of its bulk of albumen.* He then received a hypodermic injection of one-fourth of a grain of morphine, a few minutes after which he had his last convulsion. After this his coma continued. His bowels could not be opened by croton oil. Two more hypodermic injections of one-fourth of a grain of morphine were given, with the apparent effect of slowing his respirations down to 18 a minute, but they continued stertorous. His pulse, which before the first hypodermic had been frequent and not weak, became very hard and bounding, coming down from above 110 a minute to 100. At midnight tracheal râles began to be heard, and between 7 and 8 o'clock A.M. of the 29th he died, without any other change in his symptoms.

The urine for examination was drawn with a catheter. Not more than four fluidounces were found in the bladder. No more urine was passed, and the bladder was found empty on *post-mortem* examination.

No microscopic examination of the urine was made.

The symptoms for twenty-four hours before death were those of uræmia, a frequent cause of death in this most insidious form of renal disease,—contracted kidney.

Autopsy.—The kidneys are very small, not more than half as large as in health. They contain each fifteen to twenty superficial cysts, from a line to three lines in diameter, filled with transparent fluid, and each kidney contained one larger cyst which held a fluidrachm of the same fluid. Further, the cortical or convoluted portion of the organ is greatly diminished in area.

Examined by the microscope, the walls of the arterioles, which are brought out with great distinctness by means of acetic acid, are seen to be

twice and even three times as thick as in health, exhibiting quite the relative difference shown in Dr. Johnson's drawings, made from actual specimens. The concentric layers of connective tissue about the Malpighian bodies are here peculiarly distinct: so distinct and abundant is the fibrillation, so large and well-defined are the spindle-shaped connective-tissue corpuscles, that I cannot but think it affords evidence of the activity of the elements of connective tissue always sparsely present in the adventitia of the blood-vessels of the kidney, if nowhere else, and which must be admitted as one of the sources of the increased amount of fibrillated tissue present in this form of renal disease, but not the exclusive one.

Of equal interest in this connection is the condition of the heart. We may truthfully say it is enormously thickened. It weighs twenty ounces,* and the muscular walls of the left ventricle are twice as thick as they usually are in a healthy organ, while the valves are practically normal. There may be a slight degree of thickening of the mitral leaflets, but the valve is physiologically sufficient, and the condition resolves itself into one of pure hypertrophy of the left ventricle, which we believe to be due to the extraordinary efforts of the heart to overcome the resistance presented by the renal and general systemic arterioles through their hypertrophied muscular coat. *February* 26*th*, 1874.

---

3. *Tuberculosis of the kidney—Peculiar "worm-like" bodies from the urine of the same case.*

By Dr. R. M. Bertolet, for Dr. Thomas B. Reed, who gave the following history:

The pathological specimens just shown are from a patient of mine, A. B., aged 35, of American parentage, who came under my professional care some ten days ago, with an acute attack of nephritis. Always of comparatively robust health (father still living at sixty, mother died of some acute fever, one sister of acute tuberculosis of the lungs at an early age), having served throughout the war, he came first under my notice professionally in 1869, and was treated for several months for "stricture of urethra" (the result of gonorrhœa contracted in 1864, in the army) by gradual dilatation, from the finest "catgut" to a No. 19 bougie. Every four to six months since (1869 to 1874), I have passed a bougie, and I repeated

---

* Normal weight, ten ounces.

the operation some six weeks before his death. He was a man in mercantile life, whose business required him to travel a great deal; of correct and temperate habits, and, so far as I know, never sick until his last illness.

When called to see him, October 9th, he was suffering from fever of a malarial type, after a severe cold which he had neglected, and from wandering neuralgic pains over the chest and abdomen, and severe local pain over the kidneys. He was promptly treated by a mercurial cathartic, active local counter-irritation, dry cups, etc., over the lumbar region, full doses of quinine, and moderate diuretics, and for thirty hours he seemed decidedly improved. The urine was highly albuminous, sp. grav. 1130, but there was no apparent deposit until the 12th. On this day was observed an acute pleurisy developed posteriorly over both lower lobes of the lungs, more decided on the left side, and large effusion into the chest, which was greater on the right, with consequent oppressed breathing, and the tough, viscid expectoration specially characteristic of this complication. Simultaneously were noted a *peculiar blanching of the face* and a *failure of the circulation*, indicative of *hemorrhage*, and *most alarming*. This was late on the evening of the 12th. On examining his urinal on the morning of the 13th, very large quantities of cylindrical worm-like bodies, about one to two lines in diameter and from two and a half to three and a half inches in length, were discovered in the peculiar, smoky, dusky-red urine, which showed to the eye (as was soon confirmed by the microscope) positive and extensive hemorrhage from the urinary organs. He continued to pass these bodies in greater or less quantity during the remaining forty-eight hours of life. No treatment was of the slightest avail. He was freely stimulated with tonics and astringents, active diuretics and diluents, thorough counter-irritation, cups, etc. He died of exhaustion (loss of blood and compression of lungs) on the evening of the 15th. His mental condition was clear till within a few moments of his death. Relief by the aspirator would have been tried had there been the slightest probability of averting the result.

Post-mortem examination and notes by Dr. R. M. Bertolet.—The examination was made twenty-four hours after death, and was confined to the thoracic and abdominal organs. There were large effusions into the pleural cavities, with pleuritic exudations over lower lobes of both lungs, greater over the left. No evidence of tubercle in lungs. Liver apparently healthy; dark blood escaped from portal veins upon section. Mesenteric glands not enlarged. The bladder was contracted and empty; its mucous membrane and that of the right and lower half of left ureter presented no pathological lesions.

Left kidney moderately enlarged, of doughy consistence; its cortex smooth, yellowish-white in color, with clearly developed *stellulæ Verheynii* and injection of the Malpighian bodies,—the latter seen as red dots; nearly all of the medullary papillæ intensely congested, purplish in hue. Pelvis and ureter healthy. The thin capsule easily separated, and was covered with a stout layer of adipose tissue.

Right kidney somewhat larger and more congested, with the same alterations of the parenchymatous structure as noted in the opposite organ. But in addition there are seen disseminated at numerous points both in the cortical and medullary substances, also in the capsule itself, small round tubercular nodules of variable size and color. None of these tubercles have attained a size greater than that of a small shot, the larger ones having an opaque, yellowish aspect, while the smaller are gray and transparent.

The mucous lining of the pelvis is thickly strewn with granules, many of which have softened into continuous cheesy patches, forming large, irregularly-shaped ulcerations. The underlying connective tissue is greatly hypertrophied. There is extensive loss of substance of several of the central papillæ, the tubercular infiltration and ulceration extending upwards into the cortex.

The upper half of the left ureter is apparently filled with a clot half an inch thick. The mucous membrane of this portion of the tube is studded with minute gray tubercles. A more careful examination clearly shows that the clot has been formed not within the lumen of the tube, but by extravasations between the mucous membrane and the outer coats of the ureter.

Microscopically, both kidneys presented fatty degeneration of the renal epithelium, with slight hyperplasia of the interstitial connective tissue. The presence of giant multinuclear cells and lymphadenoid structure in the gray granules of the left kidney confirms the diagnosis of true miliary tubercle.

The softened cheesy foci (probably embolic) situated in the cortex, although only of the size of a bullet, evidently proved the source for the local infection, since the bladder and genito-urinary organs were not, as is usually the case in renal phthisis, involved in this instance.

Remarks.—The right kidney clearly showed erosion of some of the vessels of the kidney, with subsequent hemorrhage and rupture of wall and the pouring out and infiltration of the fatty and cellular tissue surrounding the pelvis of the kidney and ureter, forming a large, irregular mass which at first sight suggested the idea of malignant disease of the

organ. When the kidney was lifted from its bed, a large mass of coagulated blood was found lying in the retro-peritoneal region, amounting to several handfuls. Here, then, was the cause of the blanched face and failing circulation. From the eroded arteries and ruptured wall of the kidney his life-blood had slowly and silently ebbed away.

Some of the questions involved in the treatment and subsequent *post-mortem* examination of this case are of interest.

The hemorrhage and its cause are of special moment.

(1) Malignant disease (cancer) or traumatic injuries are the chief sources of hemorrhage from the kidneys. During life, and, indeed, until the determination of the question by the microscope, I was of the opinion that malignant disease (cancer) had suddenly been developed in this case. Tubercle in other organs—the lungs, for example—is not, *as a rule*, attended with hemorrhage, but, as in gangrene, seals up the vessels as it advances; and in looking up the authorities on the subject I do not find any mention made of hemorrhage as an element in any discussion of the subject of tuberculosis of the kidney.

(2) The presence of the cylindrical worm-like bodies, which were probably composed wholly of blood-corpuscles and fibrin, and the probable manner of their formation. There were three possible modes thought of. Aitken and Vogel state that "they have been seen, and are possibly formed by the passage of blood through the urethra." This, if it was passed slowly and through a stricture, might be a satisfactory explanation; but in this case no stricture existed, as a No. 19 bougie had been passed within a few weeks of death, and the passage of these bodies in great numbers at each act of micturition shows conclusively that they were formed before reaching the bladder.

Niemeyer, another author who mentions the subject, says "that they are sometimes formed in the *ureters*," but fails to state under what circumstances.

In the case before us this seems to me the most intelligent way to account for their formation. As stated in the *post-mortem* account, the hemorrhage which was poured out into the fatty and cellular tissue in and around the pelvis and the origin of the ureter *coagulated and formed a semi-solid mass encircling the ureter and very greatly contracting its calibre*, so that while surrounded by this mass *only a small-sized probe could be passed.* The blood poured out in the pelvis of the kidney made its way with difficulty and drop by drop through the stricture, and coagulated in the ureter below this point.

The third theory to account for their formation is in the straight or

collecting tubules of the kidney. The masses seem to me too large to be accounted for in this way; and yet the microscopic appearance of some of the specimens of Dr. Bertolet show what seem to be the branching tubules coming off from the straight tubules.

To his very able assistance in the *post-mortem* and microscopical investigation of this case, as well as in the discussion of the various theories and authorities on the subject, very much of the interest of the case is due.

Examination of urine and worm-like bodies by Dr. Bertolet.—The urine had a specific gravity of 1030, an acid reaction, highly albuminous, contained granular and blood casts, free blood-corpuscles, besides the numerous worm-like bodies seen floating in the reddish-brown-colored fluid. These worm-like bodies are more or less tortuous in outline and dark-red in appearance. Their average length is two inches, width one line and under. Very many of them end in a thin filamentous appendage, so tenuous as to be scarcely visible to the naked eye. A few of these terminal extremities, when examined microscopically, present a dichotomous appearance. These lateral branches are not due to any accidental folding, but seem to be in actual continuity with the main trunk.

Microscopically, these casts are made up of coagulated fibrin and blood-corpuscles. Renal epithelium is seen adherent at points along the minuter filaments only. The question at once arises, At what point were these remarkable casts formed? While the wider portions of them were unquestionably moulded in the constricted part of the ureter, the terminal parts are most probably casts of dilated straight tubules.

The adherent renal epithelium, the branched appearance, and the fact that sections of the medullary cones still reveal the presence of blood-casts in some of the tubules, while others are seen empty and deprived of their epithelium, lead me to regard the tail-like end attached to some of these worm-like bodies as being formed in the uriniferous tubules. That they should have been washed from thence and become adherent to the masses, plugging the ureter, seems to me no more improbable than that the clots should have been expelled from the latter site. Beale and other authorities state the diameters of the largest tube-casts to be from one five-hundredth to one two-hundred-and-fiftieth of an inch. Yet, upon considering the unusual and enormous pressure to which the uriniferous tubules of this kidney must have been undoubtedly subjected by the blood damming up into them, I believe that the finer portions at least of these worm-like bodies were formed in the straight tubules, and not in the ureter.

Dr. J. G. Richardson observed that to his eye the so-called "*branch*" of the cast shown by Dr. Bertolet presented the appearance of being a

narrow strip of the main stem, split or torn off the side for a short distance, instead of showing the character of a smaller cast from the lumen of some tributary tubule emptying into the larger stricture.

He further remarked that he had never seen a tube-cast larger in diameter than the one three-hundredth of an inch, and that the largest recorded by Beale was the one two-hundred-and-fiftieth of an inch; whereas the bodies presented by Dr. Bertolet were, when fresh, as thick as the one-sixth of an inch. He also thought that so large a dilatation of the uriniferous tubules as would be necessary for the formation of these bodies would be visible after death. Dr. R. suggested that the bodies might be formed in the ureter, whose walls are often in contact, and that the tapering form of the body might be owing to the fact that the farther from the immediate seat of hemorrhage the less would be the force of the blood and the smaller the quantity, so that a clot would gradually become narrower in its diameter as its extremity was reached. *October 22d*, 1874.

---

4. *Contracted kidneys and hypertrophied heart.*

By Dr. F. P. Henry.

The specimens of contracted kidneys and hypertrophied heart were taken from a girl æt. 17, who was admitted to the Episcopal Hospital on the 7th of December.

She presented the typical symptoms of chlorosis,—a greenish-yellow skin, pearly conjunctivæ, amenorrhœa, and a marked continuous musical murmur heard on applying the stethoscope over the course of the internal jugular vein. There was also a blowing murmur with the first sound of the heart, heard most distinctly at the apex.

Under the use of iron and quinia the girl steadily improved up to December 16th. At this time she became more feeble, lost her appetite, and complained of colicky pains in the abdomen. Her condition remained about the same until the evening of December 18th, when she became partially comatose, and died at midnight.

At the *autopsy*, ten hours after death, the *left ventricle* of the heart was found hypertrophied, and the *kidneys* contracted.

The *lungs* were perfectly healthy, as were also all the abdominal organs except the kidneys.

The cortical portion of the kidneys is atrophied, and the kidneys are

quite small; but it must be borne in mind that the patient furnishing these specimens was a remarkably small individual, not five feet in height, and weighing, I should say, under one hundred pounds when in an ordinary state of health, so that the small size of the kidneys may be more apparent than real.

This is believed to be a case of simple hypertrophy of the heart caused by contracted kidneys. *January* 15*th*, 1875.

---

5. *Cystic kidneys; obstruction by enlargement of the lateral lobes of the prostate gland.*

By Dr. W. H. Parish, for Dr. C. M. Harris.

A. F., æt. about 60 years, died January 10th, 1875. He was seen by Dr. Harris for the first time one day before death, and no history of prior condition could be obtained. When seen, he was suffering with pelvic and abdominal pains, and pain down each thigh. He died in slight coma, without convulsions.

Autopsy, January 11th, 1875.—There was general emaciation; slight atheroma of valves of heart. Lungs normal. Liver cirrhotic. Intestinal tract apparently normal. Prostate gland great enlarged and quite firm. Bladder contracted, walls much thickened and in a rugose condition; the openings of the ureters into the bladder were diminished in calibre. The ureters were examined only at their extremities; the upper extremities were dilated. Pelves of both kidneys dilated, as were the calyces of both. In the pelvis of the left kidney and upper portion of the left ureter were about two ounces of muco-purulent fluid.

The parenchyma of both kidneys was diminished in quantity, as if atrophied from pressure. *January* 15*th*, 1875.

---

6. *Soft cancer (encephaloid) of the kidney and of the lumbar glands(?).*

By Dr. James Tyson.

This specimen was removed from a farmer æt. 52 years. The case first came under my observation about eighteen months ago, as one of hæmaturia. The hemorrhage had first occurred in the spring of 1873, but for four years previous there were frequent attacks of lumbar pain, which

were at first attributed by the patient and his friends to lumbago. They were, however, periodical, and often of extreme severity, and he had actually once passed a small stone, which, from the description of a highly intelligent person who saw it, would appear to have been a mulberry calculus. With these facts before me, I was not slow in deciding that the case was one of impacted calculus, although the blood was copious, and there were sometimes coagula. The urine was, of course, highly albuminous, but a microscopic examination, made in August, 1873, revealed no casts. After he came under observation the hemorrhages remained absent for as much as four weeks at a time, but gradually became more frequent, as did the attacks of lumbar pain, which finally became continuous and extreme. The patient gradually became weaker and lost flesh, notwithstanding supporting treatment. Œdema of the right leg appeared, and subsequently extended to the left, and by Christmas, 1873, he was entirely confined to bed. Dulness was now apparent over the region of the right kidney, and the real nature of the disease was suspected, although before this the presence of incontinence of urine also led to the suspicion that the bladder might be involved, a symptom entirely explained by the condition of the spinal cord found *post mortem.*

He lingered, requiring the constant use of opiates to subdue the pain, until about October 23d, when he died.

The *post-mortem* examination was made by Dr. Hunsberger, of Blandon, Berks County, Pennsylvania, who kindly forwarded the specimens. They consisted of the bladder, two kidneys, and a portion of the tumor. The former organ appears to be healthy, but the left kidney is enlarged, while the right is converted into a trabecular connective-tissue frame-work, the interstices of which are occupied by the usual brain-like substance of soft cancer. The proper situation of this organ was occupied by a large tumor, extending down to the crest of the ilium and eroding the bodies of three or four lumbar vertebræ. Sections of the portion of the tumor sent were made, and found to present the microscopical characters of encephaloid or soft cancer. Pushed up to this tumor, and lying in contact with the stomach, to which it was adherent, was the right kidney, presenting the characters described.

The lungs and liver were the seats of secondary deposits.

A most interesting question in connection with the case is the relation of the large tumor encroaching upon the vertebræ to the cancer of the kidney. The history of the case would seem to point to the former as primary, but it is much to be regretted that the examination did not determine the exact seat of its incipiency.

Dr. Wm. Pepper said the specimens recalled a case which he had had the opportunity of watching several years ago, in the person of a young man of healthy family history. The lumbar tumor was on the left side, and to it the kidney was closely attached; but, while its ureter was somewhat compressed, the substance of the kidney was not actually involved by the disease. In this case the periodical character of the lumbar pain was so marked and so extreme as to lead, during the earlier period of the case, to the suspicion of aneurism, although other symptoms of aneurism were wanting. It, however, ran the same course as Dr. Tyson's case, terminating in paralysis and œdema of the lower extremities. There was no abnormal condition of the urine. The right kidney was healthy; the left was flattened and adherent to the lumbar tumor. Its ureter was constricted by adhesions, and the kidney somewhat sacculated in consequence. The mass proved to be a soft cancer of the vertebral glands. The vertebræ were eroded, and prolongations of the growth had extended through the foramina into the spinal canal, and the spinal cord was compressed and softened in its substance.

It is well known that cancer of the kidney is rare, and that changes in the urine are uncertain and inconstant. He had happened to meet several cases of cancer of the kidney which ran their entire course without marked changes, without hæmaturia, albuminuria, or peculiar cells in the urine. In other cases, again, there is the presence of albumen, more or less characteristic cells are found in the urine, while marked attacks of hæmaturia form a very important symptom. *January 28th*, 1875.

---

7. *Latent cirrhosis of kidneys without albuminuria or dropsy; hypertrophy of heart; dyspnœa; sudden death.*

By Dr. Wm. Pepper.

The patient was a young woman, æt. 27 years, whose appearance always indicated full health, with some tendency to plethora. It is not known that she ever had scarlatina, and no symptoms had ever attracted attention to the kidneys. For some years past, occasional dyspnœa had been noticed, which grew much more severe last fall, when it became constant, and much increased on exertion. She also had occasional violent paroxysms of orthopnœa, resembling attacks of spasmodic asthma, and usually at night, and, on several occasions, hæmoptysis occurred. The secretion of urine

was abundant, of light color, and rather low specific gravity; it was carefully examined several times, but no albumen or tube-casts were found. The breathing was very frequent, and there were frequently signs of marked pulmonary congestion. The action of the heart was habitually rapid, but was readily kept under control by moderate doses of digitalis. Physical examination showed a considerable degree of hypertrophy, chiefly of left ventricle. While under treatment, several severe nocturnal paroxysms occurred; and, finally, after having enjoyed an unusual degree of comfort for several weeks continuously, she was seized with symptoms ot intense dyspnœa soon after retiring one evening, followed in a few minutes by insensibility, purplish suffusion of face, and death.

At the *autopsy*, extreme cirrhosis of both kidneys was found; the organs being reduced to about one-third their normal size. There was intense venous congestion of all the abdominal organs. The *lungs* were deeply congested, but no apoplectic clots were found. The *heart* was much hypertrophied, the walls of the left ventricle being especially affected. The valves were competent, but the leaflets of the mitral were thickened and somewhat too rigid. The right ventricle was not much enlarged, and its full expansion seemed checked by a delicate band, which passed from about the middle of the septum to the outer wall. There were traces of old pericarditis. *March* 25*th*, 1875.

---

8. *Kidney from a case of hæmaturia in an infant.*

By Dr. Jos. G. Richardson.

The specimen, showing a curious natural injection of both the convoluted and straight portions of the uriniferous tubules with blood-casts, was sent to me by Dr. M. B. Wright, of Cincinnati, Ohio, for microscopical examination; the case being one in which supposed pigment-flakes were found in the urine, and, he believed, also in the blood.

Dr. Wright is preparing a paper in relation to a series of these cases which had occurred in his hospital wards, for the forthcoming volume of the Transactions of the American Medical Association, but has kindly permitted the exhibition of this specimen, and furnished the following brief history of this and similar examples of the disease:

"In three or four days, or longer, after birth, a dingy appearance of the (child's) surface is observed. A curdy exudation is scattered over the mouth, the urine becomes dark, and soon a black sediment, in more or less

quantity, is observed on the napkins. Some of the little patients have died within twenty-four hours, others have lived several days, and a few have recovered. The urine has been carefully examined chemically, with negative results merely."

I exhibit under the microscope a thin section cut in the axis of one of the pyramids of the kidney. By tinting the contents of tubules, in similar preparations, with aniline or iodine (according to my method for the diagnosis of blood-stains), I have been able to demonstrate, and even accurately measure, the red blood-corpuscles of which they were composed.

May 27th, 1875.

---

9. *Calculus, bladder, ureters, and sacculated kidneys.*

By Dr. W. G. Porter, for Dr. J. G. Allen.

The patient, a gentleman 76 years of age, when in New York ten years ago, was suddenly seized with an attack of retention of urine, which was relieved by the catheter in the hands of an eminent surgeon of that city. The catheter was passed without difficulty, but the attack of retention was followed by cystitis, which laid him up for some time. Since then he frequently has had attacks of retention, and whenever an instrument was used for the relief of the patient, cystitis followed, although the catheter was always used carefully and by skilful hands. He thus acquired such a dread of all instrumental interference that of late years he would not allow a catheter to be used, and when he had retention he would go to bed and use opium suppositories until the urine began to dribble away. During all this time he suffered more or less from increased frequency of, or difficulty in, micturition; and finally died during one of the attacks of retention, with the bladder unrelieved.

Post-mortem.—On opening the abdominal cavity, the distended bladder was found reaching about an inch and a half above the umbilicus, and uniformly adherent by its anterior surface to the abdominal wall. The adhesions were evidently not of recent formation; most of them were separated with some difficulty by the finger, some few bands requiring division with the knife. On opening the bladder, a large quantity of extremely ammoniacal urine escaped, and a calculus about the size of a walnut, weighing three drachms, was found; it was extremely rough and irregular on its surface, dark in color, and presented the appearance of what is known as a "mulberry calculus." The bladder was thickened,

enlarged, and its interior surface was excessively ribbed. The prostate gland was very much hypertrophied, particularly its third lobe. The ureters were much enlarged and distended with urine. The left kidney was a mere membranous bag, containing urine, none of the secreting structure of the kidney apparently remaining. The right kidney contained a large cyst. *April 9th*, 1874.

The stone was referred for analysis to a *special committee* consisting of Drs. Porter, Isaac Norris, and Hare, who reported as follows:

"The committee to whom was referred the chemical nature of the calculus exhibited at a stated meeting of the Society, would report that it is of the variety known as the mulberry calculus, and consists principally of calcium oxalate. Externally it presents the usual warty character, stained with blood, and is exceedingly hard. Before the blowpipe it is converted into a carbonate, and finally into lime. It dissolves in hydrogen chloride aided by heat, and more readily in hydrogen nitrate, and gives with the spectroscope the characteristic orange and green lines with the purple band in the more refrangible part, and with the liquid tests the usual reactions for a calcium salt. The presence of oxalic acid is also shown when boiled with potassium carbonate and the whole neutralized with an acid and a soluble lime salt added. All of which is respectfully submitted, and the committee ask to be discharged." *May 28th*, 1874.

---

10. *Vesical calculus of small size, producing marked symptoms.*

By Dr. John Ashhurst, Jr.

The calculus weighs less than two grains, and was removed by lateral lithotomy, from a boy, one week previously. The symptoms of stone in the bladder have existed only about three weeks, but have been unusually severe, several attacks of complete retention of urine having occurred, and the violent straining during one of these attacks having caused rupture of a blood-vessel in each orbit. The stone appears to be of the uric acid variety, and there were evidences of renal calculus before the development of vesical symptoms. Entire relief has been afforded by the operation.

May 27th, 1875.

b. FEMALE ORGANS OF GENERATION.

11. *Ovarian tumor.*

By Dr. H. Lenox Hodge.

The tumor was removed by Prof. Agnew, from a patient 33 years of age, married, and the mother of two children. It was first noticed in January, 1873; since then it has steadily increased in size. She was tapped in December, and again in January. The tumor is multilocular, and weighed eighteen pounds, solid and fluid. The microscopical examination has been made by Dr. Richardson. *February* 12*th*, 1874.

---

12. *Ovarian tumor removed by ovariotomy.*

By Dr. H. Lenox Hodge.

The operation was performed this morning. The patient is 29 years of age, and has suffered from the tumor for about eighteen months. She was tapped last May, and one large cyst emptied. This was followed by partial relief. During the summer the fluid reaccumulated, and before the operation she measured two inches more around the abdomen than she did before the tapping.

The tumor is of the multilocular form, and belongs to the right ovary. The left ovary was healthy. On account of the thick character of the contents of many of the cysts, and the large amount of fibrous structure, it was requisite to make the abdominal incision ten inches long, extending about one inch above the umbilicus. The patient has reacted well, has no pain, and rests very comfortably this evening. *September* 23*d*, 1874.

---

13. *Ovarian tumor of the left ovary, and a tubal dropsy of the right Fallopian tube.*

By Dr. H. Lenox Hodge.

The specimen was removed at the Presbyterian Hospital from a woman who has suffered from ovarian dropsy for about two years and a half.

She has been tapped eight times by different practitioners, and was ad-

mitted into the hospital three weeks after the last tapping. She died on the second day after her admission, in a faint upon rising to have a stool.

Upon making the examination, the uterus was found lying in front of the tumor, flattened and extending three-fourths of the distance to the umbilicus. The uterus was also elongated so as to measure six inches. The tumor extended to the margins of the ribs, and consisted of one large cyst, with a few small ones in the exterior portions of the wall. The large cyst was filled with a thick purulent fluid, with numerous large flakes of fibrinous deposit. Upon its interior were a number of inflammatory growths. The smaller cyst had not suppurated. This tumor was on the left side. The right ovary was healthy, and exhibited a recent *corpus luteum.* The right Fallopian tube was much elongated, tortuous, and its diameter enlarged, especially towards its fimbriated extremity. This extremity extended far beyond the ovary, and was not in direct connection with it. At the extremity of the tube there was a sac filled with a dark-colored fluid, containing a small quantity of albumen, and communicating freely with and constituting part of the Fallopian tube. The fluid could not be forced along the narrow part of the tube into the uterus.

There was recent local peritonitis, and there was cirrhosis of the liver.

The special points of interest in this case to which I desire to direct the attention of the Society are inflammation of an ovarian cyst following tapping; the existence of distinct tubal dropsy; the microscopical and chemical characteristics of ovarian and tubal dropsies.

September 23*d*, 1874.

Report of Committee on Dr. Hodge's specimen:

"The committee appointed to examine the specimen presented by Dr. Hodge at the meeting of the Pathological Society held September 23d, 1874, report that they have carefully examined the specimen, and find that the tumor was an ovarian tumor attached to the broad ligament by inflammatory adhesions.

"H. Lenox Hodge,
"J. Ewing Mears,
"John S. Parry."

---

14. *Fluid removed from a cyst of the broad ligament.*

By Dr. H. Lenox Hodge.

The specimen was taken from a woman 52 years of age, who had suffered from the swelling for four years. On October 9th, I tapped her,

and removed ten quarts of this colorless, transparent, thin fluid. It is slightly opalescent, and looks like pure spring-water. Its specific gravity is 1004, and it does not coagulate on boiling. Upon standing it has become less clear than at first, and a thin pedicle has formed upon its surface. Under the microscope, Dr. Richardson reports that the field is free from objects.

There is a property which I think this thin fluid possesses, and to which I wish to direct the attention of members of the Society, namely, *its power of transmitting sound.* Upon auscultating the abdomen of this patient, the gurgling of the intestines could be distinctly heard in front where the sound on percussion was dull. In other cystic dropsies of the abdomen I have not noticed this symptom. It may possibly prove of value in detecting the existence of cysts of the broad ligament and in distinguishing them from other collections of fluid. Their diagnosis prior to tapping is somewhat difficult, and anything that will aid in recognizing them is of value.

October 22*d*, 1874.

---

15. *Ovarian tumor.*

By Dr. F. P. Henry.

This specimen of ovarian tumor was removed *post mortem*, but is none the less interesting pathologically on that account. The patient from whom it was obtained was admitted to the Episcopal Hospital on February 2d. Her abdomen was enormously distended. She had been tapped about two weeks before admission, for the eighteenth or nineteenth time, when, according to her statement, four pailfuls of fluid were removed. Fluctuation was easily obtained all over the abdomen, which was evenly distended.

She first noticed a swelling in the hypogastric region at the time of the menopause, about three years ago. She was tapped February 18th, and two and a half bucketfuls of a fluid of the consistence and color of syrup of acacia were removed. Before the tapping the circumference of the abdomen was sixty-one inches. After a quantity of the fluid had drained away, a large tumor was felt in the right side of the abdomen, extending from the ribs to the iliac region. Her attention was called to it, and she then said that she had discovered it some months before, after one of her numerous tappings, and had called the attention of her physician to it, whereupon he pronounced it to be the liver.

The tapping only reduced the woman's girth six inches, but was followed by great relief.

Having decided the case to be one of ovarian tumor, which opinion was confirmed by the attending surgeon, Dr. Forbes, arrangements were made to have the woman transferred to the surgical side of the house. On February 25th she was informed of the proposed change, at which she was greatly agitated, and declared that she could never survive an operation. At this time she was in her usual state of health, but she grew worse towards the afternoon, and died the next morning about ten minutes before my visit to the hospital. Dr. Merrill, the resident physician, said there was some dyspnœa preceding death.

At the *post-mortem* examination it was only possible to examine the abdomen, and that only because it was impossible to get the body in the coffin without reducing its size. The large cyst was adherent to the anterior wall of the abdomen. There was some recent lymph upon the intestines, and the tumor felt during life was found free on the right side. The heart was not examined, and so the cause of death cannot be pronounced upon with certainty. My opinion is that it may have been from heart-clot of gradual formation. The heart-sounds were feeble, but there was no valvular murmur, and the urine did not contain albumen.

March 11*th*, 1875.

---

16. *Medullary carcinoma of the left ovary.*

By Dr. J. Ewing Mears, for Dr. W. W. Keen.

History by Dr. W. W. Keen.—Mrs. A. S., æt. 46, of West Chester, was sent to me May 1st, 1875, by Dr. McClurg. She began to menstruate at 15, and ceased at 44; was always regular, and did not usually suffer much pain. Married at 19, and her only child was born one year later. Has never had any uterine trouble. Her general health has been good until within two years. She first observed a swelling just above the right groin, about two years and a half ago, but it was not painful. In September last, after lifting a heavy basket, she observed that it had changed its place to the middle line. She had at that time considerable abdominal pain, and was sick some three or four weeks, but was not in bed. In October last, Dr. McClurg tapped her and removed five gallons of a greenish, viscid fluid, the operation being followed by considerable peritonitis. Her health was better after she was tapped, but the abdominal swelling again increased considerably. Of late she had not suffered much pain, but, from general discomfort, life was becoming a burden.

May 1st, 1875.—On examination, she is seen to be a thin, spare woman. Her abdomen measures, from the ensiform cartilage to the umbilicus, six inches; thence to the pubes, nine inches; between the iliac spines, sixteen inches; and the greatest abdominal girth, a little below the umbilicus, is thirty-three inches. The swelling is almost wholly below the umbilicus. A considerable amount of ascites is readily recognizable, beneath which the tumor is distinctly felt. The anterior parietal adhesions are limited to two irregular spots of about three inches square, the one surrounding the point of tapping, the other below it, and corresponding to a hard mass. The ascitic fluid flows around these adhesions, and reveals them easily. No adhesions existed laterally to the abdominal walls. The whole mass was, however, movable with difficulty either from side to side, or from below upwards. Palpation showed that the upper part of the tumor was distinctly cystic; the lower part, however, was solid. Anteriorly there extended from the pubes, obliquely to the right, a mass feeling somewhat like an elongated, irregular uterus; but the later examination of the uterus made it very doubtful that this was the uterus.

The vaginal examination showed the os and cervix in about their normal position, size, and relations. The tumor could be felt behind the womb, but the cervix did not fade into the tumor, for a depression existed between them. The sound entered the uterine cavity upward, and somewhat to the right, two and a half inches.

The uterus was scarcely movable at all independently, and movement of the tumor communicated motion to the uterus. The tumor could also be felt by the rectum, and its general pelvic examination left no doubt that the pedicle was very short and the adhesions probably pretty firm, but not very extensive.

May 20th.—By the aspirator I drew off a small quantity of the fluid for examination. I punctured the cyst through the adhesions, so as to avoid the peritoneal cavity. The fluid was purulent-looking, and showed on examination some compound granular corpuscles and a few blood- and pus-cells; but the morphological element was mainly the distinct ovarian cell.

May 22d.—The tumor was removed at St. Mary's Hospital, in the presence and with the assistance of my colleagues, Drs. Grove, Schell, and Mears, and Drs. McClurg, Stewart, Porter, Griffith, with several others. After tapping the main cyst I found that the lower mass was too solid for any further diminution in size, and my incision had to be extended from the umbilicus six and a half inches downwards nearly to the pubes, to admit of its removal. The parietal adhesions were easily broken up; a few were found above and behind, to the intestine and omentum, and the mass was

then turned out of the abdominal cavity. It was so large and solid that it hid everything below its mass, and I was obliged to tie its large base with a stout ligature, and then remove the greater part of the tumor at once, by cutting through its substance. Having done so, the base of the tumor (for it could not be called a pedicle) was found to be attached directly to the uterus, the rectum, and the left side of the pelvis. The parts of the tumor which had been left were now removed. Three large stout ligatures were passed around the broad attachments, two at the uterine and one at the pelvic attachments. These secured some large vessels. Considerable trouble was caused by these vessels and numerous smaller ones, so that eight ordinary ligatures were required. These were cut off short, but the three large ones were brought out of the abdominal wound. The attachments were touched with Monsel's solution, and the wound was closed by eight silver-wire sutures. The operation lasted two hours.

The tumor consisted in its upper portion of one large cyst, containing about four pints of fluid like that before described, besides two or three quite small cysts. The inner surface of the large cyst was coated with soft, almost grumous papillary growths, numerous detached masses of which made up a sediment in the fluid. The lower part was quite a hard solid mass, divided by distinct septa of connective tissue into smaller masses, which could be peeled out of their loculi. These smaller masses were whitish in color, and again subdivided into still smaller similar masses.

She was placed in bed with some hot-water bottles, though she was not very cold, and one-fourth grain of morphia was given hypodermically. In a short time she became conscious, and reacted well, though vomiting occurred occasionally. Nothing was given for three hours, but then beef-tea and milk-punch in small quantities were given every hour. Her pulse in the evening was 124, and temperature 101.2°. Another one-fourth grain of morphia was given to produce sleep. She suffered no pain.

May 23d.—In the morning her pulse was 126; temperature 100.8°. She had not slept any, had rejected the beef-tea utterly, but retained the punch. There was no pain, but the belly was a little tender. She passed a small quantity of water. Her general condition was much depressed. I continued the punch and ordered broken ice and a cup of iced tea.

In the evening her pulse was 144, and very weak; her temperature 101.8°; her belly tender. A little oozing of bloody serum had taken place during the day. She was bathed in perspiration, was restless and despondent. From this time she gradually sank more and more, and died at 8 A.M. the next morning, May 24th.

Autopsy, May 24th, at noon.—The wound was well united throughout, except where the ligatures emerged. At each ligature there was a little pus. The intestines were all glued together with lymph of recent formation below the level of the umbilicus. At this level the omentum was attached to the belly-wall transversely, and divided the main peritoneal cavity into two parts. In the upper the evidences of old inflammation and its resulting adhesions were seen; in the lower the recent inflammatory changes, the results of the presence of the tumor and the operation. No hemorrhage had occurred after operation.

The uterus and right ovary were removed, with a portion of the rectum. The tumor was found to have been attached to nearly the whole of the left half of the uterus laterally and posteriorly, and to the rectum in Douglas's cul-de-sac. From this rectal attachment and deep on the posterior surface of the uterus the troublesome hemorrhage had taken place, and also from the pelvic attachment of the left broad ligament, which was the pelvic attachment. The right ovary was somewhat enlarged, and had contracted some adhesion to the pelvis.

All the specimens are deposited in the Museum of the College of Physicians.

Dr. J. G. Richardson kindly examined the specimens for me, and reports as follows:

"Scraping the surface of a fresh incision into the ovarian tumor you left with me yielded an abundant milky juice, containing multitudes of rounded, oval, caudate, and multiangular cells, with large nuclei. Thin sections from the growth exhibited similar cells heaped together in the alveoli of a loose but rather abundant stroma, the individual cell-elements being without intercellular substance. The tumor seems, therefore, to be a rather hard variety of encephaloid or medullary carcinoma.

"The right ovary contained a dark-brown fluid, in which compound granular corpuscles, plates of cholesterin, and 'Drysdale's ovarian cells' were abundant. Its internal wall, on incision, displayed a peculiar plicated arrangement, strikingly analogous to that of the *corpus luteum* of pregnancy."

Dr. Mears said he had examined the fluid and did not find in it the so-called ovarian cell in such numbers as Dr. Keen. He thought he had at times been able to diagnosticate cancer of the ovary by examination of fluid drawn from the abdomen. In this case, however, he was unable to do so, but had concluded that this was a multilocular cyst, in which suppuration had occurred. The discovery by Dr. Keen of the so-called ovarian cell in such large quantities in the fluid derived from this case by tapping, would

seem to deprive this cell of its pathognomonic character, since the specimen is pronounced by Dr. Richardson to be a true medullary cancer.

Dr. Bertolet said that he would refrain from saying anything about the so-called "ovarian cell," as being a matter still held *sub judice* by a special committee of this Society, but he thought that, as a scientific body, it was wellnigh time that we should drop allusions to and discussions about "cancer-cells," of which such frequent mention had been made. Cancerous tumors could not be diagnosticated by simply examining the juices or rough scrapings, but could only be recognized by careful section and examination of the cells in relation to the stroma. The mere presence of a greatly and variously altered epithelium did not suffice to distinguish a carcinomatous growth from a benign adenoma; and many other species of tumors, like a simple retention-cyst, may present us with as many varied forms of cell-growth. The alveolated connective-tissue stroma is as important a factor as the "epithelial" element; either one, without the other, can never constitute a carcinoma. "Cancer-cells" are things of the past, and by us, also, should be irretrievably consigned to oblivion.

Dr. Mears said he would like to ask Dr. Bertolet whether or not it was possible to diagnosticate cancer by examination of products obtainable during life.

Dr. Bertolet replied that it was formerly alleged that cancer of the kidney could be determined by the presence in the urinary sediment of cells derived from the *débris* of the breaking-down growth. These various forms of cells—atypical epithelium—have now been abandoned as worthless for the diagnosis of renal cancer. Occasionally, it is true, fragments are discharged so large as to permit the recognition of an *alveolar structure*, when teased or cut in thin sections; but very often even such fragments are so far advanced in the necrobiotic process as to preclude such a recognition.

Dr. Mears said he could recall at least one instance in which he had examined the fluid drawn from the abdomen and concluded that the case was one of cancer of the ovary. He was present at the operation, and presented the tumor to this Society. The specimen was referred to the Committee on Morbid Growths, and reported by them to be one of cancer. He was not as yet a believer in the existence of pathognomonic ovarian cell, and in the discussions in this Society he had expressed his disbelief in the existence of a distinctive cancer-cell. He fully recognized that the only proper method to determine the character of growths was to examine them in section, in order to study the relation of the cells to the stroma, but he felt sure that he had at times observed differences in the fluids in

cases of ovarian disease which caused him to declare that the growth was not an ordinary cyst of the ovary, but a cancer.

Dr. John Ashhurst, Jr., said that he thought that in our zeal for modern methods of investigation (the excellence of which no one could be more ready to admit than himself) we should not overlook the circumstance that cancer had, as a matter of fact, been frequently recognized in past years by the examination of scrapings, or of the so-called "cancer-juice," and that the investigations of Paget and other eminent pathologists had been almost entirely conducted in this way. While no one at the present day probably believed that there was any definite "cancer-cell," yet he thought the existence in any particular specimen of a great variety of cells of different sizes and characters, and of multifarious shapes, furnished probable, though not certain, evidence of the presence of cancer. It must be remembered, too, that even with the modern method of examining thin sections it was not always possible, without repeated examinations, to determine whether a given growth was of a carcinomatous or a sarcomatous nature, the same tumor, perhaps, presenting in most parts cells in constant relation with an intercellular substance (sarcoma), and yet, in certain places, nests of cells without any intercellular substance, when the growth would have to be called a *carcinomatous sarcoma.* Hence, while fully agreeing with Dr. Bertolet as to the superiority of the modern mode of studying the minute anatomy of tumors, he thought that, nevertheless, some information of practical value might be gained by examining scrapings or expressed fluid, and that it was not at all unreasonable, therefore, to suppose that a microscopic examination of the liquid removed by tapping might afford ground for a probable, though doubtless not a positive, diagnosis of cancer.

Dr. Joseph G. Richardson said that he had now in his possession specimens of the discharge from a case of tumor under the jaw showing characteristic pearly globules by which he was enabled to make a diagnosis of epithelioma, without any examination of sections from the growth.

Dr. James Tyson said he had recently more than once stated that in our modern methods of study of morbid growths he feared that the cell itself was being too much overlooked. Certainly no one would accuse him of claiming the existence of a specific cancer-cell; but at the same time, having had some experience in the older methods of scraping and dissecting, as well as the more modern of hardening, staining, and section, he felt that there were certain peculiarities of the cells of cancerous growths considered *in toto*, the presence of which alone justified more or less suspicion of malignancy, in a clinical aspect, at least. These characters had

been well described by his friend Dr. Ashhurst, and need not therefore be repeated. To those named might also be added the large numbers of nuclei, and the large size of the nuclei in relation to that of the cells themselves. Dr. T. did not wish, however, to be considered as advocating a study of the cells only, in making the diagnosis of cancer, but thought that both methods should be combined.

With regard to cancer of the kidney, he had to say that in a very large number of examinations of urinary sediment from cases of suspected cancer, and in some of which cancer was found to exist after death, he had never met any cellular or other elements whence the presence of this disease could be suspected. At the same time, he thought it not impossible that, in the disintegration of the organ, portions might descend to the bladder, which would aid or confirm a diagnosis, and he saw no reason to doubt the accuracy of observation by such observers as Beale, Hoffmann and Ultzmann, and others bearing on this point.

Dr. Richardson thought it might at least be said that while the cellular elements in normal tissues grow according to a law of uniformity, those lying closely apposed resembling each other so long as constituting the same tissue, the cells of cancer grow in a *lawless* and irregular manner, resembling those of various other tissues as well as those in which they happen to be seated.*

Dr. Bertolet thought that if Dr. Ashhurst were to have plunged his trocar into the cavity of the tumor of the breast which had been this evening reported by the Committee on Morbid Growths as a cysto-sarcoma, he would have drawn out many epithelial elements, while the chief mass is in reality a sarcoma. In fact, the contents of the large cyst had been examined microscopically, but were found to be mostly epithelium, and so destitute of any characteristic features that no allusion to their appearance was deemed called for.

Dr. Pepper referred to the interesting question of the microscopic appearances in the urinary sediment in cases of cancer of the kidney. He had had the opportunity of carefully examining the urine in quite a num-

---

* [I have sometimes illustrated to my students the nature of this *lawless growth*, which I conceive to be so important a characteristic of the cells of cancer (as distinguished from Lebert's cancer-cell), by comparing it to that manifested in the development of the fungus producing the "smut" of our Indian corn. The relation held by the huge, distorted, ugly, and *lawlessly-growing* diseased grains to healthy grains evenly ranged in a ripe ear of corn, is strikingly analogous to that subsisting between the large, deformed, and *lawlessly-growing* cells of carcinoma, and the equal, symmetrical, and regularly-arranged cellular elements of normal tissue, as, for example, the mammary gland, which the malignant tumor may invade.—J. G. R.]

ber of such cases, and had found the results most uncertain. The great variety of form and size of the cell-elements derived from the epithelial lining of the urinary passages (perhaps especially from the bas-fond of the bladder) simulate at times the cell-forms of carcinoma, and on several occasions when the autopsy showed merely pyelitis, suspicion of cancer of the kidney had been aroused in this manner. On the other hand, in cases of undoubted renal carcinoma the microscopic study of the urinary sediment gave entirely negative results.

It would seem as though much of this discussion turned upon the precise classification adopted for tumors and neoplasms. It is of course well known that this has varied much at different times, and notably since the earlier writings of Paget. There can be no doubt that the latter observer and others of his school very frequently made a correct diagnosis of cancerous growths, so called under their classification, because the character of the expressed juice and particularly the cell-forms it contained formed an important feature in the characteristics of a cancer. But at the present time there exists an almost unanimous disposition to accept the classification of recent writers, in which cancer occupies a perfectly definite place, not in the least dependent on the character of juice that can be expressed from a cut surface, nor on the cell-forms present, but upon certain definite anatomical relations and arrangement of cells and intercellular stroma. According to this latter view it is, of course, necessary to employ the mode of examination which will alone afford a demonstration of these relations; and it is evidently impossible that a diagnosis can be made from the examination of fluid. It would seem that, with this conception of the question, the assertions made by Dr. Bertolet were well founded.

May 27th, 1875.

---

17. *Cancer of the uterus.*

By Dr. John H. Packard.

The specimen was derived from a woman aged 49, whose history has been published in the *American Journal of the Medical Sciences* for July, 1874, as "*A Case of Lumbar Colotomy for Obstruction of the Rectum by Cancerous Tumor of the Uterus.*" The object of the operation was the temporary relief from the obstruction, and by its means much comfort was secured to the patient while she lived, which was thirty-four weeks.

When I first saw the patient her vagina was filled with a growth, and

an examination of the uterus by the speculum was difficult, on account of the extreme vascularity of the mass distending the vagina. On introducing the finger into the rectum, it was arrested in a short time by a mass which appeared to block up the pelvis and make any further examination of the pelvic organs difficult. The operation of lumbar colotomy was performed, to relieve her from the effects of impaction of the fæces. I am unable to say whether the cancer originated from the pelvic organs or the vagina. *November* 12*th*, 1874.

Report of the Committee on Morbid Growths:

" Your committee find the tumor presented by Dr. Packard distinctly alveolated, therefore carcinomatous. Long club-shaped cylinders filled with epithelial cells are seen permeating the muscular layers in every direction: hence the variety is *epithelial carcinoma* or cancroid.

" The same histological features are possessed by the rectal masses and those strewn throughout the body of the uterus and appendages. Greater part of the cervix has been destroyed; whether it or the rectum was the primary seat of the disease remains to be decided upon by the special committee." *December* 11*th*, 1874.

---

18. *Fibroid tumor of the uterus.*

By Dr. James Tyson, for Dr. Francis L. Haynes.

History by Dr. Haynes.—Mary M., aged 32, was treated for uterine disease in 1873, at the University Dispensary; among other means, sponge tents were employed. Receiving no benefit, she discontinued treatment for a time, and finally came under my charge in October, 1873. A subperitoneal fibroid was detected by bimanual palpation. Under the internal administration of fluid extract of ergot, the flooding (which was her principal symptom) rapidly diminished, and in a short time she considered herself well. Examination revealed no change in the fibroid.

The patient was now lost sight of until June 5th, 1875, when I was called to attend her, and found her in a collapsed condition, and suffering from intense abdominal pain, with constant vomiting. A strangulated inguinal hernia was discovered. She had been treated for " cramps" by a homœopathic physician for eighteen hours previously. The hernia was reduced, and one-half grain of morphia given hypodermically. The vomiting and pain immediately ceased, but the patient never reacted, and died after twenty-four hours' illness.

On *post-mortem* examination, the intestines were intensely congested, and presented a pinched appearance at one point, showing the site of the hernia. About four ounces of bloody serum were found in the pelvic cavity, with other evidences of local peritonitis. The fibroid tumor had evidently increased in size since 1873. The right Fallopian tube was dilated at its extremity, where it presented a small opening, from which was issuing a fluid of a tarry appearance.

It was impossible to learn the immediate previous history of the patient; but it was known that she was menstruating at the time of her death.

June 24th, 1875.

---

19. *Epithelial tumor of the vagina.*

By Dr. J. Ewing Mears.

The patient is aged 35 years, is a native of England, and has been married eight years. She has never been pregnant, and menstruation is in every respect normal.

During the last fall and winter she was treated for ulceration of the womb, and was relieved. Her attention was first directed to the growth in the vagina by a hemorrhage which occurred in May last. Hemorrhages, more or less severe in character, have occurred from time to time, for the relief of which she has used styptic injections. Her general health has been good, and she has been able to perform her household duties without interruption.

On making a digital examination, an irregular, soft mass could be distinctly felt occupying the posterior wall of the vagina. It was situated at a point corresponding to the junction of the upper with the middle third of the canal. The growth was sessile, the attachment measuring in its long diameter about an inch, and transversely about an inch and a half. Between the mass and the os uteri the wall of the vagina was smooth and entirely free from any morbid growth. The os tincæ was normal, and free from disease.

On introducing a Sims speculum, the tumor could be easily examined, and presented to the eye the appearances described above.

Slight hemorrhage followed the digital examination and was readily checked.

In removing the tumor, an attempt was made to accomplish this by means of the wire écraseur: owing to its soft, spongy, character, this was

not successful. A hooked periosteal elevator was then employed, with which and the finger-nail the entire mass was removed, leaving a smooth surface on a level with the vaginal wall. Hemorrhage was not copious. After thoroughly cleansing the vagina by injections of water, pledgets of lint saturated in Monsel's solution of iron were introduced, which effectually checked the hemorrhage; after the expiration of twenty-four hours these were removed, and the surface was found coated with scales formed by the styptic. In a few days these were removed, leaving a small healthy-looking raw surface.

This case seems to possess one or two features which it may prove of interest to the Society to consider. At first, guided by the history of the case as presented, I was disposed to regard this growth as a papilloma of the vagina, and in view of this fact had prepared to encounter more difficulty from hemorrhage in effecting its removal. I was struck, therefore, by the comparatively slight amount of bleeding which occurred, and at once concluded that I had to deal with a pure epithelioma. Subsequent microscopic examination confirmed this conclusion, since there was an entire absence of the dendritic growths which characterize the papillary or villous form of cancer. Large quantities of variously-shaped nucleated cells, many containing granules and a delicate stroma, were all that could be seen in a number of portions which were examined.

It has occurred to me that this possibly may be one of those instances in which there has been a transition of papilloma into epithelioma as noted by Rindfleisch. This belief is founded solely upon the statement as to the free hemorrhages which occurred in the early stages of the disease.

The extremely rapid growth of the tumor is proven by the statement of the physician by whom the patient was treated for cervical endometritis, and who assures me that three months ago there was not a sign of any morbid growth in the vagina. It is interesting to observe that, so far as the records of this Society furnish evidence, and also from the statements of several physicians and surgeons with extended experience in the treatment of the surgical diseases of the female generative organs, who have been interrogated, primary cancer of the vagina is not of very frequent occurrence. The volumes of Transactions of this Society published, now three in number, do not contain the report of a case. During the past two years two cases have been reported to the Society,—one by Dr. Parry, and one by myself. *June 25th*, 1874.

20. *A case of atresia vaginæ.*

By Dr. H. S. Schell.

On the 2d instant an Irishwoman named Mary G. was admitted to St. Mary's Hospital, on account of a painful tumor of the abdomen. She was 30 years of age, and had been married five years. The hypogastric region was filled with a round body about the size of the womb in the fourth month of pregnancy.

From this mass an oblong tumor, about six inches long by two and a half inches broad, extended obliquely into the left lumbar region, and was movable from side to side to the extent of a couple of inches. Both of these bodies were rather hard, tense, and elastic. The patient stated that she had never menstruated, but that she had suffered from abdominal pains at monthly periods for the last twelve years. She had noticed the tumor for the last five years only. She was now scarcely ever entirely free from pain, and she anticipated the monthly exacerbation in a few days after her admission. On attempting to make a per vaginam examination, it was found that the canal was apparently somewhat in front of its usual position. It grasped the forefinger closely, and curved round immediately behind the os pubis. It was dilated at its upper part about the tip of the finger, but no os uteri could be felt.

The tumor was encountered at two and three-quarters inches from the external orifice. The rectum was large and flaccid. It dilated, immediately after passing the sphincter, into a sort of pouch. Its anterior wall was in contact with the perineum, the apparent vagina, and the base of the tumor, and, finally turning off to the left, was lost to the touch.

Visual inspection of the external organs of generation revealed well-formed labia, nymphæ, and clitoris. No normal urethra could be found, but when the finger was withdrawn from the anterior canal it was followed by a few drops of urine. The perineum was unmarked even by a dimple. When a finger was introduced into the anterior canal, and another into the rectum, there was evidently only the thickness of the walls of the two passages between them. No fibrous cord could be detected, and the coats of the two canals could be made to glide upon each other to some extent.

It seemed to me probable that this was a case of absentia vaginæ; that the large tumor consisted of the uterus distended with retained menses, and that the movable offshoot might be a Fallopian tube enlarged from the same cause.

On the 7th instant, at the probable monthly period, the woman suffered such extreme pain in the tumor that it was found necessary to resort to the hypodermic use of morphia to render her condition tolerable. As she was exceedingly anxious to be relieved, I proposed to make a vagina by incision in the perineum and careful dissection of the urethro-rectal septum, and to let out the retained menses.

On the 14th, a week after the monthly period, in consultation with Drs. Keen and Mears, it was decided to etherize the patient, and make, if possible, a more thorough examination before operating. The woman proved to be very refractory to the influence of the ether, and the consumption of a pound only produced incomplete anæsthesia, during which she made violent expulsive efforts. In one of these, a large portion of the tumor, about the size of a child's half-born head, was forced for a moment through the anus.

During the examination, the length, large size, and natural appearance of the anterior canal produced some doubts as to the correctness of the previous diagnosis. It was thought that it might be a common duct for the bladder and uterus. To this uncertainty was added the fact that the proposed operation was of a delicate character, and a fatal result from it not impossible. Under the circumstances it was decided to use the aspirator,—1, to ascertain the nature of the contents of the tumor; and 2, if found to be menstrual fluid, to relieve the uterus of most of it; and to make the proposed dissection at some future day, if thought desirable.

The puncture by the aspirator was accomplished through the rectum by means of the smallest needle, and two or three drachms of thick, slimy, red fluid removed.

It was then found that the joint between the needle and the rubber tube was not quite air-tight, so that the fluid could only be withdrawn slowly and with great difficulty. The needle was therefore removed from the tumor, with the intention of having the instrument made perfect and of taking away the rest of the fluid in a few days. The next morning, however, found the patient laboring under a violent attack of general peritonitis, which resulted fatally, in spite of treatment, on the evening of the 16th.

A *post-mortem* examination, made the following day, showed that the peritonitis had been caused by the diffusion throughout the abdominal cavity of the menstrual fluid previously contained in the tumor. What remained of the hypogastric tumor was now a flaccid, nearly empty sac, capable of holding about a quart. It proved to be the occluded and distended vagina. Its walls were one-fourth of an inch in thickness, except

in the Douglas's cul-de-sac, where for a couple of square inches they were thin as paper. In the lower part of this attenuated region the fatal rupture had taken place, the rent being only large enough to admit an ordinary probe.

The body in the left lumbar region was found to be the hypertrophied and elongated uterus. It measured five inches long by two and a quarter inches broad. Its interior was divided into two unequal cavities, of which that of the neck was perhaps treble the capacity of the body. The walls of the organ varied in thickness from three-fourths of an inch in the body to half an inch in the cervix. The cavity contained about a fluidounce of menses, and communicated with the vaginal pouch by an orifice similar to that of the virgin uterus.

The right Fallopian tube was normal in its origin, and its distal extremity was dilated so as to hold an ounce or two of fluid.

The left tube had an irregular origin near the internal os uteri. The apparent vagina proved to be the urethra. It was three and a half inches long, its walls thick and muscular, and it led to the bladder only. The walls of the latter were thickened and its mucous membrane congested. The fluid removed by the aspirator and also that taken *post-mortem* from the uterine and vaginal cavities showed under the microscope a large quantity of granular detritis, some mucus- and blood-corpuscles, and numerous crystals of cholesterin.

It was impossible to find in the rectum or vaginal pouch any trace of the passage of the aspirator-needle.

In the accompanying drawing I have endeavored to represent as accurately us possible a sectional view of the condition of the parts previous to the rupture of the tumor. An examination of this diagram suggests the theory that at the age of puberty the vaginal pouch was probably not far from the perineum; but as the menstrual fluid accumulated the sac gradually rose from the pelvis into the abdomen, dragging with it the rectum and urethra, the latter becoming elongated and hypertrophied to accommodate itself to the new relations of the parts, and its capacity being enlarged perhaps by *intromissio penis.*

The rectal dilatation is not so readily accounted for, but it is possible that it may have officiated vicariously in the performance of marital rites.

It is difficult to determine in this case precisely when the rupture of the vaginal sac took place; whether it was produced by the pressure used in making the examination, by the puncture of the needle, or by the expulsive efforts of the woman herself. The possibility of such an occurrence

was contemplated before the examination was made, and much care was taken in manipulating the parts, so that it seems improbable that this could have caused the trouble.

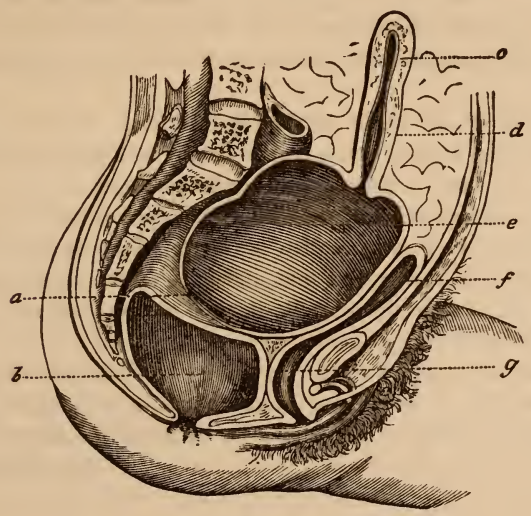

Fig. 4.

b, rectum; *c*, uterus; *d*, cervix uteri; *e*, vaginal sac; *f*, bladder; *g*, urethra; *a*, point of rupture of vaginal sac.

As to the implication of the needle in the disaster, my object was to make the puncture anterior to Douglas's cul-de-sac, so as to avoid the peritoneum if possible; and I think I succeeded. I am therefore disposed to attribute the accident to the patient's bearing-down efforts, which were mostly reflex in their character, and caused by the introduction of a foreign body—viz., the finger or sound—into the congested and irritable bladder.

This view is rendered more probable by the fact that when the puncture was made, about five minutes after the most violent effort, the impression produced upon my mind was that the tumor was softer and farther away from the perineum than it had ever been before. At all events, in consequence of the excessive thinning of the posterior vaginal wall, a rupture at that point was imminent at any time.

The case is instructive as displaying in an unusual manner the peculiar danger of this malformation, and teaches a valuable lesson as to the propriety of an early operation. *February 24th*, 1875.

Report of the Committee on Morbid Growths.

"In Dr. Schell's specimen of congenital occlusion of the vagina, your committee have found the black coloration of the walls of the pouch due to presence of hæmatoidin crystals and pigment-granules in the submucous and connective-tissue layers of the dilated vaginal canal. This coloring-matter has unquestionably been deposited from the retained menstrual blood.

"The walls of the uterus are slightly thickened; there is, however, no dilatation of the uterine cavity proper, simply a funnel-shaped distention of its cervical canal. The absence in this specimen of hæmatometra, so generally an attendant upon congenital atresia of the genital canal after the establishment of menstruation, seems to your committee explicable upon the fact that in this case the anteflexion of the uterus, with the ensuing kinking of the organ at the internal os, has acted as a mechanical hindrance to its further distention.

"The manner in which the uterine cavity has been laid open prevents us from ascertaining whether a complete stenosis existed at the internal os. The urethra very readily admits the insertion of a finger."

March 25th, 1875.

---

c. MALE ORGANS OF GENERATION.

21. *Undescended testicle, and medullary sarcoma of the testicle, occurring in the same individual.*

By Dr. R. M. Townsend.

Saturday, April 4th, 1874, I was consulted by D. R., mate of a transatlantic barque, on account of a supposed hernia. He was wearing a truss at the time that had been ordered for him in Liverpool. He gave the following history. He is 32 years of age, a native of northern Prussia, and has followed the sea since his fourteenth year. When six years old, he fell upon a plough, inflicting a severe bruise upon the perineum. He first noticed his present condition three months ago, as a swelling within the scrotum. At the end of two months it had sensibly increased, and considerable pain had become incorporated with it. For the past month both pain and swelling have been rapidly progressive: the former, especially, so severe that for the last fourteen days of his trip to this port he was incapacitated for work, and had to keep his berth.

Examination of the tumor, after removing the truss, revealed a tense mass with an obscure feeling of fluctuation. It was evidently not a hernia, presenting none of the characteristics of that affection. The introduction of an exploring-needle failed to bring away anything but a few drops of blood. I was unable in my examination to detect the presence of either testicle other than as a component of the mass. There was no enlargement of the cutaneous veins of the scrotum, or of the neighboring lymphatics. The man's general health was good, and he presented no evidences of a cachexia. He denied any venereal taint, and, with the exception of yellow fever in the West Indies, all forms of previous sickness. His mother is living and healthy, as likewise are four sisters. His father died of rheumatism two years ago.

Some degeneration of the testicle being manifest, an operation, in the shape of an exploratory incision, and, if necessary, removal of the affected organ, was proposed as the surest means of relief. The patient assenting to this proposition, he was accordingly placed under the influence of ether, April 15th, and, with the assistance of Drs. Maury and Graham, I removed the organ. Previous to the preliminary incision the feeling of fluctuation seemed to be so well marked that I was induced to introduce the needle of an aspirator. Nothing came away, however, but a few drops of frothy blood. As soon as an incision was made into the testicle a brain-like matter immediately protruded itself. The finger alone was used to clear away the mass, and after it had all been removed the vaginal tunic shone out clear, white, and unaffected. The latter, after ligation of the cord, was removed. But a few drops of blood were lost during the operation.

The removal of the diseased testicle revealed that its fellow had not descended; and as the man has had both sexual desire and intercourse since within a time that the descended testicle must have been utterly destroyed, it bore out the inference that one testicle had failed to descend. Examination failed to reveal its whereabouts.

A careful microscopic examination of the removed mass was made by Dr. Bertolet, who reports as follows:

"The softer portions of the growth are made up of a large round-celled parenchyma. The nuclei are also of a relatively large size, and surrounded with granular protoplasm. The intercellular net-work is well developed, has a soft consistence, and at many points is hyaline, at others again finely fibrillated.

"The greater part of the tumor presents these microscopic appearances, as briefly mentioned, and can therefore be designated as a *medullary sar-*

coma. But there are noticeable at several points hard lumps, not much larger than a pea, which are very firm, white in color, and transparent on thin section. These lumps, upon section, were found to be true hyaline cartilage, requiring, therefore, no further detailed description.

"It was only in a few portions of this pulpy mass that any traces of the tubuli seminiferi were discoverable, but these were so characteristic, and the tubuli distended with irregularly-shaped epithelial cells presenting many protuberances, so as to leave little doubt that active proliferation of the epithelial elements had occurred, and that this mixed growth is to be regarded as being in part carcinomatous, as well as sarcomatous."

May 2d.—The ligature came off the cord.

May 9th.—The patient has convalesced, and goes to sea again in two days. Since the operation he has suffered severely from colicky pains and constipation. A teaspoonful of the fluid extract of taraxacum at night, followed by a saline in the morning, finally gave relief.

Dr. R. M. Bertolet said the testicle was one of the favorite seats not only of all the varieties of sarcoma itself, but also of all the histoid formations found in sarcoma. It is in the testicle that we have the best opportunity of studying heterologous formations. We have here occurring not only the cartilaginous, but as well the adipose, striped, and unstriped muscular tissues, and the different forms of fibrous and myomatous tumors. Indeed, there are sometimes here recognized all these varieties alongside of each other. Enchondromata and myomata may occur as primary growths, go on for a time without giving rise to serious trouble, but finally become painful. A growth may be originally sarcomatous, and after a time in it may appear the elements of cartilaginous or muscular tissue. We have in this instance a sarcoma in the interstices of which are found cartilaginous elements.

But what is perhaps more important to the surgeon is the course of the disease. Sarcoma starting from the testicle, and not from the epididymis, is generally retained for a time by the tunica albuginea, but if this membrane is once broken the growth spreads very rapidly, entering the cavity of the abdomen and involving the retro-peritoneal glands. If this growth, therefore, has not extended along the spermatic cord, although the medullary sarcomata, as well as the medullary carcinomata, are in the highest degree malignant, there may be no further extension of the disease.

April 23*d*, 1874.

22. *Cystic medullary cancer of testicle.*

By Dr. W. S. Forbes.

This specimen is from a man aged 54 years. The patient related that, two years and five months prior to his entrance into the Episcopal Hospital, he had fallen in a fit, and that a few days after the catastrophe his scrotum began to enlarge, becoming in a short time as large as when the operation for removal of the testicle was performed a few days ago.

On examination, the scrotum measured eleven inches in its vertical or long axis, and eight inches transversely. It presented the appearance of a large hydrocele. The upper half of it was translucent, and the lower part opalescent and thick. The man was very much out of health, and very despondent. There was strongly suspected a diseased testicle at the lower part of the mass. In a short time the opacity of the tumor extended over two-thirds of the scrotum. It was concluded that there was a condition of cachexia, as a consequence of which a blood-vessel had ruptured into the sac, producing the appearance so well described by Percival Pott as sometimes occurring when the walls of a hydrocele become much distended.

On tapping the tumor, very little blood and very little water were drawn off through the canula, although the instrument could be moved about with great freedom, imparting the sensation that would be given in moving it through clots of blood, which strongly suggested hæmatocele. The patient was advised to have the tumor removed, to which he readily assented.

At the consultation with my colleagues, I stated my belief in the existence of hæmatocele complicated with malignant disease of the testicle.

On opening the mass, a large quantity of blood and water escaped from the cyst at the upper part, and the testicle was found in the lower part as large as a large orange, and presenting the appearance of medullary cancer.

The history of this case seems to be this: that the man bruised his testicle in the fall he had more than two years ago, that hydrocele was rapidly developed, that the injured testicle was attacked by malignant disease, and that there was ruptured a blood-vessel by distention, giving rise to the opacity in the fluid in the cyst some weeks ago.

The peculiarities of the case are that the patient should have lived over two years with this malignant disease, and that there should have been no metastatic complication, for every other portion of his body appears to be healthy.

March 25th, 1875.

Report of the Committee on Morbid Growths:

"In Dr. Forbes's tumor of the testicle we find, upon microscopical examination, large oval alveoli, filled with nucleated epithelial elements; the latter are seen in the various stages of fatty metamorphosis. There is no cylindrical arrangement indicating the presence of any remaining seminiferous tubules, nor is there any proper intercellular substance. The growth is a medullary *carcinoma.*" *April 8th*, 1875.

---

23. *Chylous fluid from a hydrocele.*

By Dr. H. Lenox Hodge, for Dr. C. H. Masten, of Mobile, Alabama.

History by Dr. Masten.—It may prove interesting to the members of the Pathological Society to examine the accompanying specimen.

The history of the case is briefly as follows: W. H. W., a native of Mobile, aged 22 years, robust in health, five feet eleven inches high, one hundred and fifty-seven pounds in weight, bilious temperament, black hair and eyes, dark complexion, presented himself on the 18th of October, 1874, to be treated for "hydrocele."

He stated that some eight years ago he had first noticed an enlargement of his scrotum, which, however, did not give him any inconvenience, and that it was not until about four years ago that he considered it necessary to seek medical advice upon the subject. Then he was "tapped" by his medical adviser, and (to use his own language) "a quantity of milk was drawn out." Subsequently he was tapped on several occasions, but no treatment instituted for a permanent cure. To satisfy myself of the nature of his affection, I at once introduced a trocar, and, to my astonishment, I drew off f ℥viii of a white fluid, which, to all appearances, resembled "*milk.*" As the case was a novel one, at least to me, I concluded to send a specimen of the fluid to my friend Dr. James Tyson, of Philadelphia, for his examination and opinion.

The following extract from his letter, of date Philadelphia, October 25th, 1874, gives the result of his examination:

"The specimen is alkaline in reaction, sp. gr. 1015, highly albuminous, and appears to be made up, as determined by microscopic examination, of innumerable molecules, which are mere points under a power of four hundred diameters, together with a limited number of small granular cells, somewhat smaller, but otherwise resembling the colorless corpuscles of the blood, floating in a serous fluid.

"Its physical characters are precisely those of *chyle*. Chemically, I find it almost completely dissolved by ether, and, after evaporation of the latter, to leave a cream-like mass. There were no spermatozoids whatever.

"The fluid is not only in its physical but in its chemical characters comparable to chyle, and I believe its origin to be similar to that of chylous urine so called, which is probably due to the leakage of a lymph-vessel into the bladder.

"So here there is, probably from some cause, a similar leakage from a lymphatic into the hydrocele sac. . . . A similar case is reported by Vidal, and called 'galactocele.'

"Our fluid was not examined for sugar; but, even with sugar present, I should compare the fluid to lymph or chyle, rather than milk, for it contained—

"1st. The *molecular base*, with very few oil- (milk-) globules.

"2d. The leucocytes, or chyle-corpuscles.

"3d. The albumen.

"Signed, JAMES TYSON."

Without speculating upon the case, I will simply state that I did not see my patient after the date upon which I evacuated the sac until the 1st of the present month, when he presented himself again, and requested that some operation should be done for his permanent relief, as he was contemplating a matrimonial connection and wished to be fully prepared for the occasion.

The outlines of the operation I will mention, for the condition of the parts (as revealed by the operation) proves the correctness of the suggestion made by Dr. Tyson.

On the 5th of April I cut down upon the sac, and then evacuated its contents through a canula. I found the same character and quantity of fluid as on the former occasion. After having discharged its fluid contents, I split open the sac and carefully examined its entire internal surface, for the purpose of detecting, if possible, the cause of the peculiar fluid. At the upper portion of the sac, just where it begins to be reflected backwards over the testicle, I discovered a small glandular-looking body, about the size of an ordinary pea, having very much the same appearance as the pouting granulations we often see at the opening of a fistula. The sac was very much thickened, and as dense and firm as the ball of an ordinary Davidson's syringe; it was smooth and polished on the inner side, showing no appearance of vessels. Slicing off this little body with a pair of scissors, I at once saw the mouths of some three or four vessels, *which did*

not bleed, and which I believe were the mouths of the lymphatics, which had poured out this fluid.

I dissected them back for a short distance, to see if they had any connection with either the cord or the gland, but found they were lost in the cellular tissue which surrounds the tunica vaginalis. I carefully tied the bunch of vessels with a small silk ligature, and brought one end out. Then, having cut away the front wall of the thickened sac, I coaptated its edges with some four or five delicate silk sutures, bringing to the outside a free end of the suture, and then closed the wound in the integuments with the pin-suture, ordered cold-water dressings, and left my case to heal, as I hoped it would, by primary union.

On the fourth day I removed the pin-sutures, and found the wound in the integuments thoroughly united; and on the 10th of the month, just eleven days after the operation, I discharged my patient, as I hope, permanently cured.

I am aware that it is not usual to treat hydrocele cases by excision of the sac, and then attempt to gain primary union; but in this climate the success of surgical operations is so very great, and the tendency to primary union so remarkable, that I felt justified in attempting the same in this case, as it was desirable to avoid all suppuration. There was very little inflammation following the operation, and, with the exception of some congestion and weight of the testicle (not more, however, than usually remains after an ordinary case of orchitis), I may pronounce my patient cured.

I am pleased to report this case to the Society, not alone on account of its rarity and the interest which I believe it will afford, but because its results so fully sustain the views of Dr. Tyson as to its origin,—viz., "a leakage of a lymphatic into the sac of the tunica vaginalis."

May 13*th*, 1875.

---

24. *Epithelial cancer from the male urethra.*

By Dr. J. Ewing Mears.

This is a secondary growth from the meatus urinarius of a man aged 40.

October 8*th*, 1874.

Report of the Committee on Morbid Growths:

"Dr. Mears's tumor removed from the urethra is an epithelial cancer. The papillæ are covered with dense layers of larger flat epithelia and contain concentrically laminated pearls." *October* 22*d*, 1874.

VI.—THE NERVOUS SYSTEM.

1. *Cerebral hemorrhage.*

By Dr. John H. Packard.

The specimen is the *basilar artery* from which there had been *cerebral hemorrhage*, removed from Miss H. L. C., æt. 73, who was found dead in her room, lying on her face, near the washstand, early in the morning of November 16th, 1873. There were evidences of her having vomited just before her death.

She was under my care in the summer of 1872, with symptoms of hypochondria, no physical cause being assignable. Afterwards she was seen by Dr. A. H. Smith. At the time of her death she had been for some time under the care of Dr. J. C. Morris, on account of debility, insomnia, and hepatic derangement; but these symptoms had in very great degree disappeared, and she had, on the evening previous, seemed to be quite well.

By Dr. Morris's request, I made an *autopsy*, seventy-two hours after death. Present, Drs. Morris and Horace Williams.

Head.—Dura mater adherent to the calvaria. Arachnoid opalescent, with serous effusion everywhere beneath it. A very large clot of blood covered the whole base of the brain, the base of each anterior lobe, and the sides of the hemispheres, extending into the anfractuosities as well as into the third and fourth ventricles. The spinal canal also seemed to be full of clot.

The left vertebral artery was about four times the size of the right (enlargement of the left, or contraction of the right?). The basilar artery was of full size; Dr. Morris thought it dilated. Near its middle, on the left, was an orifice, by which the escape of blood had in all probability taken place. The cerebral hemispheres and cerebellum appeared on section to be normal; but the optic thalami, corpora striata, and crura cerebri were decidedly softened. The lateral ventricles were full of bloody serum, and the choroid plexuses distended with dark clot.

Thorax and abdomen.—Costal cartilages ossified; lungs entirely non-

adherent and normal, but presenting some hypostatic congestion; heart healthy, although slightly softened; valves normal, aorta very slightly atheromatous just at its root.

The space between the layers of the lesser omentum was filled with a mass of solidly coagulated blood, which extended up along the œsophagus, gradually becoming more and more slender, to a point about three inches above the diaphragm. At this point a vessel must have given way; but there was no ulceration or other visible cause for hemorrhage, nor could the vessel itself be detected.

The liver was enlarged, fatty, and in an early stage of cirrhosis; the kidneys were simply congested.

The uterus and ovaries were extremely small; the left ovary especially.

January 22*d*, 1874.

---

2. *Cerebral hemorrhage.*

By Dr. John H. Packard.

Mr. S., æt. 47, seemed in perfect health on the morning of March 5th. At 12.30 he was found insensible in the water-closet, at a hotel.

When seen by Dr. Taylor he was partly conscious, though unable to speak. Pupils not markedly abnormal. When asked if the cold applied to his head felt good, he nodded; and when asked where he had pain, he put his right hand under the back of his head. The left arm and leg seemed paralyzed; the exact degree was not noted. His pulse was feeble, his surface pale and cold, and he seemed in a state of collapse. He swallowed two teaspoonfuls of whisky.

When I first saw him, his face was pale, his breathing stertorous; pupils contracted equally; occasional strabismus, and he was totally unconscious. Sinapisms were ordered, also stimulating injections; ice to head, and afterwards cups to back of neck and temples. Reaction took place; great heat of skin; pulse full and tense; right pupil now became dilated; left contracted. He was bled from the arm to about ten ounces, without any effect but to lower the pulse. Death occurred about ten hours after the seizure.

Autopsy, sixty-one hours after death.—Head only examined. Some decomposition had occurred. Vessels of the dura mater much congested. A large quantity of coagulated blood effused beneath the pia mater at the base of the skull, extending up on the outer surface of both cerebral hem-

ispheres, and dipping into all the anfractuosities. The clot seemed to extend down along the spinal canal; it filled the third and fourth ventricles, as well as the right lateral ventricle, which was enormously distended by it. The left lateral ventricle was full of bloody serum.

Several vessels seemed to run through the clot in the right ventricle, and to one of them was attached a small firm bilobed body.

The brain-substance was universally softened; but whether this was a *post-mortem* change or not, was not apparent. *March* 12*th*, 1874.

---

3. *Tuberculous deposit at base of brain.*

By Dr. John H. Packard.

A. Y., æt. 2 years, was first seen by me May 31st. His parents had moved over from West Philadelphia about ten days before, and on his becoming indisposed they placed him under the care of a homœopath, who gave him something to check a diarrhœa, with dark and offensive stools, which was then his chief symptom.

The child continuing to droop and to show an increasing tendency to drowsiness, they sent over for Dr. M. B. Musser, their former attendant, who advised them to send for me.

During my attendance, the child's symptoms were chiefly stupor, with occasional accessions of jerking, affecting more especially the right arm and leg. The mother said she noticed some strabismus, but could not, of course, tell which eye was most affected. The thumbs were not drawn in. The child took scarcely any food, but did not vomit. The bowels were inactive unless medicine was given. The pulse was from 90 to 93 in the minute, throughout, except on the last day, the sixth of my attendance, when it grew much more rapid and feeble, and the temperature seemed normal to the hand; there was occasionally a marked degree of dryness and harshness of the skin.

A few days before death it became evident that vision was gone; the eyes were normal in appearance, but the pupils were unaffected by light.

Death took place quietly on the 6th of June.

Autopsy, made by Dr. G. S. Gerhard and myself, twenty hours after death.—Head only examined. Body in ice, and stiff.

Skull-cap normal in thickness and firmness; somewhat adherent to dura mater, which seemed normal. Some subarachnoid effusion.

All the veins on the surface of the brain were distended with blood, those on the right side particularly so. A good deal of serum flowed out as the membranes were divided, perhaps partly from the ventricles.

Sections of the brain showed less than normal vascularity. The central portions of the hemispheres, especially the left, were very soft. The corpus callosum was entirely diffluent, and the fornix, choroid plexuses, and septum lucidum were scarcely traceable. All the ventricles were dilated with serum, and some granular deposits existed along the plexuses.

On the base of the brain there was a good deal of effused lymph; a large mass existing in the interpeduncular space, on the front of the pons Varolii, and along down the medulla oblongata and spinal cord.

In the fissure of Sylvius on either side, around the middle cerebral artery, a granulated mass of tuberculous deposit existed, probably interfering with the flow of blood through the vessel, and thus inducing the softening above noted. Smaller deposits of similar granulations existed in great abundance over the other portions of the base of the brain.

The optic globes were not removed for examination, the father of the child being present.

Dr. J. G. Richardson was kind enough to examine the deposits removed, and sent me the following report:

"I find on microscopic examination that the 'little sago-like masses' visible in the pia mater of the portions of brain you left with me on the 8th instant are *true miliary tubercles*, being seated in the tunica adventitia of the arterioles and smaller arteries, and made up of oval and obtusely angular cells (sometimes exhibiting endogenous cell formation), arranged in a delicate net-work, each of whose meshes generally includes but a single cellular element." *June 25th*, 1874.

---

4. *Sclerosis of the spinal cord, with atrophy of the motor cells in the anterior horns of the gray substance.*

By Dr. R. M. Bertolet.

The first series of specimens exhibited under the microscopes are transverse cuts of the spinal cord of an ordinary case of locomotor ataxy. The clinical records of the case are preserved by Dr. Pepper.

The alterations that have occurred in this cord have been limited chiefly to the posterior columns, giving rise to such decided gray degeneration in this section as to be distinctly visible to the naked eye; the translucent

wedge-shaped segments, extending from without inwards, along both sides of the posterior fissure and cornu, penetrate up to the commissure. Here, microscopically, all the medullated nerve-fibres have disappeared, their places being taken up by anastomosing bands of fibrillated connective tissue: in other words, there has been an active proliferation of the neuroglia, in consequence of which the nerve-fibres have gone under; numerous corpora amylacea being the only traces indicative of their former existence. Here and there an axis-cylinder can still be detected. This sclerosis or gray degeneration of the posterior columns is traceable from the cauda equina up through the entire length of the cord: unfortunately, the medulla and brain of this interesting case were ruined by being placed in an improper hardening solution. This gray degeneration of the white substance does not extend into the lateral columns, nor is there any decided lesion discernible in the gray substance proper, beyond the too homogeneous appearance of the stroma. The multipolar cells do not appear smaller than in the normal cord; no appreciable alteration is found in them; certainly their number is not diminished, nor is there any diminution of the size of the anterior cornu itself.

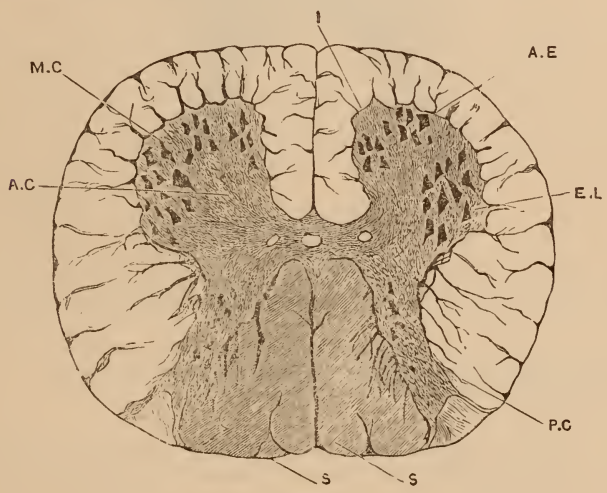

Fig. 5.

Transverse cut through the lumbar enlargement of the spinal cord.—Case of locomotor ataxy.
S S, the sclerosed posterior columns.
P C, posterior horns.
A C, anterior horns.
M C, motor cells of the anterior horns, which are grouped into E L, the external lateral, A E, antero-external, and I, the internal group.

My object in presenting these sections and the drawings of this typical case of progressive locomotor ataxy is to contrast them with the lesions found in the cord of a well-marked case of infantile spinal paralysis.

In the second set of specimens the microscopic sections also reveal the presence of extensive sclerosis of the posterior columns, showing the same exuberant development of connective-tissue fibres; in addition, there are seen disseminated in the anterior and lateral columns small isolated patches where a like indurative process is being developed,—*sclérose en plaques.* But by far the most interesting changes are those that have taken place in the anterior cornua of the gray matter (*vide* Fig. 6).

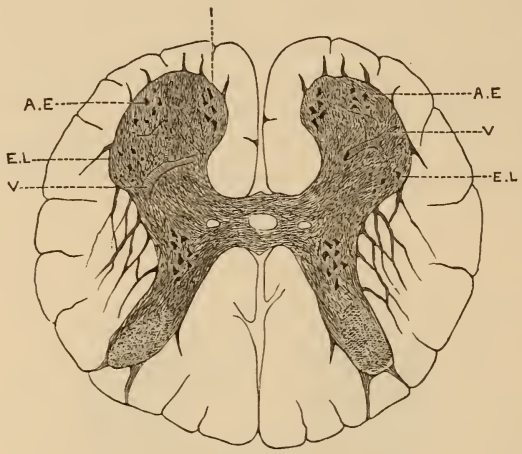

Fig. 6.

Transverse cut of spinal cord through the lumbar enlargement.—Case of infantile spinal paralysis. There exists marked sclerosis of the posterior and anterior columns; not represented in the drawing.

Great diminution in the size and number of the nerve-cells will be observed at E L and A E, the external and antero-lateral groups, while I, the internal group, remains unaltered.

V V represent large blood-vessels in the anterior horns.

With a low power scarcely any of the large multipolar nerve-cells, ordinarily as thickly strewn in the anterior horns as the leaves in Vallombrosa, can be seen; while the lesser groups of these cells situated in the posterior horns, being more deeply stained by the carmine, appear in striking contrast with the surrounding tissues. A higher objective also fails to reveal most of the nerve-cells of the anterior cornua, which are conveniently, though not strictly, classified in three groups: 1, a large external lateral group; 2, a small antero-external group; and, 3, a smaller internal group.

In these specimens it will be seen that the first group of motor cells has nearly disappeared, their places being occupied by a dense fibrillated mass, packed with inflammatory corpuscles; while in the second group but few of the motor cells remain. These are shorn of their long process, their nuclei and nucleoli being concealed by coarse granular pigment-matter, and their edges more or less corrugated: in short, they are seen in the various stages of atrophic changes. The smallest and internal group of these cells alone remains unaffected, the caudal prolongations and nuclei being clearly visible.

It may also be observed that several enormously dilated vessels are seen coursing in the gray matter of the anterior cornua.

These changes were most marked in the region of the lumbar enlargement, whence the cuts that are exhibited were obtained. Sections through the brachial enlargement left no doubt that the process had already ascended to this point.

Whether an actual diminution in the size of the anterior cornua has occurred from the atrophy of the nerve-cells is a matter not so readily determined, since both cornua are in this case affected in about the same degree. This diminution is, however, very apparent when only one limb is paralyzed, as in a case of infantile paralysis reported by Charcot,* and in another by Prof. Roth.† T. Thompson Dickson ‡ also observed the same phenomenon in the spinal cord of a patient who had suffered amputation of the right leg fifteen years before death. Prevost and David § found a like appearance in the right horn in a case of muscular atrophy of the thenar eminence.

Were all other proofs wanting, the data alone obtained from these cases of unilateral fascicular sclerosis would be sufficient to establish beyond all controversy the functions of the large multipolar cells of the anterior horns.

The entire length and thickness of all the white fasciculi may be so far involved in this process of sclerosis that not a single nerve-fibre with its axis-cylinder can be found, and yet the muscles do not suffer directly in their nutrition so long as the nerve-cells maintain their integrity.

It is a fact now generally recognized that the lesions of progressive locomotor ataxy, although most frequently characterized by sclerosis of the

---

* Leçons sur les Maladies du Système Nerveux, Paris, 1873, p. 59.

† Virchow's Archives, Bd. 58, S. 263, 1873. Infantile Paralysis, with complete Bibliography.

‡ Transactions of the London Pathological Society, vol. xxiv., 1873, p. 3.

§ Arch. de Physiol. Normal et Pathologique, Juillet et Septembre, 1874, planche 24.

posterior columns, as in the typical case above, may at times have their seat in the lateral or anterior columns. Sooner or later the slow chronic irritative processes extend towards the gray axis of the cord and consecutively involve the anterior nerve-cells, causing them to atrophy and disappear in the contracting horns. It is then that the locomotor ataxy becomes complicated with progressive muscular atrophy. Cases illustrative of this point are given by MM. Pierret* and Charcot,† and others. This consecutive involvement of the anterior horns in Duchenne's disease is stated to occur in about one-eleventh of the number of cases.

In infantile spinal paralysis, on the other hand, the development or extension of the sclerosis to the anterior horns has lately been frequently observed. Through the kindness of Drs. Parry and Jenks, I have been enabled in three cases of infantile spinal paralysis to convince myself of the existence of the most profound alterations in a great number of the motor cells, and disappearance of others. Fig. 6 is taken from one of these cases.

Whenever we have superadded to the symptoms of spinal paralysis those of muscular atrophy, be the case one of paralysis in the adult or infant, we may, with the greatest degree of probability, expect to find alterations in the motor cells, since there is not a single well-authenticated case on record showing muscular atrophy as a result of the spinal lesion, where the motor cells have preserved their integrity. In these cases the muscular atrophy is unquestionably induced not by a primary affection in the muscles themselves, but is consecutive to the myelitis,—the evidences of myostitis and fatty degeneration of the muscular fibres sometimes observed being therefore of secondary importance, and perhaps altogether accidental.

There are still many conflicting opinions held by different pathologists as to whether the lesions in the motor cells are primary or secondary to the inflammation of the surrounding tissues. Roth‡ is inclined to accept the latter theory in all cases, and this propagation of the inflammatory process along the neuroglia to the anterior horns with the secondary involvement of the nerve-cells cannot be denied to occur in certain cases of central myelitis, spinal pachymeningitis, and tumors of the cord. Charcot,§ on the other hand, regards the lesions of the motor cells as primary in typical muscular atrophy, in infantile spinal paralysis, and in the spinal paralysis of the adult. The exact localization and limitation of the lesions

---

* Arch. de Physiol., t. iii. p. 599,—Sur les Altérations de la Substance grise de la Moelle épinière dans l'Ataxia locomotrice.

† Loc. cit.

‡ Loc. cit.

§ Loc. cit., pp. 60–66.

in certain cellular groups is certainly a very strong argument in favor of their being affected *ab initio*. A very interesting case has recently been published* where congenital atrophy and loss of power in all the muscles of the right thenar eminence were attended with a decided diminution in the size of the right anterior horn, and disappearance of its lateral motor cells. The lesion was most pronounced in the region of the seventh cervical nerve, not extending beyond the sixth and eighth; the white substance presented no appreciable alterations. The constantly-increasing number of such cases, where the alterations are seen confined to the anterior horns, leads us to believe that the nerve-cells are often the primary seat of the irritative process; although in each of the three cases of infantile paralysis examined there was found sclerosis of the white substance as well as in the gray axis.

The clinical histories of these cases of spinal sclerosis, even when the motor cells are involved, as manifested by the progressive muscular atrophy, generally show a very protracted affection, seldom in itself fatal unless the nerve-cells of the nucleus of the hypoglossal and of the spinal nerves are also involved at the same time as those of the brachial enlargement; then a fatal termination is prematurely induced, the symptoms of glosso-labial paralysis being superadded to the ordinary disturbance of the muscular atrophy.

It was formerly asserted that sclerosis of the lateral columns in itself is sometimes accompanied by general muscular atrophy; but later researches by the eminent neural pathologist Charcot† show that this is not the case unless the process has extended to the anterior horns. In a newly-described form of muscular atrophy resulting from this lateral amyotrophic sclerosis, the author, in the paper just referred to, draws attention to the predominance of the atrophy in the upper extremities, while it is at minimum in the legs, amounting to a mere simple paralysis. The arms in this affection, in spite of the paresis and rigidity, still are capable of performing certain movements, but with a trembling motion, which recalls to mind the shaking palsy observed in *sclérose en plaques*. In the few cases so far observed, a relatively short period, seldom extending beyond three years, elapsed before a fatal termination. The existence of this peculiar form of muscular atrophy, affecting uniformly all the muscles of the limb, needs further confirmatory observation.

---

* J. L. Prevost et C. David, Arch. de Physiol., Juillet et Septembre, 1874, planche 24, p. 595.

† Gaz. Méd., Nos. 31 and 32, Août 1, 8, 1874,—"Sclérose primitive et amyotrophique."

Dr. Pepper said that he enjoyed the opportunity, while in Paris, of examining many of Charcot's preparations of the spinal cord at the Salpêtrière, from which the true lesions of infantile paralysis had first been demonstrated. The number of carefully-made observations has now so much increased that it is no longer questioned that one form of infantile palsy depends upon this lesion of the groups of nerve-cells in and near the anterior horn of gray matter.

In regard to this case of sclerosis of the posterior columns, the lesion was the usual and characteristic one of progressive locomotor ataxy, and he believed that the patient from whom the specimen had been obtained, and who had been under his care for some months before his death, had first presented the symptoms of that disease soon after his penis and scrotum had been amputated by a single stroke of a large knife, occasioning copious hemorrhage.

Dr. Harrison Allen did not know whether Dr. Pepper supposed that any relation existed between the peculiar accident and the phenomena of the paralysis, but he thought it not unreasonable that there should have been, conceding the announcement of a favorable predisposing condition. The surgical shock of such an operation, particularly if the organs were excited, must have been very considerable, and could readily have extended to the spinal cord. *October 8th*, 1874.

---

5. *Myxomatous neurome of the brachial plexus.*

By Dr. R. M. Bertolet.

This tumor was removed, November 1st, at the *necropsy* of a woman aged 67, who died from pulmonic phthisis. This growth, considerably larger than a fist, completely filling up the right axilla, never gave rise to any pain or decided inconvenience. It was several years in attaining its present size; the integument remaining freely movable over it, while its soft and fluctuating contents were suggestive of a cyst.

Upon dissecting out this fusiform growth, it was found that the nerve-sheaths formed a continuous covering over it, the nerve-bundles and individual fibres being widely separated and spread out over the tumor, and partially imbedded in it. When cut into, it presented a soft, trembling, gelatinous mass, yellowish-white in appearance; the more vascular portions having a reddish tinge and firmer consistence. In the fresh condition the

substance of this tumor was not only soft and yellowish, but translucent; the alcohol has rendered it slightly opaque and more solid.

Microscopically, the growth is characterized, as can be seen in the accompanying slides, by large *stellate* and *spindle cells*, freely anastomosing with one another. These cells are imbedded in a structureless, hyaline basis-substance, which is rendered cloudy and granular upon the addition of acetic acid and other reagents. Septa of connective tissue are only sparsely developed. At points, large oil-globules are met with: at others, again, small round mucoid cells fill up the meshes; but the bulk of the growths presents the above pure type of myxoma.

Histologically, there can be no doubt that we have here a tissue analogous to embryonal connective tissue, which has sprung from the perineurium of the brachial plexus. It is not a neuroma in the true sense of the word, the term being admissible only in so far that it is indiscriminately applied to all neural tumors. Even the painful neuromatous growths so often occurring after amputations are generally mere fibromas, an actual new growth of the nerve-fibres themselves being exceedingly rare. Most of the spindle-shaped tumors found along the trunks of the nerve belong to the class of myxomas, as has been long ago pointed out by Virchow. When thus situated they are often multiple, and give rise to neuralgia and lancinating pains; yet they may fail to evoke any of these symptoms, as in this instance. Virchow mentions a case in which a painless myxomatous growth seated upon the peroneal nerve was mistaken and opened for a hygroma.

Myxomatous neuromas, like the myxomatous growths occurring in other portions of the body, are comparatively benign, with perhaps even still less tendency to metastasis. After the peripheral nerve trunks, the next most frequent site for these neoplasms is the spinal cord; while in the brain and its meninges they are the exception, the pathological production of the cerebral neuroglia being the glioma. *November* 14*th*, 1874.

---

6. *Multiple myxoma of the spinal cord.*

By Dr. R. M. Bertolet.

These growths were discovered accidentally upon the cord of an adult of whom no clinical history seems ever to have been obtained. They are five in number, scattered along the length of the cord, both upon its anterior and posterior surfaces. The largest measures nearly half an inch in length,

but only a few lines in thickness. The microscopic appearances do not differ materially from those of the preceding specimen. The nerve-filaments were spread over the surface of the tumor first presented.

The President, Dr. Pepper, remarked upon the presence of Dr. J. J. Woodward, of the army, who had been one of the original members of the Society, and most active in its proceedings, and invited him to make any remarks which his large experience in the histology of morbid growths might suggest.

Dr. Woodward said that it would give him great pleasure to say something on the subject, if he thought he could add anything to what had been so well said by the members who had already spoken. He assented to the opinion that these growths are rare; certainly he had seen comparatively few of them. The only point not alluded to by previous speakers which it occurred to him to mention was the occasional association of myxoma with genuine carcinoma in the same growth. Not long since, he had examined such a tumor at the Army Medical Museum. It was from the parotid region, and for the most part consisted of typical myxomatous tissue, with beautiful stellate cells. A portion of the growth, however, had the anatomy of carcinoma, and presented a true alveolar structure, the alveoli being stuffed with masses of granular cells with large nuclei, which adhered together without any intercellular substance. Several of the microscopical sections preserved exhibited both these forms of morbid tissue in different portions of the same section.*

November 14*th*, 1874.

---

7. *Clot in left corpus striatum.*

By Dr. William Darrach.

The specimen was derived from a male patient aged 53 years, height five feet eight inches, stout, of sanguineous temperament and of intemperate habits, but always able to walk.

---

* Dr. Woodward subsequently informed the Recorder that the tumor referred to is No. 6320, Surgical Section, Army Medical Museum. It was from the right cheek of a lady about 55 years old, and occupied the site of the parotid gland, which was apparently atrophied. It was excised November 10th, 1873. Nos. 6459 to 6470, Microscopical Section, Army Medical Museum, are thin sections of this tumor, stained with carmine and mounted in Canada balsam.

On November 28th he had an attack of apoplexy, which produced paralysis of the right arm; he was unconscious, breathed heavily, and cold perspiration stood over the face; his nose was cold, and back of the head hot; pupils contracted; no strabismus. Pulse very feeble. Ten ounces of blood were taken by cups from the occipital region. The pulse came up after the bleeding, and consciousness was restored several hours after. The following morning he was able to swallow, and talked rationally, and the right arm was raised to his head.

November 30th, 4 P.M.—Unconsciousness again returned, with all the other symptoms. Cups were again resorted to, and, after much suction, the blood flowed. Eight ounces were again taken. The following morning the consciousness returned, and he was enabled to take brandy and beef-tea as before.

December 1st, P.M.—The congestion again returned, with the former symptoms. He was again cupped, with great difficulty, as the blood was very thick, but he was again relieved.

On December 2d, A.M., he was unconscious; became worse in the afternoon, and the *left* arm also became paralyzed, but there was no paralysis of the lower extremities. He passed water with great force. At this stage it was not thought advisable to renew the cups, and death followed after midnight.

Post-mortem.—Heart.—Right ventricle covered with fat. Left ventricle quite firm. Aorta showed an atheromatous condition.

Liver.—Fatty degeneration manifest.

Brain.—Sinuses engorged with blood. Pia mater cloudy and œdematous.

Left lateral ventricle contained a very large clot in the corpus striatum. In the *right* none was perceptible, although there had been paralysis of the left arm the last day of his life.

The arteries of the base of the brain were markedly atheromatous.

December 10th, 1874.

---

8. *Extensive subcranial extravasation, which complicated a fissured fracture of the skull.*

By Dr. Richard A. Cleemann.

Through the courtesy of Dr. Tyson, the pathologist to the Hospital of the University of Pennsylvania, I am enabled to show the Society this

specimen of traumatic subcranial blood-clot, from a patient who came under my care before his removal to the hospital.

The subject of the accident was a sailor, 20 years of age. While coming up the river Delaware in a schooner, at 7 A.M., November 30th, 1874, he was struck by a block (a heavy piece of wood bound with iron) attached to the jib-sheets. He was unaware of being unconscious from the blow, though a fellow-sailor afterwards recalled seeing him on his knees; but he could have been stunned but for a very short period, since the captain of the vessel, his father, who was on the after-part of the deck at the time, did not know till an hour afterwards that any accident had occurred. About 10 A.M. the injured man lay down, complaining of pain in the head and vomiting; and in the afternoon I saw him on the vessel, then attached to the wharf. These symptoms still continued, with a feeling of lightness in the head, but he was perfectly conscious and without paralysis. There was tenderness over the right side of the head anteriorly, and a little fulness was observed, but no depression of bone could be anywhere discovered. Ten grains of calomel were ordered, which were to be followed by a dose of sulphate of magnesium. Perfect quiet was directed, and an unstimulating diet.

I saw the patient the next day about noon. He was now lying on his left side, curled up on the seat of the cabin, and seemed to be made uncomfortable by any attentions paid to him. His father said he could only occasionally cause him to speak, but he would open his eyes, which he kept closed, when told to do so, and, at my request, turned his head from one side to the other. He had been found in the morning at the side of the vessel, where he had gone to evacuate his bladder, a portion of the urine having wetted the deck. I understood at the time that his bowels had not yet been moved, though afterwards I was told that he had had an involuntary evacuation. I now considered him to be in the condition of "cerebral irritation," as described by Mr. Erichsen, and, recognizing the likelihood of subsequent cerebral inflammation, and the disadvantages of his residence on the vessel in that event, it was decided that he be removed to the Hospital of the University of Pennsylvania, about a quarter of a mile distant. While I was at the hospital, whither I went at once to make arrangements for his admission, I was hastily summoned back to the vessel on account of an alarming change in my patient's condition. I found him lying on his back on the floor of the cabin, comatose, and suffering one convulsion after another. These spasms were tetanic in character. Suddenly the lower limbs would be rigidly extended with the feet pointed, while the hands and arms would be stiffened and flexed, and in the severer

attacks the muscles of the spine would be affected to the degree of producing marked opisthotonos. The respiratory muscles were also involved, at times to the extent of producing mucous rattling in the trachea, frothing at the mouth, and accumulation of secretion in the nose, these symptoms being followed by an approach to stertor in the breathing, which feature, however, was very transient. Borborygmi were heard in the intestines, but accompanied by no involuntary discharge. The pulse, in the intervals of the convulsions, counted sixty beats in the minute, and was oppressed in character. Under these circumstances, I opened a vein in the right arm, and observed with interest that the prick of the lancet was followed by the motion of withdrawal of the limb. The blood spurted freely till ten ounces had been lost, when the vessel collapsed. This measure was undertaken, not in the hope of cutting short the convulsions, but as a temporary resource, with the view of diminishing vascular tension, that the cerebral congestion consequent on the muscular disturbances might do less injury. The pulse was more free afterwards, though the number of beats to the minute was not altered. The hospital ambulance, though momentarily expected, did not, through a misapprehension of the driver, arrive for the patient, who thus remained two hours longer on the vessel. During the first hour the convulsions continued; then the man, who had been lying in folded blankets merely, and in a corner of the over-heated cabin, was placed on a soft bed, exposed to a current of fresh air, when the spasms ceased; which sequence allows the inference that they were reflex in character, excited by his uncomfortable position. Finally, he was carried on a stretcher to the hospital. The journey, though short, was a severe one, for the day was very cold, and the way lay across three vessels floating at different heights, and over undulating and broken ground. Whether from these causes or not, the man was repeatedly convulsed during the transit, so that when he was placed in a bed in the ward his condition seemed far worse than before. His skin was now very hot; face somewhat livid, breathing labored, though not stertorous, and pulse 120. I detected no paralysis of the limbs, but the pupils were widely dilated.

The case now passed from my care, but I learned that the man died ten hours after admission, his condition becoming worse and worse.

The *necropsy* was made by the house-surgeon, the head only being examined. A fissured fracture of the skull first presented itself. This fracture, as I saw it delineated on a prepared skull, extended from near the summit of the frontal bone, on the right side, running not far from and apparently parallel to the coronal suture, which it crossed low down, into the right greater wing of the sphenoid, where it divided into two

arms, one of which penetrated the lesser wing of the same side. Higher up a branch had been given off, extending forward through the frontal, and another downwards and backwards into the squamous portion of the temporal bone. Examining the cranial contents, a large blood-clot, five inches in diameter and more than an inch thick, is seen, covering, with the exception of a small portion posteriorly, the whole of the dura mater, which corresponds to the right anterior lobe of the cerebrum. The arachnoid cavity is free from blood; the vessels of the pia mater intact, the cerebrum, except the depression caused by the clot and the *post-mortem* staining, normal. Removing the clot, the larger vessels beneath are found uninjured, as was to have been expected from the late occurrence of the symptoms of compression.

This case is in accord with the conclusions of Mr. Callender, that rapid death from coma without paralysis is the usual consequence of effusions about the vertex, but it differs from the general rule in the supervention of convulsions.* It is interesting to note, however, that in Mr. Callender's cases of extravasation into the brain-substance, the spasms were observed, as a rule, when the lesion, which was accompanied with left-side paralysis, was in the *right anterior lobe* of the cerebrum exterior to the optic thalamus and corpus striatum.†

It is exceptional that so severe an injury as the one recorded should have been received without appreciable loss of consciousness. That this symptom, when secondarily developed, did not make its appearance till thirty hours after the accident, is to be explained, most probably, by an issue of blood so slow that the brain was for a time able to accommodate itself to the disturbing effects of the extravasation.

As to the question of the use of the trephine in the treatment, this appears to have been one of the rare instances where its use would have been entirely justifiable. The accurate knowledge of the part struck indicated the probable site of injury, while the slow approach of coma and the absence of paralysis seemed to designate an extravasation without the brain-substance proper.

The *post-mortem* examination revealed no contraindications. The consideration of the measure, however, was deferred on the vessel, on account of the more favorable conditions for the performance of the operation in the hospital; the delay in the transmission there of the patient not being anticipated.

---

* St. Bartholomew's Hospital Reports, vol. iii., 1867.

† Ib., vol. v., 1869.

Dr. James Tyson said he was reminded, by Dr. Cleemann's case, of another on which he had made the *post-mortem* examination, which was striking in its parallelism in some points, while in certain other respects it was essentially different.

The case was that of a gentleman about 60 years of age, much addicted to the use of alcohol, who fell upon the ice, walked several squares to his house, and retired to his room. He was in the habit of remaining in his apartment for days at a time, and a similar course at this time did not attract any attention. At the end of thirty-six hours, however, his room was entered, and he was found unconscious and in a dying condition. He was dead when Prof. F. G. Smith, who was called to attend him, entered the room.

There was total ignorance as to the cause of death, and a *post-mortem* examination was requested with a view to its determination. On inspecting the body, the fingers were found tightly flexed upon the palms, whence it was inferred that he had died in a convulsion. On removing the calvaria and opening the dura mater, a huge clot was found *beneath* the latter, and covering the whole of the anterior half of the right hemisphere, depressing it decidedly, and extending down beneath the base of the brain. *There was no fracture of any portion of the skull.*

Dr. Wm. Pepper asked whether there were any evidences on the scalp or tissues beneath which would indicate that the patient had in falling struck his head with violence. It is not improbable that in cases where the walls of the blood-vessels are much diseased, a spontaneous rupture might occur so as to occasion a clot in that position. Hemorrhage into the arachnoid or sub-arachnoid space is not very rare, and, in a large proportion of the cases where he had himself met with it in adults, had been associated with chronic intemperance. The symptoms which characterize meningeal hemorrhage are quite peculiar, and it is possible that at the moment of the hemorrhage a person should fall, but afterwards be able to rise to his feet and find his way home. It is interesting, therefore, to learn whether any evidence was found of such an injury caused by the fall as might have produced this hemorrhage, either by direct violence or by counter-stroke.

Dr. Tyson said there were no evidences of contusion of any part of the scalp or subjacent tissues.

Dr. Cleemann remarked that the case, in connection with his own, illustrated admirably the conditions under which trephining might on the one hand be of service, and on the other clearly useless. Thus, in Dr. Tyson's case the position of the clot beneath the dura mater permitted the blood to pass down beneath the brain, so that even if the seat of hemorrhage was

reached by the trephine, the operation would avail nothing. But in his own, the clot being external to the dura mater, and therefore circumscribed, its removal was quite within the range of possibility.

He desired to know of Dr. Tyson whether there was any breach of continuity in the brain-substance, as is usual when convulsions occur in like cases. He thought that the convulsions in his own case were evidently of a reflex nature, caused by the uncomfortable position of the man as he lay in the cabin. He thought the brain was in that condition in which it was exceedingly susceptible to irritation, and that under these circumstances the patient would be thrown into convulsions from comparatively trifling causes. He took much interest in these phenomena of the case, from their resemblance to those of certain cases of puerperal convulsions, in which, the brain being already in a state of irritability from the presence of serum constituting an œdema, as it were, the slightest external irritation would excite a convulsion of great violence.

Dr. Tyson replied that the brain was evidently compressed in this case, but there was no breach in the integrity of its structure.

January 28*th*, 1875.

VII.—THE ORGANS OF SPECIAL SENSE.

1. *Aural polyp.*

By Dr. C. H. Burnett.

This polyp was removed from the left ear of a large, healthy young man, 21 years old. The patient states that he has been aware of the existence of the polyp in his ear for seventeen years. He assigns no reason for its occurrence, and says there has never been much discharge attending the growth of this body in the ear. There has never been any operation even attempted on the ear, although he has frequently requested physicians to remove the polyp since it has extruded itself from the orifice of the meatus.

Upon inspection of the affected ear, I find the orifice entirely closed by a "button" of the polyp, covered with integument, and a trace of hardened secretion around the orifice of the meatus, at the sides of the aforesaid "button." There is no odor whatever, nor has there ever been, according to the patient's statement. It was impossible to see beyond the already crowded orifice of the meatus, and I therefore, after testing the hearing, proceeded to extract the polyp.

The hearing for a watch, audible at forty feet, was reduced to contact, and the hearing for the voice was reduced so much as to render the left ear useless in conversation.

I passed the wire noose of a Blake's-Wilde's snare over the projecting "button," and came into a widened meatus, proceeded with the instrument as far inwards as I could get it, and then constricted the innermost part of the growth, and, with the most powerful traction I could make, brought away the polyp. This operation caused the patient *no pain.* There was considerable hemorrhage for three to four minutes (about two ounces), then the hemorrhage ceased almost instantaneously of its own accord. The patient states that next day, while stooping at a spring to drink, his ear suddenly gave forth a gush of blood, but stopped bleeding as suddenly as on the previous day.

After the removal of the polyp, which was of a sigmoid shape, I found

the meatus greatly widened and excavated posteriorly, where the larger curve of the sigmoid-shaped polyp had been lying.

I could not detect any odor in the ear, nor was there any confined discharge behind this large polyp.

After the operation, the hearing for the watch rose to six feet, and conversation was heard on the left side. I touched the point of attachment of this growth with chloro-acetic acid several times, causing great pain for a few moments. The pain from the use of this acid is always relieved by a syringeful of warm water. I am unable to state the appearance or condition of the membrana tympani, since the fundus of the meatus auditorius was entirely filled up by the broad cut surface of the pedicle of the polyp.

May 14*th*, 1874.

Report of the Committee on Morbid Growths:

"The large aural polyp presented at the last meeting by Dr. Burnett measures an inch in length and half an inch at its widest diameter. The growth is more or less distinctly lobulated, and covered with a firm, whitish membrane. The most pendent and exposed portion of the growth is covered with layers of flat epithelial scales, appearing as narrow, spindle-shaped cells when seen in profile. Towards the pedicle, however, the growth is covered with a cylindrical epithelium; having a long tapering extremity, and furnished with a large vesicular nucleus; the broad free extremities are still occasionally furnished with a fringed, ciliated margin. The entire peripheral border of the growth is more or less distinctly marked with low papillary elevations; in the spaces between them, corresponding depressions occur, into which the epithelial layers are seen to dip down, the size of the cells gradually decreasing and becoming more rounded until they reach the basement membrane; the whole presenting a picture closely resembling that of the rete Malpighii of the skin.

"The interior of the growth is densely packed with small, round, finely-granulated and nucleated cells; upon pencilling these away, a very delicate fibrillated stroma is seen, the fibres of which cross each other in every direction.

"The blood-vessels are quite numerous, and, being filled with a natural injection, are very prominent. The larger trunks, occupying the more central portions of the tumor, send out radiating branches towards the periphery.

"There are also present in the growth a very few mucous glands, whose efferent ducts are seen in the transverse cuts as circular spaces lined with a single layer of cylindrical epithelium. A few of the sections made, fortunately, exhibit the branching and racemose extremities of these ducts.

These microscopical appearances, as briefly mentioned above, led your committee to designate this tumor as a *mucous polypus*,—by far the most frequent variety of aural polypi. The presence of the ciliated epithelium can leave little doubt as to its origin from the mucous lining of the tympanic cavity. In fact, modern investigations tend to make this membrane the sole source of all aural polypi; the cutis lining the external meatus taking little or no part in their production.

"These mucous polypi of the ears do not present any histological features differing from those hyperplastic conditions of the mucous membrane of the nose, vagina, and other localities which lead to the formation of polypoid growths. Like them, they are also liable to undergo myxomatous degeneration; at least such has been the experience of some members of your committee who have given considerable attention to the investigation of aural tumors. The gelatinous consistency and translucent appearance of the lower third of this specimen led to the suspicion of myxomatous degeneration having occurred in it. But the absence of any mucin reaction and of anastomosing stellate corpuscles did not warrant such a conclusion. The only case so far recorded where the entire aural polypus was a pure myxoma is that of Steudner, to whose valuable paper* upon 'The Pathological Anatomy of the Aural Polypi' we would refer those who may be interested in the subject." *May* 28*th*, 1874.

---

2. *Polypi from the ear, with portions of a necrosed incus.*

By Dr. C. H. Burnett.

These polypi were removed from the left ear of a boy 7 years old, at present in the surgical ward of the Presbyterian Hospital, where he has been operated upon for lesion of the knee-joint. The patient is of a remarkably scrofulous diathesis, having at present a scrofulous ulcer on the neck beneath the affected ear. I found a copious sanious and offensive discharge issuing from the left meatus when my attention was called to this case by the surgeon then in charge of the ward. The parents state that the discharge has existed for two years.

There has been mastoid disease on each side, to the greatest extent, however, on the left side, where I found a wide depression, with a corrugated surface, as large as the end of one's thumb.

---

* Archiv. f. Ohrenheilkunde, Bd. iv. p. 199.

On the right mastoid process, close to the auricle, directly behind the meatus, there is a small, round, and deep depression in the bone, marking, in all probability, the exit of a former sinus.

Upon inspection of the left meatus, I found a polypus as large as a pea lying half-way down the passage, attached to the antero-superior wall by a short, thick pedicle. I removed the polypus by means of Blake's-Wilde's snare, and touched the cut surface of the pedicle with a drop or two of chloro-acetic acid. Its removal was attended by a slight hemorrhage. After the removal of this polypus and the cessation of the bleeding, I discovered a longer, deep-red body, lying on the floor of the meatus, which at first sight I considered a clot of blood, and, seizing it with a pair of forceps, I gently removed it. As soon as it was removed from the auditory meatus, I discovered that it was an organized body, containing in its structure a large amount of fluid blood, and imbedded in it I found the accompanying piece of bone, which is a portion of one of the ossicles. Dr. H. Allen has examined this bone for me, and has pronounced it the long process of the incus. I could find no necrosed surface in the ear from which this piece of bone could have come, which fact would remove any doubts as to its true nature. The organized vesicle-like body of polypus containing fluid blood was placed in a solution of equal parts of water and glycerin, which soon became deeply stained with blood, leaving the membranous sac quite pale and flaccid.

The first polypus, placed in the same preservative fluid, has retained its original shape and brownish color.

The fetid discharge has ceased, in three weeks since the operation, under the use of daily syringing with Labarraque's solution and water (f℥ss—Oj). The amount of hearing in this case could not be obtained, because the child belongs to that class, now and then seen in hospitals, which makes no reply to its superiors, but converses freely with its playmates, apparently hearing all that is said. There can be no doubt that the boy is deaf in the left ear, for inspection since the cessation of the discharge reveals the entire loss of the membrana tympani and all those portions of the ossicular auditus usually seen from the meatus. What the condition of the bodies of the ossicles may be, it is impossible to state. I believe the portion of the incus removed with the second polypoid growth became detached by a process of necrosis, but was mechanically retained in the meatus by the first polypus, which entirely occluded the meatus. The second growth, to which the long process of the incus adhered, was in all probability a polypus in the process of formation.

June 11*th*, 1874.

3. *Bead removed from meatus auditorius externus.*

By Dr. Chas. H. Burnett.

This bead, seven mm. in diameter, four mm. in thickness, and perforated at its centre, was *removed with a mass of inspissated cerumen from the right meatus auditorius externus* of a woman 68 years old.

The patient was entirely unaware of its presence in her ear, and, of course, could give no account of its mode of getting there. It was in all probability placed there in her childhood and forgotten, as it produced neither pain nor deafness.

Lately, however, the accumulation of cerumen became so great as to cause deafness, and the removal of the obstructive mass to relieve the deafness led to the discovery of the blue bead. *May 28th*, 1874.

---

4. *Keratosis obturans* (Wreden).

By Dr. Charles H. Burnett.

I desire to call the attention of the Society to a specimen of obstructive disease of the external ear, recently described by Wreden, of St. Petersburg, and named by him keratosis obturans, in contradistinction to ceruminosis obturans, with which it has often been confounded, though differing from it very widely.

The latter disease, as its name implies, consists of a mass of inspissated cerumen, but it is easily removed by appropriate syringing, and the ceruminous nature of the mass removed from the ear is recognized, among other features, by the rapidity with which it dissolves in water.

Keratosis obturans, however, recently tabulated by Wreden as a separate and special disease of the ear, is a collection of epithelial laminæ, derived from the cutis of the external auditory meatus, of gradual accretion, causing great deafness, and very obstinate in its resistance to removal.

Every one who has had any extended experience in removing impacted masses, usually of cerumen, from the ear, must have remarked the fact that now and then a mass is encountered requiring a piecemeal removal by the patient use of syringe and forceps, and which, after lying a long time in water, will not dissolve as ordinary wax of the ear does. It is such exceptional masses that Wreden has investigated, and, finding that their

composition is not of cerumen but of the horny elements of the cutis, he has proposed for them the name of keratosis obturans.

These obstructive bodies are not confined to any age or sex.

Wreden states that his attention was first specially called to their peculiar nature by meeting a very adherent one in the ear of a little girl. In this case he was so fully impressed with the suspicion that he was dealing with a wad of soft white paper maliciously placed in the ear by the young patient, that he accused her of the deed, and, although she denied it, he was not convinced of the truth of her denial until the microscope revealed the fact that the mass he had with great difficulty removed was composed of epithelial elements arranged in peculiar laminæ.

Upon inspection of the ear containing such a mass as I have described, a thin layer of ordinary cerumen may be seen covering the outer surface of the plug, and thus one may gain the impression that the case is one of ordinary ceruminosis obturans or ceruminous impaction. But continued syringing, by its barren results in such cases, soon convinces the operator that the obstruction is no ordinary one.

The case furnishing the specimen I exhibit this evening came under my care last July. The patient was a gentleman 60 years of age, suffering with intense deafness and tinnitus in the occluded ear, and, owing to the fact that the meatus was rendered abnormally tortuous by two large exostoses of the meatus, one above, the other below, it required patient and careful picking and syringing for half an hour for eight days before all the foreign body was removed, with, at last, a restitution to normal hearing. From statements of the patient I inferred that similar though smaller and less annoying plugs had been removed from the ear, though he could not give any idea as to the length of time the present one had been forming, as the onset of deafness was almost instantaneous.

Usually, in these cases of keratosis in the external ear, no part of the mass comes away as a coherent plug, but the mass must be broken down and removed in small pieces. In this case, however, I was fortunate enough, by the use of a solution of bicarbonate of soda (gr. x ad f℥j) in glycerin and water, to remove about half of the mass as a whole. When it was first washed out it was perfectly white, and resembled a set of layers of wet tissue-paper slightly separated from each other by the buoyant effect of the water. When pressed upon it felt quite as hard as it does now, but by this time the color of the plug has changed from white to light brown.

Any one pressing upon this mass will perceive how readily its peculiar resiliency distinguishes it from the ordinary cerumen plug, with its soft and greasy consistence.

As insolubility of the removed mass is one of the distinctive features of this peculiar aural disease, I have allowed this mass to remain constantly in water and glycerin since its removal from the ear last July, and the result of the experiment may be seen at this time.

Its resistance to solution and its leathery consistence will readily account for the difficulty one experiences in removing it from the ear.

Wreden has not suggested any cause for the occurrence of this disease of the ear, and, although among the laminæ composing these masses he has sometimes found vegetable spores, he is not inclined to ascribe the origin of the mass to irritative presence of a fungus in the auditory canal.

In cases where a tendency to recur is fully established, care in preventing an accumulation of the laminæ will greatly simplify the malady as well as the treatment. *December* 10*th*, 1874.

---

5. *Gunshot wound of the eye—Excision of the eyeball.*

By Dr. John Ashhurst, Jr.

The eyeball was removed a few hours ago from a colored man, 38 years of age, who entered the Episcopal Hospital on May 30th, 1875, suffering from a gunshot wound of the left upper eyelid and eye. Vision being lost, and the eye manifestly disorganized and moreover very painful, excision was resorted to.

The specimen was referred to Dr. Wm. F. Norris for examination and report. *June* 24*th*, 1875.

Report of Dr. Norris:

"The ball which was handed to me for examination had already been divided by a meridional cut and placed in dilute alcohol.

"There was an abscess in the cornea near its centre, and at the upper part of the ball just behind the corneo-scleral junction was a ragged wound nearly two lines in length, in which lay a large loop of prolapsed vitreous. The remaining vitreous was shrunken, of the consistence of thick jelly, and in places infiltrated with blood. The choroid was much thickened, and at several points detached and separated from the subjacent sclera by serous effusion.

"After hardening, microscopic sections were made of the several parts. Those of the cornea showed an absence of the anterior epithelium, and the tissue proper, besides its usual lamellar appearance, presented numerous

granular spindle-shaped and round cells, and was permeated by numerous capillary blood-vessels. Near its centre was a large lacuna, the pus-cells which had filled it having fallen out, and from this a sinuous tract leading into the anterior chamber. On each side of the lacuna and tract leading from it was a band of corneal tissue resembling in appearance the anterior elastic lamina (Bowman's membrane). The stroma of the choroid was traversed by numerous enlarged and dilated blood-vessels, and its fibres forced apart by an abundant accumulation of round cells (pus), which in places have fallen out of the sections, leaving large lacunæ.

"Near such spots the sclera was markedly altered in structure, its fibres becoming much more wavy and tortuous, and the interspaces between them larger, as if the section had been partially teased out with needles. The blood-vessels of the sclerotic were larger and more numerous than usual, and the nuclei of their walls, as well as those of the proper tissue of the sclerotic, stained deeply, and were more marked than those of normal tissue.

"In such localities between the fibres of the sclera, and especially along the course of the vessels, were numerous round, ovoid, and irregular masses of brown pigment. W. F. Norris."

Sept. 9th, 1875.

VIII.—DISEASES OF THE SKIN.

Description of a specimen of lupus vulgaris.

By Dr. Louis A. Duhring.

The specimen which I present for examination was taken from a patient suffering with lupus vulgaris, who at the present time is under my care. He is an Irishman, 26 years of age, and has been the subject of the disease for fourteen years. An oval-shaped, superficial ulcer, the size of an almond, existed upon the back of the wrist, from the centre of which an island of tissue was seen projecting. This piece of unhealthy-looking skin, not larger than a small split pea, and which had not been there more than a month when first seen by me, was excised with a scalpel. Examined at once with the naked eye, it was found to be soft, gelatinous, and too tender to handle. It contained very little blood, and was pale in color, as though it had been soaked in water. It was immediately placed in a one-fourth per cent. solution of chromic acid, and allowed to remain there three days, when it was transferred to strong alcohol for a few hours, and in this manner prepared for examination. The small fragment was entirely disposed of into thin sections which were variously treated with glycerin, carmine solution, oil of cloves, and oil of turpentine. A large number of the sections were studied, all of them affording similar results.

Under a low power, 60 diameters, the tissue is seen to consist of a very thin layer of hard, horn-like epidermis, remarkable for its imperfect development as well as for the extreme paucity of its cells. Immediately beneath this stratum, which may be likened to an enveloping membrane, is found the rete Malpighii, very highly organized, and unusually distinct in outline, dipping down between the papillæ of the corium. The papillary layer is next encountered, and is seen to be clearly defined against the rete. The papillæ are prominent, and unusually large. The corium itself is totally altered in structure, the connective tissue being almost completely obliterated and supplanted by a mass of fine "granular matter," invading every part of the corium. With the power of 60 diameters this structure bears a resemblance to the spores of certain fungi, particularly those of the Trichophyton, which refract light in such a brilliant manner.

Here and there throughout the corium are seen lumina, varying in shape and size, but without defined border, and which manifestly result from an absence or loss of the "granular matter" referred to. This condition is everywhere noticed, in the papillæ themselves as well as farther down in the corium. A few transversely cut fine hairs are observed in some of the specimens. Gland structure is not noticed. Such are the features recognizable with a low power. With a higher power, 500 diameters, certain points appear which may be mentioned as follows. The rete cells are noticeably large and well defined in outline, possessing the rounded nucleus and angular-formed nucleolus with more than ordinary clearness. Their borders exhibit the prickles very plainly. The rete shows a prolific and rapid growth of cells, similar to that which is seen in other speedy pathological changes which take place in the skin, as in herpes, for instance.

The "granular matter" spoken of when viewing the specimen under a low power is now seen to be made up of a multitude of small cells, which are closely packed together, either free or imbedded in a delicate meshwork. These are of various shapes, some being rounded, others angular or polygonal, and others oval; in fact, they vary greatly as to outline. They also are different as to size; some being relatively very large, and others very small. Some are found to be similar in size to the red blood-corpuscles, while others, the vast majority, are very much smaller. They refract light in a marked degree. Their contents show various stages of change; some of them containing fine granular matter, with a few prominent black points in their centre, while others show a tendency to further disorganization and rupture. These cells, which form the bulk of the tissue, are very numerous, and appear to invade every portion of the corium, from the apices of the papillæ downwards; they are quite evenly disseminated throughout the structure, and show no tendency to aggregate or grow about a centre. At the same time, they are found in larger numbers at some points than at others,—this being accounted for, I think, by there being a more rapid and luxuriant growth at this point on account of some variation in the original connective tissue. The cells are not adherent one to the other, but appear as separate bodies, lying close to one another. The lumina referred to, represent points where disintegration and destruction of tissue, both of the original connective tissue as well as of the new formation, have taken place. About the borders of these cavities, shreds of connective tissue are seen, but they are scanty in number, imperfectly developed, and everywhere studded with the new formation cells. Although the mass of the corium appears to consist of these cells without much of

a stroma, yet upon more accurate examination it is observed that a fine, delicate mesh serves as a bed for most of them, although they are often not firmly seated in it.

The case is an interesting one, from the fact of its being a very recent formation of lupus. It is a *young* specimen of the disease, showing the process in its early stage, and differs in this respect from the specimens usually obtained, which are apt to be of long standing, and show a somewhat different picture, particularly as regards the rete Malpighii.

The numerous cells infiltrating the corium comprise the chief interest which attaches itself to the specimen, and these seem to agree with the observations of Virchow, Auspitz, Neumann, and others. Rindfleisch, however, takes an entirely different view of the subject, considering lupus as an adenoma of the sebaceous glands, and placing it in close proximity to the epithelial growths. This latter view is so at variance with the one commonly accepted that at present it is merely mentioned. Hebra, Virchow, and others agree in placing lupus with the neoplasmata, grouping it with elephantiasis græcorum and syphilis. Virchow considers these three diseases under the head of "granulation" tumors or growths, and adds that they consist of a decaying tissue very prolific in cells, which is rich in cells just in proportion to the degree of its pronounced character; and that the greater the number of cells it contains the smaller and less highly developed they are found to be. According to the same author, the lupus mass is made up of a collection of young, very soft, granulation-like tissue, generally abounding in vessels, which hold, as a rule, small round cells, resembling at times the cell of the rete Malpighii so much as to be difficult of diagnosis. This view corresponds in part with the examination of our case; but that the lupus cells resemble the rete cells so much as to be scarcely distinguishable the one from the other, is a statement which is by no means borne out by our investigation. The line of demarcation between rete and corium was well marked and distinct, so much so as to have been worthy of note in the report. In this connection, however, the variety of lupus, as well as the stage of the disease, whether recent or old, must be taken into consideration, for these are points which it seems to me are sufficient to render different pictures in this portion of the structure. From these few remarks it will be seen that in the main our examination is corroborated by the elaborate studies of both Virchow and Auspitz upon the pathology of this disease. *May* 14*th*, 1874.

IX.—DISEASES OF THE DUCTLESS GLANDS.

1. *Adenoid (Hodgkin's) disease; enlargement of the cervical glands, with multiple lymphadenomatous tumors of the brain, spinal column, lungs, sternum, subcutaneous tissue, etc.*

By Dr. James H. Hutchinson.

The case whence these specimens have been derived has already been reported elsewhere* in full, and I therefore give only the following brief abstract of its history:

W. M. L., aged 19 years, was admitted into the medical ward of the Pennsylvania Hospital January 26th, 1874. His mother died of phthisis; but, with this exception, there appears to have been no tendency to hereditary disease in his family. Some years ago he suffered from enlargement of the glands of the left side of the neck; but this disappeared. He never had a serious illness before the beginning of that for which he was admitted. In May, 1873, the right cervical glands began to enlarge, and soon after this he noticed a swelling over the upper bone of the sternum, which gradually increased in size until it reached that of a good-sized orange. Six months before admission he became aware of a feeling of constriction at the base of the chest, and of a loss of power and sensation in the lower extremities. This increased until the day before his admission, when he became absolutely paraplegic, and lost control over his bladder and rectum. On admission, he was found to have complete paralysis of motion and sensation of all the parts of his body below the thorax. On the right side of his neck there was a mass of much enlarged glands, firm to the touch and not tender. Upon closer examination it was possible to trace the outlines of several glands which appeared to be loosely bound together. In addition to these and to the tumor over the sternum, there were numerous tumors varying in size from a millet-seed to a walnut distributed over the body, especially on the trunk, although the arms, legs, and face were by no means free from them. No enlargement of the

* Transactions of the College of Physicians of Philadelphia. Third Series, vol. i.

spleen or liver could be detected. A slight excess of the white cells was discovered when the blood was examined microscopically.

Death from exhaustion took place May 4th, 1874, or very nearly five months after the appearance of the first serious symptoms, and a year after the enlargement of the cervical glands was first perceived. At the *autopsy* the tumor (Fig. 7) of the sternum was found to measure from three and

Fig 7.

one-half to four inches in diameter, and was raised above the surface of the bone at least one and one-half inches. It penetrated the sternum, and was nearly of the same dimensions beneath the bone as above it. The other tumors were distributed over the body as follows: On face, twenty-four; on front of chest, seventy; on front of abdomen, sixteen; on back, twelve; on right leg, thirty-three; on right arm, eighteen; on left leg, twenty-three; on left arm, forty-three,—making in all two hundred and thirty-nine. Twenty similar tumors were counted scattered over the surface of the brain.

On opening the chest and removing the thoracic viscera, a tumor was found completely surrounding the bodies of the sixth, seventh, and eighth dorsal vertebræ (Fig. 8), and continuous with this through the intercostal spaces were similar growths, occupying the gutters on both sides of the spinous processes, but causing little or no projection posteriorly. The spinous and transverse processes of the vertebræ were so soft that they could be readily cut with a scalpel. Upon removing the tumor, it was

Fig. 8

seen to have penetrated into the spinal canal, where it was adherent to the dura mater. It compressed the spinal cord (Fig. 9), which was, in this

Fig. 9.

position, less firm than elsewhere. A similar, but much smaller, tumor was found within the canal at the level of the last dorsal vertebra.

The lungs contained a large number (as many as three hundred were actually counted) of tumors, similar in appearance to those in other parts of the body. Their average size was about that of a large pea; but a few were considerably larger than this. Small tumors, about the size of a grain of Indian corn, were scattered over the peritoneal covering of the intestine. The mesenteric glands were much enlarged and prominent; but no other lymphatic glands within the abdominal cavity were diseased. The liver was normal in size, color, and consistence, being free from tumors either on its surface, in the connective tissue of the fissure, or in its substance. The spleen was not enlarged, and presented an absolutely healthy appearance. Tumors were found in the substance of and surrounding the kidneys and supra-renal capsules.

A small piece of the left femur, about its middle, was removed for the purpose of examining its medullary cavity. This was filled with a yellowish-green gelatinous substance.

A microscopical examination of portions of the tumors, after hardening in alcohol and pencilling out their sections, showed an almost complete identity in the arrangement of their stroma with that of a lymph-gland.

May 28th, 1874.

---

2. *Diseased supra-renal capsules from a case of Addison's disease.*

By Dr. F. P. Henry.

T. G., æt. 23, sailor, born in Trieste, Austria, was admitted to the Episcopal Hospital January 4th, 1874. The diagnosis on admission was epilepsy, based upon the fact that he had previously had attacks of that disease. He came under my care on May 1st, and at that time was suffering from obstinate constipation, with nausea and occasional attacks of bilious vomiting. His pulse was extremely feeble, and he complained of a constant sense of weakness. The man was naturally of a very dark complexion, but there was a peculiar dinginess in the color of his skin which attracted my attention from the first, and which, taken in connection with the other symptoms, led me to suspect that I had to deal with a case of Addison's disease. At times there was great tenderness about the umbilical region, and on one occasion, after palpating the abdomen, the patient uttered loud cries for ten or fifteen minutes, and seemed in great agony. Nothing was found after death to explain this symptom. The urine was examined at different times, and only once presented a faint trace of albumen. The lungs were examined and declared sound, as they proved to be at the *post-mortem.*

The prostration became gradually more marked, the pulse more feeble, and the stomach so irritable that the greater portion of the food was vomited. There was frequent vomiting of bile. During the last three days of life there was suppression of urine; Dr. Reed, the resident physician, passed a catheter, but no urine flowed through it. He then received a vapor-bath.

The man died on June 22d. The *autopsy* was made six hours after death. The intestines, both small and large, were found to be quite empty and decidedly contracted. The liver, stomach, and pancreas presented no gross appearances of disease. Spleen slightly enlarged and congested;

lungs healthy. The kidneys and supra-renal capsules were removed together. The latter organs were seen to be much enlarged. In the fresh state, on section, they were of a yellow color, and the opposite surfaces of the section poured out a quantity of thick, yellow matter resembling pus. Small nodules were found in both organs which presented the gross appearances of softening cheesy masses. Under the microscope, a section of one of the diseased glands presented a large quantity of granular matter, a few large oval cells containing oil-globules, and a number of small, irregularly-shaped cells, judged to be tubercle-corpuscles. No trace of the normal structure of the gland, such as its division into cortical and medullary substance, was observed in the specimen examined.

I omitted to mention that a moderate quantity of adipose tissue was found in the abdominal walls and in the mesentery and great omentum, and that the bladder was empty.

Dr. Wm. Pepper said there were several points of clinical interest about this case, not the least of which was its connection with epilepsy. Recent investigations tend to associate some forms of this latter affection with lesions of the cervical sympathetic; and so, in well-marked cases of Addison's disease, the nature of many of the symptoms, as well as the results of some *post-mortem* examinations, shows that the abdominal sympathetic nerve is involved.

As to the connection between the melasma and the lesion of the supra-renal capsules, although not so close as Addison thought, at the same time examination shows that cases in which lesions of these bodies are not found are generally wanting in certain essential symptoms of the disease.

He had seen cases where the *autopsy* proved both the existence and absence of the lesion of the supra-renal capsules; but whenever the typical symptoms were present, such as disturbance of the heart, disposition to syncope, irritation of the stomach, tendency to vomiting, gastric tenderness and associated nervous phenomena, there was always marked caseous degeneration of the supra-renal capsules. In the last of these cases, also, critical examination of the solar plexus indicated disease. There was an increased amount of fibroid tissue in the ganglia, atrophy of the nerve-tubules, and excessive pigmentation of the ganglionic cells. Whether this latter was pathological or not, he could not positively aver, since even in health the pigmentation of these cells is often marked; but it is sufficient that lesions of the solar plexus have been found to exist, in some cases, where it has been carefully examined. *June* 25*th*, 1874.

Report of the Committee on Morbid Growths on the supra-renal capsules presented by Dr. F. P. Henry, June 25th.

"The microscopical examination of the enlarged supra-renal capsules accompanying Dr. F. P. Henry's specimens from a case of Addison's disease exhibits an excessive development of the stroma into fibrillated connective tissue, which is marked with small-cell infiltration. At numerous points large cheesy foci, composed of granular detritus, are seen in varying degrees of softening. No miliary tubercles were detected. There is almost complete destruction of the parenchymatous glandular structure; though towards the cortex long parallel cell-columns are found at great intervals.

"We have here to deal with that alteration of the supra-renal capsules most frequently observed in morbus Addisonii,—viz., *cheesy fibrinous metamorphosis* of these glands. It may be here remarked that this cheesy fibrinous degeneration is very liable to be associated with tubercles in these glands themselves, or else it is complicated with general tuberculosis. According to Klebs, this association of the two diseases occurs about in the proportion of two to one."

---

3. *Tumor of the thyroid gland.*

By Dr. John H. Packard.

The specimen was removed November 12th, from Mrs. M., æt. 42, who has suffered from it ever since the birth of her second child, nineteen years ago. Within the last year it has been increasing rapidly in bulk; she has suffered much annoyance every winter from it, as well as whenever she took cold or upon making any exertion. The operation was done at her earnest desire, and was in itself not difficult, although the hemorrhage was profuse immediately afterwards and required very prompt and energetic action. The tumor is presented in order that it may be referred to the Committee on Morbid Growths for examination.

November 12th, 1874.

Note.—The patient progressed favorably until the seventh night, when there was slight bleeding from the effect of an irritative cough. Congestion of the lungs, which had been previously somewhat troublesome, now became extreme, and she died twenty-four hours subsequently.

Report of the Committee on Morbid Growths:

"The tumor of the thyroid gland removed by Dr. Packard is an ordi-

nary *struma hypertrophica*, with commencing colloid degeneration. The glandular follicles of the parenchymatous substance have evidently been undergoing active proliferation and segmentation, as shown by the budding-out of small glands from the walls of the larger parent follicles. Many of these follicles contain, besides their epithelial lining, a thick, amber-colored, gelatinous or colloid substance. The size of the distended follicles is very variable: in no place, however, have they coalesced so as to form large cystic cavities. The blood-vessels of the fibrous septa are very abundant and large, but the connective tissue itself is only developed in a very subordinate degree,—not sclerosed. In many places the network of vessels had a peculiar glassy appearance, their walls being unusually thick, and, upon the addition of iodine, yielding a distinct amyloid reaction. We have, therefore, a struma gelatinosa, with partial amyloid degeneration of the blood-vessels." *December* 11*th*, 1874.

---

4. *Enormously enlarged spleen.*

By Dr. W. G. Porter.

The specimen is from Mrs. H., white, born in the United States, married, about 40 years of age, mother of five children, the youngest now 7 years of age. She always enjoyed good health until 1865, when she went to Norfolk, Virginia, where she contracted a very obstinate form of malarial fever, for which she could never be induced to submit to regular treatment. She never would take quinine, or, in fact, medicine of any kind for any length of time. About 1868 she had a fall, when she felt, as she expressed it, "something give way," and soon began to feel pain in the left side in the region of the spleen, which was accompanied by acid eructations, and considerable gastric and intestinal disturbance. Soon afterwards a tumor was noticed in the epigastric and left hypochondriac regions, which gradually increased in size until it filled the whole abdominal cavity. About eighteen months ago she was examined by Dr. F. J. Buck and Dr. John S. Parry, of this city, who pronounced the tumor to be an enlarged spleen. She was treated locally by the biniodide of mercury ointment, and the bromide of ammonium internally. Before and since that time she had been treated by many regular physicians; also by homœopaths, and every other variety of quack; several of whom pronounced it to be an ovarian tumor, and one of whom assured her that the tumor was ovarian, and was very anxious to

remove it, assuring her that he could remove it almost without her feeling it. On Friday last, she not only attended to her household duties as usual, but visited an administrator of oxygenated air, who promised to cure her in two weeks. She also attended a furniture auction, and was on her feet the greater part of the day. On Saturday she complained of great abdominal pain and some difficulty of breathing, which was greatly increased by the recumbent posture.

On Sunday night I saw her for the first time, and found her sitting propped up in bed with pillows, complaining greatly of pain in the abdomen and a feeling of tympanitic distention. Her stomach was very irritable, and she had vomited large quantities of a greenish, bilious-looking fluid. She was much emaciated and thoroughly anæmic. The pulse was weak, and she was evidently extremely ill. Morphia was administered hypodermically, followed by hot applications to the feet and brandy and chlorodyne by the stomach. The anodynes had but little effect in relieving the pain, and on the following day she died.

Autopsy, thirty hours after death.—Body extremely emaciated; abdomen very much enlarged and distended. On opening the abdomen, it was found to be almost entirely filled by a large tumor which lay immediately under the peritoneal coat of the abdominal walls and in front of the intestines. On lifting it up, it was at once seen to be the *spleen*. There were no adhesions between it and the abdominal walls. The weight of the organ on removal was found to be *twenty-one pounds*.

Dr. Wm. Pepper said the exhibition of such a tumor brings up the question of extirpation of the organ involved. The absence of adhesions observed here is frequently observed in connection with malarial disease; the changes in the peritoneum being limited usually to capsular thickening. When the organ approaches at all near the size of the present one, treatment has been heretofore an entire failure, and this has been so well recognized that the possibility of extirpation has often been discussed, and the operation actually performed in several instances. As to other forms of treatment in less advanced cases, hypodermic injections of ergotin seem to have some influence over the contractile element of splenic tumors, though more evidence is needed before the value of this treatment can be determined. He had recently a case of leucocythæmia under observation where there appeared to be a temporary diminution of bulk under this mode of treatment. All treatment by external inunction and internal use of quinine is successful only in comparatively small degrees of enlargement. He would be glad to hear an expression of opinion, with regard to the propriety of operation, from the surgical members of the Society.

Dr. John Ashhurst, Jr., said that it was, of course, well known that splenotomy had been performed with success in *traumatic* cases, but no instance had, he believed, occurred, at least in modern times,* in which success had attended the operation when performed for such a condition of the organ as was exhibited in the specimen on the table; death having, indeed, in these cases usually followed in a short time from hemorrhage. In view of such a history as had been read this evening,—the patient carrying this enormously enlarged spleen for years with comparative comfort, and being able to attend to her ordinary avocations,—the surgeon who should propose to operate would, in Dr. A.'s judgment, assume a grave responsibility. The probability of relief from such an operation was so small as to be totally incommensurate with the risk to life.

Dr. R. M. Bertolet said that if this huge organ was an *ague spleen*, as had been suggested, he thought it of a rare type, as we usually have more thickening of the capsule than is here found. He thought it remarkable that the organ with such a thin covering did not rupture long before it had attained its present size. Another reason against its being a mere ague spleen appeared in the light color it presented instead of the dark pigmented hue of the ague spleen. He was also impressed by the waxy appearance of its cut surface and the translucency of its edges, and asked whether the iodine test for amyloid degeneration had been applied.

Dr. Wm. Pepper said that he also had been struck with the points alluded to by Dr. Bertolet, particularly as to the translucency of the edges and the absence of capsular thickening, but he was deterred from mentioning them

---

* This sentence perhaps requires some explanation. Dr. Otis, U.S.A., the able surgical historian of our late war, has, in the forthcoming second volume of the Surgical History (the advance-sheets of which I have had the privilege of inspecting), collected twenty-six cases of splenotomy, of which only six are said to have terminated fatally. Sixteen cases, in which the operation was performed for *traumatic* causes, all terminated successfully. Of the other four cases in which death did not follow, one belonged to the first half of the sixteenth and one to the first half of the eighteenth century; in the third (Dorsey's) the spleen does not (according to the report in Eve's "Remarkable Cases in Surgery") appear to have been actually removed, but, its adhesions having been broken up, to have been placed "as nearly as possible in what I [the operator] conceived to be its natural position;" while the fourth was Péan's famous case, in which a cystic spleen was removed under the impression that it was an ovarian tumor. Six cases have come to light since Dr. Otis's table was printed, of which four (traumatic cases) are said to have resulted favorably, and one in death, while the termination of the sixth has not been published. Thus, there appears to have been no case reported, during the last one hundred and fifty years, of successful splenotomy for leucocythæmic or malarial disease, while there have been, during the same period, at least seven cases in which the operation performed under these circumstances was the immediate cause of death.—J. A., Jr.

by the fact that the other viscera were uninfluenced. Further, such extreme enlargement of an albuminoid spleen is rare, while there was also the history of persistent malarial disease previous to the appearance of a tumor. The freedom from suffering and the long maintenance of activity were as remarkable as anything else in the case. In other cases of extreme enlargement, he had observed considerable suffering and great impairment of general health. He shared Dr. Ashhurst's opinion with regard to the impropriety of operating, to a great extent.

Dr. Porter said that it had changed color since its removal, when it was much darker in hue. It had been preserved in a fluid containing a mixture of salt and saltpetre. The tumor was not diagnosed as an enlarged spleen until eighteen months ago, and Dr. Parry, who made the diagnosis at that time, is now out of town, and no further history could be obtained.

March 25th, 1875.

Report of the Committee on Morbid Growths:

"The monstrous spleen, presented by Dr. Porter, does not respond to the tests for amyloid reaction. Fresh microscopic sections show the presence of much black pigment-matter in all the splenic tissues. The Malpighian bodies and trabeculæ are not appreciably hypertrophied; the hyperplasis seems to consist solely in an aggregation of blood-corpuscles (chiefly red) in the cavernous sinuses or pulp-substance of the spleen."

April 8th, 1875.

X.—TUMORS NOT OTHERWISE CLASSIFIABLE.

1. *Hard cancer of the mamma.*

By Dr. John H. Packard.

The specimen was removed from Mrs. T., æt. 70, English, mother of six children, only two of whom lived to adult age, and they died of consumption. Her last confinement was twenty-five years ago. Lactation was always normal, without abscess or other difficulty.

The present growth made its appearance as a very small knot, a year or two ago. It began to enlarge rapidly, and occasionally to give her pain, about four months ago. General health perfect. The growth—about the size of a lemon—and the atrophied gland were removed, by operation, March 3d, Dr. L. Starr giving ether, and Drs. John Ashhurst, Jr., and Brinckle being present and assisting. Three or four vessels were secured by torsion. The wound was closed with hare-lip sutures, and carbolized cerate applied.

The case has done well. *March* 12*th*, 1874.

---

2. *Hard cancer of the mamma.*

By Dr. J. Ewing Mears.

The portions exhibited were removed from a patient aged 46, at the third operation which I have performed upon her. At the time of the first operation the entire gland was excised. In a year from this date the disease reappeared in the cicatrix, and two small masses were removed, one of which had undergone ulceration. Eight months following the second operation three nodules of cancerous tissue were excised, the development and growth of these having been very rapid. After the third operation the patient was attacked with pleuro-pneumonia, which terminated fatally in a few days.

In presenting these specimens to the Society, I desire to direct the

attention of the members to a method of treatment which has been pursued in this case, and to exhibit the results as shown in the specimens. A short time prior to the first operation, and after the full development of the tumor, the patient was examined by Dr. Washington L. Atlee, in consultation, at whose suggestion the administration of *arsenic* was commenced. The form employed was the officinal liquor potassii arsenitis, which was given in *two*-drop doses. The medicine was administered without interruption from the time of the first operation until the second,—a period of one year. During this time the patient's general health was remarkably good. There appeared to be an entire absence of that condition designated the "cancerous cachexia." Her appetite was not at all interfered with, and there was no loss of flesh or strength. The return of the cancerous growths in the cicatrix was unattended by pain, from which she had suffered severely during the development of the primary tumor. The portions removed at the second operation were submitted to a careful microscopical examination by Dr. Tyson, and pronounced by him to be specimens of scirrhus. He noted an extreme degree of fatty degeneration in the cells of the structure,—nothing to indicate any impression made upon this secondary growth by the long-continued use of the arsenic.

A good recovery followed the operation, and the patient was again placed upon the arsenic; in five months *three* small masses were observed, one occupying the site of the cicatrix, one about two inches above, and one about one inch below it.

The patient's health was not so good after as before the operation; her strength began to fail, and in other ways she manifested a decline of her former good health. The stomach was not affected by the use of the drug, so far as could be observed. It seems proper to ask that the specimens removed at the third operation should be referred to the Committee on Morbid Growths, for their examination. If these are found to be specimens of scirrhus, the conclusion is inevitable that in this case the remedy was ineffectual in modifying the character of the growth.

The test was made under the most favorable circumstances; the social condition of the patient was such that all directions were strictly enforced; the arsenic was taken regularly and without intermission. The specimens as removed have been submitted to careful microscopic examination, and their character definitely determined. *March* 26*th*, 1874.

Report of the Committee on Morbid Growths:

"The mammary tumors presented by Dr. Mears have a firm, glistening white appearance upon fresh section; very little soft fluid matter can be

pressed out from them. Microscopically, the tissue is composed in greater part of thick and tough fibrous bands of the interstitial connective tissue; in this structure are imbedded nests of small, epithelial-like cells, which are seen in the various stages of fatty infiltration and degeneration. At a few points of the growths a distinctly tubular arrangement of the cells could be made out, as if the cancerous infiltration had originated in the tubules of the lacteal glands. No definite conclusion could be arrived at, however, as to the starting-point of the growths, since at many places nothing but a *débris* of fat-granules denoted the former site of the cancerous cells. The extremely wide and dense bands of the stroma crossing each other in every possible direction, and the almost complete fatty metamorphosis and absorption of the cellular structure, lead your committee to designate these nodules as retracting cicatrizing fibrous carcinoma,—the scirrhus proper." *April* 9, 1874.

---

3. *Hard cancer of the mamma.*

By Dr. John Ashhurst, Jr.

This specimen was removed a few hours ago from a married woman, 43 years of age. The right breast was the one affected, and the patient, who had borne several children, attributed the formation of the tumor to a blow which she had received upon the part. The disease has lasted about one year, but has been a source of suffering for only four or five months. The nipple was much retracted, partly on account of a previous mammary abscess, and the skin over the growth was becoming adherent, but there were no deep adhesions and no glandular implication. The mass was removed through an oval incision, care being taken to cut wide of the diseased structures and to remove with the tumor much of the surrounding subcutaneous fat. *March* 25*th*, 1875.

---

4. *Fatty tumor from the region of the scapula, with photographs and microscopic slides.*

By Dr. C. B. Nancrede.

The patient from whom this tumor was removed is a colored washerwoman, aged 37 years, who stated that she accidentally noticed the growth

four years ago. It was then small, situated over the right scapula, just beneath the spinous process, was of slow growth, painless, and gave no inconvenience. During the past few months, however, its growth was quite rapid, with occasional stinging pains in the part, and considerable inconvenience caused by its extending down upon the posterior fold of the axilla. The patient had never received any injury to the part. I removed the tumor on the 19th of March, 1874, by the antiseptic method, in its entirety. In eleven days the patient was well, and I believe that, had I had more faith in this method, the wound would have been soundly healed in half the time.

I had determined to test the preservative influence of chloral on the first favorable opportunity, and accordingly placed the growth in a solution of about gr. xv of chloral to the ounce of water. It can be seen at a glance that beyond the ordinary maceration which any specimen must undergo in any fluid, there is no alteration or bleaching, for the small capillary vessels supplying the capsule can readily be seen. There is also no unpleasant odor. The microscopic preparations were taken after the growth had stood in the chloral solution some time. I think that most observers have been annoyed to find that after placing specimens in some one of the so-called preservative fluids they were useless for microscopic purposes. This objection evidently does not hold good with regard to chloral. The photographs taken by Dr. Seiler, aided by the specimens under the microscopes, show very beautifully the mode of growth of lipomata. The first slide is a section of ordinary adipose tissue, and the extreme regularity in size of the component cells will be noted, with few or no interspaces at their angles. In the second, which is a section of the tumor, the great irregularity in size of the cells will be noticed, many being from one-fifth to one-fourth larger by actual measurement than those of normal adipose tissue, while many more are only one-quarter this size. In the third specimen,—mounted in Canada balsam, showing only the cell-walls,—in several places one of the smaller cells is seen situated between several larger ones, its walls much thicker, and studded at various points with masses of germinal matter. In many of the smaller interspaces will also be noted little masses of germinal matter stained deeply by the carmine solution, thus showing them to be newly-formed. Owing to their great differences in size, the cells do not assume that comparatively regular pentagonal form seen in the first specimen, but tend to assume one more rounded. These appearances clearly indicate the mode of development of fatty tumors. In consequence of some irritation, there is set up a circumscribed proliferation of the connective tissue in some clusters of fat-

cells. This is followed by a fatty infiltration of these newly-formed cells; and we thus have the explanation of the small cells arising between the large ones; for here at the angles the new germinal matter forms, which is gradually thinned out by the pressure of the fat within. This explains, too, the thicker walls of the smaller cells, which are younger, have less fat infiltrated into them, and therefore have their wall less stretched.

I would now advert to the point of surgical interest in this case,—viz., the method of removal. I followed in its entirety Prof. Lister's method, but used, instead of his cere-cloth, Mr. Lund's antiseptic gauze. As this method has given rise to considerable discussion, and has been as heartily condemned as it has been praised, I will describe the steps. My instruments were all dipped in carbolized oil, made by adding one part of acid to nine parts of oil. The incision was made and the dressing completed under a spray of one part of the acid to forty parts of water, and the wound was closed with carbolized catgut ligatures and antiseptic adhesive plaster. Over the line of the incision several layers of linen steeped in the carbolized oil were laid, over this again the "protective," made by varnishing oiled silk on both sides and coating with starch, so that when dipped in the carbolized water some would be retained, and finally six or eight layers of the gauze and a pad of tow. On the third day the dressing was removed, and renewed under the carbolized spray, when most of the wound, which was between four and five inches long, was found to have healed by first intention. As I was a very lukewarm believer in this method, never having tried it, I left one angle of the wound open to allow drainage. Had I not done this, I think that I should have had union by first intention throughout the entire extent of the incision. During the time that the open part took to heal by granulation I do not think that there were twenty drops of pus discharged. Some of the catgut sutures I removed, others cut out, and one was partly absorbed, so that it came away as if the loop had been divided. Now, it is possible that I might have had this result by ordinary methods, but I certainly would have had more pus from the granulations, especially in a patient who warned me before the operation that former slight injuries had not healed readily. Nor is it likely that so large a wound, which from its position favored the collection of blood, pus, etc., would have healed in five days,—a result that I have no doubt I would have attained had I closed it entirely. I think, from the result of the case, and others in which I have adopted the method in part, that the reason it has so often proved unsuccessful is because all the minutiæ were not attended to. As to whether it is useful by excluding germs, as Mr. Lister originally thought,

I do not pretend to know. Certainly the effects of exclusion of air are well known, as in subcutaneous operations. The antiseptic method bids fair, in some way, to come nearer this than anything we know of at present.

April 9th, 1874.

---

5. *Angeioma with sarcomatous degeneration.*

By Dr. L. A. Duhring.

The tumor which I present for examination possesses the following history: The patient was an Irishman, 50 years of age, with good general health, who stated that the growth began fifteen years ago. It first showed itself in the form of a small elevation or wart-like prominence. Its growth was very slow, especially for the first few years; of late it had evinced a disposition to more rapid development. At its commencement it was not painful, and caused him no inconvenience whatever; but since it had increased in size, within the last few years, it had been somewhat painful when squeezed or accidentally struck, and had been a source of "worriment" to him.

Upon inspection there was found a somewhat pendulous tumor, the size of a large hazel-nut, pedunculated, and seated upon the tissues of the left arm, at about the insertion of the deltoid muscle. It was soft and spongy to the touch, but could not be manipulated without causing decided pain. After prolonged gentle pressure it became quite distorted, but immediately regained its former shape and general appearance upon the removal of the force. It was a flaccid tumor, hung loosely from its pedicle over the skin of the arm, and could be moved readily from side to side in all directions. In form it was roundish and somewhat oblong, and possessed a smooth though corrugated surface. In color it was, when in its normal condition, dark-reddish, with a purplish hue in its most dependent parts; when exposed to manipulation or pressure the color varied, and showed many shades of red and purple. The growth manifestly contained blood in large quantities, which could be made to accumulate or disperse, according to the manner in which it was handled. There was no sign of ulceration or breaking down anywhere upon its surface, its structure throughout appearing to be uniformly distributed. The growth bore the general features of an erectile or vascular tumor. There was no pulsation perceptible.

Immediately after removal, which was accomplished by an elliptical incision about the pedicle, including a considerable portion of skin and

subcutaneous tissue, the tumor became softer, although it still retained its general form. But little blood escaped during the operation, and the patient made a favorable recovery. The tumor was cut open directly after excision, and showed a grayish surface with numerous reddish puncta disseminated in an irregular manner. The tissue was soft and spongy, although quite firm, and exhibited no appearance of disintegration. It possessed a reticulated structure.

Upon pressure, a very small amount of yellowish fluid mixed with blood oozed out, but there was no pure blood to be seen.

A piece of tissue taken from the centre of the tumor was hardened in

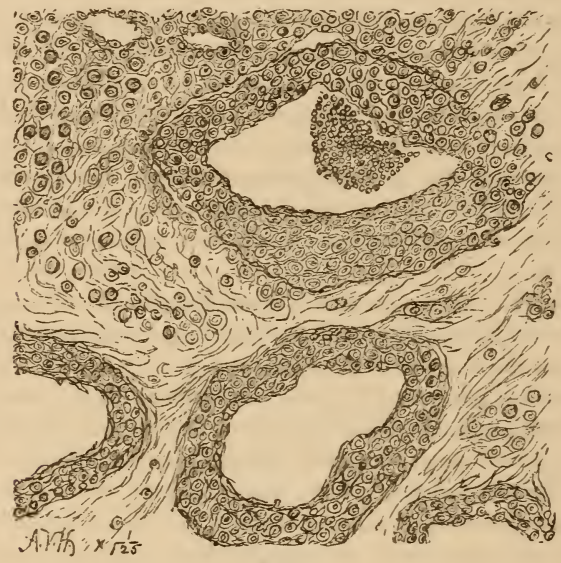

Fig. 10.

a weak solution of chromic acid and alcohol, and in the form of thin sections submitted to the microscope. With a low power an irregularly-formed tissue is seen, characterized by bands of structure of various size, shape, and distribution, which are present in all parts of the field, constituting a large part of the growth. These bands are made up of connective-tissue elements, and comprise the reticular work already referred to as seen with the naked eye. It is at once observed that much of this meshwork consists of blood-vessels which have been cut in the section, some evenly and others obliquely, giving rise to a number of appearances, and which go to render the tissue so ununiform. These blood-vessels are pres-

ent in all sizes, some still containing coagula of blood, while others are empty, their walls alone being seen as rings of connective tissue; some have collapsed, while others have retained their naturally distended form, giving a net-like look to the structure. These openings are larger and more developed in some parts of the field than in others.

In addition to this mesh-work of vessels, there is another element in the growth, of almost equal importance and interest. In these bands and rings and throughout the whole tissue there exists an active and abundant cell-formation, which may be seen permeating all parts of the tumor, and which has a large share in the growth as seen at the present time. These cells are for the most part round or roundish, contain a large nucleus, and vary greatly as to uniformity of size. They are crowded together in places, and are very numerous everywhere in the field. They are imbedded or seated upon a light, delicate connective tissue, from which they appear to spring. They may be seen invading the walls of the blood-vessels, where they produce an altered and abnormal appearance, destroying their sharpness of outline and changing their usual conformation. In certain fields the cells may be noticed collected together or arranged in strings, like so many spores of a fungus. The interest which concerns this little tumor rests with the results of the microscopic examination. Clinically, it was judged to be a simple vascular tumor or angeioma, of the cavernous variety; the view of its being of a sarcomatous nature never having been entertained, and yet the microscope reveals this element in a marked degree. Viewed simply as a microscopic specimen, apart from its gross physical or clinical appearances, it might with almost equal justice be ranged either among the sarcomata proper or with the angeiomata.

In certain examples of sarcoma the vascularity is quite extensively developed, the veins especially being enlarged; but in most cases this condition does not exist, the vascular structure being of secondary importance. In the tumor under consideration the veins, arteries, and capillaries appear, however, to be too largely and conspicuously developed to be viewed in the light of a secondary formation. The walls of the vessels, which we have seen to be infiltrated with cells, also show the vascular elements to be of earlier date than the cells, which seem to be just beginning to invade these structures. From these facts, there can be no question but that in the case before us we have an angeioma of the cavernous type, in which has developed, as a secondary formation, round-celled sarcoma.

Dr. R. M. Bertolet agreed with Dr. Duhring in his idea as to the relation of the two conditions, the vascularity and the subsequent sarcomatous degeneration. As to the other view, which would make it a sarcoma

originally, in which we have this development of huge blood-vessels later, he did not think it so reasonable. It is true that some of the cases of *fungus hæmatodes* are examples of extremely vascular sarcoma, but such tumors are generally much more rapid in their growth, and present other characters different from those of the angeioma. The nævi or mother's-marks upon the skin are very liable to be developed into some form of angeioma, which may remain innocuous for a long period, but if there is a rapid and multiple development of pigmented growths upon the skin, the probabilities are that we have to deal with melanotic sarcomata.

June 11*th*, 1874.

---

6. *Sebaceous cyst from the temporal region.*

By Dr. John Ashhurst, Jr.

This cyst, which belonged to the *cutaneous proliferous*, or so-called *sebaceous* variety, had unusually thick walls, and was readily removed, by enucleation, from a boy about ten years old. *December* 10*th*, 1874.

---

7. *Lipoma.*

By Dr. John Ashhurst, Jr.

This large fatty tumor was removed from the left infra-mammary region of a male adult. The growth was, as is usual with tumors of this nature, surrounded with a distinct capsule, which sent off prolongations, forming septa which separated the several lobes of the mass.

January 14*th*, 1875.

---

8. *Lipoma.*

By Dr. H. Allen.

The specimen was removed from A. D., æt. 45, who noticed a wart-like growth from the left popliteal space twenty years ago. The tumor was distinctly pedunculated, and was about the size of a duck-egg. It was

without pain; the only annoyance its presence gave the patient arose from its liability to contusion. *June* 10*th*, 1875.

Report of the Committee on Morbid Growths:

"The tumor is a simple lipoma, with a denser aggregation of fibrillated tissue towards one end." *June* 24*th*, 1875.

---

9. *Solid enlargement of the bursa patellæ.*

By Dr. John Ashhurst, Jr.

This specimen was removed from a young woman who had been suffering from the affection for more than a year. The great density of the tumor rendering it evident that any less radical mode of treatment would be useless, the growth was excised, its careful dissection from the subjacent tissues being much facilitated by the use of Esmarch's bandage. An incision into the mass after its removal showed a cyst-wall nearly half an inch thick, and of almost cartilaginous hardness, the fluid contents of the cyst consisting of a small quantity of a thick, synovia-like liquid.

June 10*th*, 1875.

Report of the Committee on Morbid Growths:

"The body removed by Dr. Ashhurst is evidently a proliferating mass of connective tissue springing from the synovial membrane. It is everywhere fibrillated, with the exception of a few points where it is hyaline, and encloses the characteristic mother- and daughter-cells of cartilage."

June 24*th*, 1875.

---

10. *On the anatomical differences between carcinoma, sarcoma, etc.*

By Dr. John Ashhurst, Jr.

In a verbal communication upon this subject, Dr. A. prefaced his remarks by saying that after the last meeting of the Society he had found from a conversation with Dr. Tyson that what he had said upon this topic had been misunderstood, and that he thought it right therefore to recur to the subject, and to try to make plain what he considered were the points relied upon by modern pathologists in drawing a distinction between these different forms of morbid growths.

Dr. Ashhurst took, for purposes of comparison, the common fibrous and fibro-cellular tumors (*fibroma*), the fibro-plastic or recurrent fibroid tumor (*spindle-celled sarcoma*), and the scirrhous or hard cancer, which might be considered a typical *carcinoma*. Illustrating his remarks by diagrams drawn upon the blackboard, Dr. A. said that the fibroma and sarcoma were both tumors of the connective-tissue type, but that in the former the *intercellular substance* was at a maximum, there being very few if any *cells* (connective-tissue corpuscles) to be observed, and these, perhaps, only rendered apparent by the application of acetic acid, while in the latter the cells were at a maximum, and the intercellular substance at a minimum; still, no matter how rich a sarcoma might be in cells, an intercellular substance was invariably present, and with this the cells were in *constant relation*, this being, indeed, the distinctive difference between the sarcoma and the carcinoma. In the latter there was a distinct *stroma*, which might itself be a new formation,—the stroma of encephaloid often contains spindle-shaped cells,—or, as in the case of many scirrhous growths, might be simply the connective tissue of the part in which the carcinomatous material was deposited; but, in either case, in the interstices of the stroma cells were massed together *without any recognizable intercellular substance.*

That this, and not the mere presence of a stroma, was the true and only trustworthy distinction between these two varieties of tumor, was shown by the fact that in the so-called *alveolar sarcoma* there was a distinct stroma which might readily mislead the observer into supposing that he had before him a true carcinoma, and that the real nature of the growth could only be recognized by perceiving that in the alveoli the cells were in constant relation with an intercellular substance. On the other hand, when in any part of a sarcoma the development of cells was so rapid as to cause the disappearance of the intercellular substance, that portion of the growth became truly carcinomatous, and the whole tumor was then called a carcinomatous sarcoma.

In concluding his remarks, Dr. A. said that though fully recognizing the desirability in a scientific point of view of having an accurate anatomical classification of morbid growths, and though acknowledging the great convenience attaching to the use of the term sarcoma, he yet thought that it was too indefinite, in view of the varied significations given to it by different authorities, to merit general adoption by practical surgeons.

June 10*th*, 1875.

11. *Two specimens of epithelioma of the lip.*

By Dr. C. B. Nancrede.

The patient from whom the first specimen was removed, E. B., 78 years of age, first noticed, six months ago, a hard lump on the left side of the upper lip. He has been a great smoker, using a clay pipe. About four months ago ulceration commenced, rapidly progressing, and producing an excavated, deep, painful ulcer, with indurated edges, in size about that of a nickel cent.

It had been cauterized frequently by his physician, with nitrate of silver, which had only aggravated the trouble. The patient's general health was excellent, with no arcus senilis, or atheroma of the arteries. His heart-sounds were strong and normal, his hair luxuriant. There was nothing of special interest about the operation, which has proved, thus far, successful, it having been performed the 2d of February, 1875.

The second specimen was removed from W. B., æt. 78 years, who first noticed about six months ago a small wart-like projection on the left side of the lower lip, which grew rapidly, soon ulcerating and occasionally throwing small pieces off in the form of sloughs. No treatment was attempted till he came to me, when I found a mass, about the size of a chestnut, occupying a third of the free surface of the lip, ulcerated and covered with scabs.

When first seen, on the 22d of February, 1875, its removal by the knife was advised, which operation was performed two days later with success so far.

There is one point of interest in connection with the first case,—viz., the occurrence of true epithelioma on the upper lip, where rodent ulcer is much the more frequent.

I should like to hear some expression of members as to the origin of epithelioma, whether it be a hypertrophy of granular tissue, a return of the follicles to the fœtal state, or whether the more recent view of Köster of the endothelial origin is to be preferred.

Dr. James Tyson said he could not speak from personal investigation of specimens bearing upon this question, but, from a somewhat careful examination of the observations of others, he felt that while at first thought the formation of cylinders was best explained by their origin in re-solidification of the sebaceous follicles,—a return to their fœtal state, as Dr. Nancrede expressed it,—he did not see anything in the way of admitting also Köster's view with regard to the extension of the epithelial protrusions

along the interior of the lymphatic vessels, and thus allowing both modes of origin. Some of the members were probably familiar with some comparatively recent observations by Dr. Woodward, of the Army Medical Museum, which tend to support Köster's views.

Dr. R. M. Bertolet said that the theory of an endothelial origin of epithelioma, as advanced by Köster, was very enticing, and that formerly, having used the nitrate-of-silver staining in a number of fresh growths, he was inclined to adopt this view, but, upon closer investigation, he found it inadequate to account for all of the alterations ordinarily met with in this class of tumors. The glandular apparatus of the skin in cases of epithelioma is so manifestly hypertrophied, there is, evidently, such an active proliferation of the epithelial lining of the sebaceous and sweat glands, that it is impossible to ignore the fact that they perform an important, if not the chief, *rôle* in the origin of these growths. No doubt the lymphatics serve as convenient spaces for the in-growing cancroid tubuli, and the endothelia then become involved secondarily.

When we examine the analogous cylinder-growths upon the mucous membrane, there is no question but that primarily the mucous glands are solely involved; especially where the new growth assumes, as so often happens, the habitus of an adenoma. Further, we find that the metastatic growths preserve the type of the glandular structure whence the primary growth has sprung; and thus it happens that we come to find, as has been so aptly stated, rectum in the liver.

Owing to the comparative infrequency of metastases into distant organs, the same cannot be as positively asserted of epithelioma of the skin; yet when these secondary growths shall have been more fully studied, he predicted, it would prove that they also presented an imprint of a glandular and not an endothelial tissue. *April 8th*, 1875.

---

12. *Cystic mammary tumor.*

By Dr. John Ashhurst, Jr.

The tumor was removed a few hours ago from an unmarried woman, aged 51. It originated two years since, beginning as a small, hard nodule. Very little pain attended the growth of the mass, which was chiefly annoying from its size and weight. Some portions appear to be of almost cartilaginous hardness, while in other parts large cysts have been developed,

and one of these has ulcerated, discharging a large quantity of sero-sanguineous fluid, and then healing. The tumor was not adherent, and though at the operation it was found to extend around the edge of and to send a prolongation beneath the pectoral muscle, it did not at all infiltrate the adjoining tissues. The tumor appears to be entirely surrounded with a distinct capsule, the solid portions being of firm, fibrous consistence, and the cyst containing a thin serous fluid together with a considerable quantity of a brownish, honey-like substance.

April 22*d*, 1875.

Report of the Committee on Morbid Growths:

"The Committee on Morbid Growths have examined the large mammary cystic tumor presented by Dr. Ashhurst, and find that certain portions of the cyst-wall presented small secondary cystic formations, which were of an irregular roundish shape. These cavities are lined with a cylindrical epithelium, but, instead of being perfectly smooth, have numerous in-growing papillary projections, giving to the transverse sections a peculiar racemose appearance.

"These cysts have originated from dilatation of the lacteal glands and ducts. They are surrounded by an eminently sarcomatous tissue, presenting in alternating preponderance rounding and fusiform cells. The active proliferation of this sarcomatous tissue has caused it to invade the lumen of the lacteal tubes at points completely occluding them, and thus leading to their cystic distention.

The growth, therefore, may be pronounced a *cystic sarcoma*, comparatively rare in this site of the body, yet warranting a much more favorable prognosis than can be made in the carcinomatous varieties."

May 27*th*, 1875.

XI.—MISCELLANEOUS.

1. *The anatomical, pathological, and surgical uses of chloral.*

By Dr. W. W. Keen.

I. ANATOMICAL USE.

In August last, I think, I saw a scrap in a journal simply stating that chloral was an excellent antiseptic. I made no note of it at the time, and almost forgot it till I had a case of caries of the tibia (reported below) in which I desired such a disinfectant, and it occurred to me to try it. The result being satisfactory, when I came on duty at St. Mary's Hospital in October I tried it on a number of cases (some of which are reported below), and then tried the following experiments with it in my office with a view to its possible use in the dissecting-room.

Experiment I.—October 22d, 1873, I placed some mutton with pure water in a bottle, corked it loosely, and stood it on my office table, exposed, say, to an average temperature, day and night, of 65°, as a comparative experiment. In four days it smelt very badly, and in seven was disintegrated.

Experiment II.—Same date. Mutton in a solution of chloral, gr. ij to f℥i of water, and exposed to similar conditions. November 1st (ten days), slight mould. December 8th (forty-eight days), slight smell. December 25th (sixty-five days), entirely decomposed.

Experiments III. to VI.—Mutton placed in similar conditions October 22d, 1873, but in chloral solutions of respectively 5, 10, 20, and 60 grs. to f℥i of water. At this date, March 12th, 1874, 141 days, or nearly five months, they are all perfectly preserved, with no smell save that of mutton-fat and chloral, no mould, no disintegration. A microscopic specimen from that in the five-grain solution is exhibited to the Society, to show that the muscular structure is perfectly preserved, as are also all the others.

Experiment VII.—A condyloma, removed December 24th, was washed for twenty-four hours in water, and placed, December 25th, 1873, in a forty-grain solution. It is still (March 12th, 1874) perfectly preserved, and with the other specimens is exhibited to the Society for inspection.

Experiment VIII.—Feeling encouraged by some success, I obtained a fœtus, still-born at full term, and injected it December 10th, 1873, as follows: one arm, by the brachial artery (precautions being taken of course to limit the injection to the arm), with a five-grain solution; the other arm with a ten-grain solution; one leg, by the femoral artery, with a twenty-grain solution; the other leg with a forty-grain solution; and, by the umbilical cord, the trunk and head with an eighty-grain solution. I used in all two ounces of chloral, and of each solution I injected as much as I could, so that the skin was fully stretched, as if the part were extremely dropsical. I had here a completely comparative experiment, for all the parts of the fœtus were exposed to precisely similar conditions save the strength of the injection. I left it exposed on a table in a room of average temperature of 50° to 60° Fahr. March 10th, just three months later, I examined it carefully. The body appeared perfectly preserved. The skin was shrivelled a little about the finger-nails, lips, eyelids, and scrotum, from evaporation; the toes were as plump as ever; the epidermis was slightly loosened. The head and neck, which were very much congested and discolored when received (a consequence, doubtless, of its being still-born), were of the same dark color, but no decomposition had ensued; and the common toilet-pins with which I had closed the incisions by which I reached the arteries were perfectly untarnished. On opening the parts injected with five-, ten-, and forty-grain solutions, and examining them, they appeared as firm as ever, all of natural color and consistence, and the microscope ($\frac{1}{5}$) showed no change in the muscular structure even with the five-grain solution. In order, however, to have a more careful examination, I gave Dr. J. G. Richardson a scrap of muscle from the ball of the thumb in the five-grain arm, another from the twenty-grain thigh; a slice of the tongue, which, as the mouth was open, had partly dried, but was covered with a cheesy coating (hence, probably, the torula reported below), and a piece of the parotid gland. He kindly examined them with great care, with a $\frac{1}{25}$ in. immersion lens, eye-piece A, giving 1250 diameters, and reports as follows:

A small piece of muscular tissue from the palm of the hand (five grains), teased out in a drop of chloral solution, showed the individual fibres with remarkable distinctness, the transverse striations being unusually well defined, and the whole structure quite free from granular or other degenerative change. (The specimen was shown by the class microscope.)

A similar fragment from the thigh, injected with a twenty-grain solution, was likewise admirably preserved.

A thin section from the tongue exhibited muscular fibres in the same state of complete preservation; and in these, by the aid of acetic acid, the oblong and rectangular nuclei under the sarcolemma were clearly brought into view. A minute shred snipped out from the upper surface of the tongue displayed the filiform papillæ very distinctly, and furnished numerous cells of tessellated epithelium, presenting all the characters of epithelium in a drop of fresh saliva. Multitudes of isolated torula spores and a few short chains of torula accompanied this section.

A thin section from the parotid gland showed the lobules of the glandular tissue almost unaltered, and, on the addition of acetic acid, the usual sharp definition of the nucleus in each gland-cell was obtained.

(An incision was made into one leg, and the above gross appearances were shown to the members.)

I have coated one arm with varnish and the other with rubber dissolved in benzole. I propose, after having exhibited it here to-night, to place one leg in a bag of saw-dust and the other in a bag of sand, and leave the remainder of the body exposed to evaporation during the next few months of hot weather. This will give me the means of determining whether the chloral will preserve the subjects in hot weather and of testing the best means of preventing evaporation. The results I will communicate to the Society in the fall of this year, whether they be good or bad, together with the results of any other experiments.

Experiment IX.—A negro subject was brought to my anatomical school February 23d, 1874, in good condition as to preservation, but with the entire spinal cord removed, one leg off above the knee, and one femoral artery opened. It was therefore a very unfavorable subject to begin on, as so much of the solution must escape through, at least, the small arteries, which were cut. A half-pound of chloral, in the strength of 15 grs. to f℥i of water, was injected by the carotid the same day. The body was placed on the dissecting-table March 2d, and has been almost entirely dissected since then. The cuticle was very firmly adherent. The muscles were of the most life-like color, a little flabby perhaps, but not in the least easily torn. All the other parts, also, were of the natural color, texture, and condition, so that, for example, the aortic and other sympathetic plexuses were readily dissected. The odor of chloral was perceptible, but not at all offensive. March 7th, the viscera were removed, and, instead of the usual fetid odor, which is so annoying, especially from its persistence on the hands, there was scarcely any smell. It was but slightly that of chloral, and was not disagreeable. This was twelve days after the injection. (Specimens shown.)

Experiment X.—A negro died in the city February 18th, and lay exposed during the warm weather we had then till February 28th, when he was brought to my rooms. The cuticle was off over all the chest, which was green and crepitant, and the legs were dropsical. A more unfavorable subject for preservation I have rarely had. Though a large man, I tried the chloral, on February 28th, in the same strength and amount as in the last case, viz.: gr. xv. to f℥i. March 12th,—*i.e.*, twelve days after injection and twenty-two days after death,—the subject is perfectly preserved. The cuticle elsewhere is adherent, the chest is natural in color, the smell is gone, and the specimen of muscular tissue, which I exhibit, though taken from the abdominal walls, the most unfavorable part of the body, is of admirable color and consistence.

The next subject I obtain I shall inject with one-fourth of a pound of chloral, and instead of the ordinary amount of water (a gallon to a gallon and a half), I shall dissolve it in not less than eighteen or twenty pints,—that is, about five or six grains to ℥i; for my short experience seems to show that if the parts are fully and most completely distended they are preserved better, probably because the chloral penetrates more thoroughly into every minute capillary. In order to give a little more firmness to the muscular tissue, I shall also inject a pound or two of starch, dissolved in water and mixed with the chloral solution, and make a future report of the results.

It is important that I should not be understood to claim, as yet, that chloral will answer for the dissecting-room, to the exclusion of everything else. I have not had any experience beyond the mild winter we have so far had, and during a period of five months. What effect the hot weather of summer, with its moisture, will have, I cannot yet say, but hope to do so in the fall. Thus far I can claim for it entire superiority, in the winter-time, for all dissections, and especially for the finer and more delicate ones of the skilled anatomist. Its comparative merits may be summed up as follows:

1. *Cost.*—The price of chloral is about two dollars and fifteen cents per pound; and if one-half or one-fourth of a pound will do for each subject, the cost will be from one dollar to fifty cents for each subject. Chloride of zinc, or arsenic, costs about fifty cents for each subject.

2. *Condition of the tissues.*—Zinc hardens, discolors, and decolorizes the tissues to such an extent that, for both dissection and operative surgery, they are rendered totally unfit to give a student the proper notion of their normal color and consistence. Besides this, many parts, such as the axilla, with its entanglements of blood-vessels, nerves, muscles, glands,

etc., important to be well dissected, are in such a discolored, dirty condition as hopelessly to bewilder the most earnest student. Alcohol is better than zinc, but it also hardens and decolorizes. Arsenic, also, is better, but the tissues become very soft and offensive in a little while, besides the frequent annoyance of local poisoning about the fingers. Salt and nitre subjects have the same objections (except the poisoning), and also nearly always mould in a short time. Chloral keeps the color perfectly, and the parts are of their natural consistence for at least three months, and probably much longer. By this means far more delicate and useful dissections can be made, and the student has a correct idea of the condition of the parts just as they were in life.

3. *Subsequent injections* into the arteries, etc., can be made with far better effect, since none of the arteries are at all contracted as they are by the astringent action of zinc; and the injection will therefore penetrate much farther.

4. *Permanent preparations.*—I have not yet had time to try this question, and so I do not know how it may act as to heat, moisture, vermin, etc.; but so far as finer dissections and finer injections are concerned, it would seem to promise well.

5. *Odor.*—The chloral odor, in a single subject, is not strong enough to be disagreeable, but how it may be with a roomful of them I am not prepared to say. I intend, however, to try the effect of some of the essential oils, such as cloves, bergamot, rosemary, etc., or a mixture of them; for a fragrant cadaver may entice some otherwise indifferent students to a more thorough study of its texture and tissues.

6. *Instruments and clothing.*—The destructive action of zinc* in dulling the edge of the best knives, and thus worrying the dissector by the constant use of the hone, or more frequently making him careless and slipshod, is well known. Chloral does not affect the knives in the least; and even toilet-pins, after three months in the subject (Exp. VIII.), were not corroded in the least.

II. PATHOLOGICAL USES.

Besides the experiments detailed above, I asked Dr. Richardson to examine some pus, which I obtained from the Philadelphia Hospital, through the kindness of Dr. Miller, on March 4th, 1874. The following is his report, the examination being, as before, with the $\frac{1}{25}$:

---

* Zinc being our most common injecting material in Philadelphia, I use it mainly for comparison.

"*Experiment XI.*—A specimen of pus from an acute abscess, preserved for six days in a five-grain solution of chloral, contained multitudes of well-formed pus leucocytes, numerous dead (at least motionless) Bacteria from $\frac{1}{20000}$th to $\frac{1}{2000}$th of an inch in length, and considerable quantity of granular matter.

"*Experiment XII.*—A specimen of pus preserved six days in a twenty-grain solution presented precisely identical appearances; and since the Bacteria were about equally numerous, it seems probable that they had developed in the purulent fluid *before* it was mingled with the solution of chloral. On adding acetic acid or aniline to these specimens of pus, the ordinary reactions were manifested,—*i.e.*, the brightening of the nuclei or tinging of the nuclei and the cell walls."

My own examination coincided with his.

Experiments XIII. and XIV.—I examined pus from a chancre, and also pus from an ulcer, with precisely similar results.

These experiments, as well as those given before, but especially the microscopical results as determined by Dr. Richardson and myself, at once suggest the query whether chloral in solution may not replace alcohol in the preservation of permanent wet preparations in our anatomical and pathological museums. It will be observed that the solutions varied from five to eighty grains in strength; the specimens were mutton, a condylomatous tumor, human muscular, epithelial, and glandular tissues, pus from an abscess, an ulcer, and a chancre; the time varied from six days to one hundred and forty-one days; the conditions were unfavorable for their preservation: yet not only were they all preserved macroscopically, but even the delicate cellular tissues were preserved microscopically; and, further still, the Bacteria already developed were killed even by a five-grain solution. Whether this preservative power will hold good for all sorts of wet preparations, for a longer time and in hotter weather, I do not yet know, but it will certainly do so for those named for five winter months, and probably longer.

If we can use it in place of alcohol we gain very greatly, first, in the lessened expense; for a solution of ten or twenty grains to the ounce is far less expensive than alcohol, and the bottles, instead of being hermetically sealed, need only be closed by glass stoppers, or even by ordinary corks. Secondly, this renders them entirely accessible for study at any time, whether in investigating any particular subject or specimen or for exhibition to a class; and any teacher who has used permanent preparations, hermetically sealed in expensive bottles, which cannot be passed from hand to hand, which are distorted by the refraction of the liquid and

the round glass, and not to be got at to examine accurately what we wish to study, well knows how comparatively useless they now are, and how useful they will be if chloral should make them accessible. If evaporation take place, the solution is meantime becoming stronger, for only the water and not the chloral evaporates; and an annual or semi-annual inspection of the museum, with the addition of either water or the chloral solution, will remedy any such trouble. I do not think that chloral in solution changes chemically within at least a year. I have used in some of my experiments solutions in water nearly six months old, and have had patients take the syrup from an old bottleful obtained a year before, without any perceptible change in its action.

In pathological investigations of various fluids, such as pus, urine, blood, the fluids in dropsy, etc., a few grains put into the fluid may be sufficiently preservative, and enable us to keep them for a much longer time for more careful observation. I would suggest that about five or ten grains to an ounce of the fluid would be enough; and it would be better to add it in crystals, for if added in solution it might change the specific gravity of the fluid, and so affect the integrity of the more delicate morphological elements. I would also suggest whether a solution of proper density—varying with the objects to be preserved—might not be of great service for mounting microscopical preparations. Neither of the last two suggestions have I tried myself, except with the pus, which has kept perfectly for eight days; but both are, I think, well worth the trial.

III. SURGICAL USES.

When I commenced my investigations into the action of chloral, I had seen nothing published but the little scrap which filled out a column in a journal, although since then I have seen several notices of its surgical applications.* Yet, as my observations are independent in character, confirm the results obtained by others, and show the value in surgery of a remedy as yet new, I venture to append a few of the more striking cases in which I tried it; in some with good results, in others bad. It acts, first, as a complete deodorant within a very short time, by what chemical action I do not know; secondly, as a stimulant, so that what was a foul, sluggish ulcer will become, in from two to three days, a fine, red, healthy, granulating sore. But it must not be used too strong, or it may become a decided

* London Lancet, August 30th, 1873, p. 311; Amer. Jour. Med. Sci., October, 1873, p. 531, and January, 1874, p. 261; Med. News and Lib., February, 1874, p. 27; Phila. Med. Times, February 19th, 1874, p. 326, etc.

irritant, as any one who has ever taken a dose would naturally expect. I have generally found that gr. x to f℥j of water (or, in private practice, some fragrant water) is quite strong enough. In some cases even this, which is about a two per cent. solution, is too strong, and has to be diluted. The results of the cases below were most marked in those with foul, unhealthy, ill-smelling discharges, which were changed quickly to healthy-looking sores, with excellent and yet moderate, not abundant, pus. In fact, in every case the discharge was, I think, considerably diminished. I did not find, I think, that the sores healed any more rapidly than they ordinarily would. The application seemed rather to change an unhealthy sore which was stationary, or even enlarging, to a healthy one, in the proper condition for the healing process, which soon began and went steadily forward. In no case was its hypnotic action shown.

Whether it will at all destroy the specific poisons, such as that of a chancre, I do not know, for I had no opportunity to try it in the hospital. That it would do well in open buboes, as ulcers, I have no doubt; but the best test as to its possible destructive powers on the virus would be to try the auto-inoculability of a chancre which had been treated by chloral dressings.

I have found the mucous membranes also, as would naturally be supposed, more sensitive to its irritant properties than the skin, but not so much so in some cases as would be expected. In fact, I think it must be tested by experience in each individual case.

Cases I. and II.—One, a case of long-standing caries of the tibia, with very ill-smelling discharge; the other, of caries of short duration, but equally bad discharge. I used the chloral (gr. x to f℥i) both as an external application, by which alone nearly all smell was prevented and discharge diminished, and later, in the same strength, as an injection into the sinuses. The injection did not irritate, but yet did no appreciable good other than the external application had already done, though continued for nearly a month.

Case III.—A case of psoas abscess (in which for four years the woman had worn a truss by a physician's direction, for a supposed hernia!). On admission, the abscess was discharging, in the groin, a very offensive pus in large quantities. A ten-grain solution was applied externally, and the odor completely disappeared at once, greatly to her own comfort, as well as that of the other patients in the ward. The discharge also certainly lessened, but I scarcely think it could be from the external application. It must have been from some other cause. As other injections had proved

irritating, and she was rapidly sinking, I did not try the effect of an injection of chloral.

Cases IV. and V.—Two cases of large, filthy, and foul ulcers of the leg. I used a ten-grain solution as both a wash and a dressing; in one case mixed with a poultice, in the other simply by a compress, wet with the solution. The poulticed case did so well that all smell disappeared, the ward was freed from its previous contamination, and the ulcer did well. In the other case I had tried transplantation of skin, and four out of seven grafts had taken root. The continual application of the ten-grain solution on the compress was certainly too strong, for it not only destroyed the skin-grafts, but irritated the adjacent skin considerably. Generally, however, I have not found the constant dressing with the ten-grain solution too strong.

Case VI.—Rupial ulcers, of about the same size, on the leg and arm. As a comparative test, I applied a ten-grain dressing of chloral to one, and touched the other with nitrate of silver, dressing it with simple zinc ointment. They did about equally well.

Case VII.—This was, I think, the best test of all, so far as the deodorizing properties of chloral are concerned. I do not say *disinfectant properties*, for I suppose that this is a question for the chemist rather than the surgeon. A young woman was infected by her husband with syphilis, and then he attempted a mercurial treatment. He so far succeeded that when she entered the ward, as I was making my visit, I found half of the teeth out, the rest ready to drop out, the gums sloughing everywhere, and necrosis both of the upper and lower jaw so far progressed that the upper jaw was loosened from all of its attachments. The smell was, I think, as bad as any I ever encountered, and the whole ward was filled with it in a very short time. I gave her a ten-grain solution of chloral as a mouth-wash, and on my visit the next day I could approach within six or eight inches before I was conscious of any odor. Yet the cause of the smell was constant, and the use of the wash intermittent. It was so grateful to her that she used it every fifteen or twenty minutes. The remaining healthy mucous membrane was not irritated. No hypnotic effect was visible from either absorption or the small amount probably swallowed.

Case VIII.—Gonorrhœa. In only one case of this kind have I tried chloral. I directed a one-grain solution, which so irritated the urethra that the patient would not allow its further use; but he was nervous about it, as I had inadvertently told him what I intended to use, and I scarcely trust his report. Parona,* however, reports an extensive use of it since

* Med. News and Lib., February, 1874, p. 27, from Med. Times and Gazette, January 3d, 1874, from Giorn. Ital. della Mal. Vener., October, 1873.

1870, in men and women, with the best results, in a strength of one per cent., *i.e.*, about 5 grs. to f℥i.

My friend Dr. Macpherson has tried it in several cases, and reports to me as follows:

Case IX.—Cauliflower excrescences of os uteri, with large hemorrhages and great fetor. During thirteen months he had tried numerous remedies. The only effective deodorant was potass. permang., and this, even in so weak a solution as gr. ½ to f℥i, would irritate the parts so as to re-establish bleeding. He used chloral, gr. v to f℥i. The odor was at once destroyed, no bleeding resulted, the discharge lessened greatly, and changed its character to good healthy pus; pain was relieved, and she became able to walk about in ten days.

Cases X. and XI.—Both of long-standing ozæna in scrofulous subjects. A solution of ¼ gr. to f℥i, by the nasal douche, proved irritating, and they were indisposed to allow further trial.

Case XII.—Syphilitic condylomata on the penis. The smell was almost intolerable from the mingled odors of the smegma and the condylomata. After washing with water, a ten-grain solution of chloral was applied, and the odor entirely removed. A slight balanitis occurred, which subsided on reducing the solution to 5 grs. The warts were removed, chromic acid was applied, chloral being used as a dressing, and the patient was well in four days, except one very small spot, which soon healed.

Case XIII.—Non-specific severe vaginitis in a child four years old, of strumous constitution. An injection and wash of 4 grs. to f℥i was used, and no other treatment, and in two days the patient was nearly well.

Dr. Wm. Goodell also informs me he has used it considerably of late, and it does admirably as an antiseptic, deodorant, and stimulant.

March 12*th*, 1874.

---

2. *Wad of paper and cloth removed from lacerated wound of the leg.*

By Dr. J. Ewing Mears.

The mass consisted of paper and cloth, which had been fired from a small cannon, one and a half inches in bore, and which at a distance of forty feet produced a lacerated wound of the leg in a patient who was admitted to St. Mary's Hospital. *September* 23*d*, 1874.

3. *Supernumerary toe.*

By Dr. Jno. Ashhurst, Jr.

This was removed from an infant of eight months. The deformity affected the left foot only, the superfluous digit growing inwards from near the base of the great toe. *December* 10*th*, 1874.

---

4. *So-called hermaphroditism.*

By Dr. John M. Keating.

The specimen was referred to a special committee, consisting of Drs. Keating and Harrison Allen, for report. The committee reported, January 28th, 1875, as follows:

"Your committee to whom was referred the specimen of hermaphroditism exhibited by Dr. J. M. Keating, on January 15th, 1875, have to report that, upon examination, the *uterus* and ovaries were found in position, not presenting any abnormal conditions in regard to shape and development. Immediately in front of them was seen the bladder, much contracted by the action of strong alcohol used to preserve it: it had assumed the character of a solid tumor before it was opened. *Ureters*, although somewhat torn, were easily traced, a probe passing readily through them. The relations of the urethra were normal. After careful search, neither testicles nor any trace of them were found within or without the abdominal cavity. Externally, the labia were much enlarged. The clitoris, though probably much contracted by the strong alcohol, was about the size of the penis at term. The anterior orifice of the vagina was obliterated by a true integumental growth, which was continuous with that of the perineum.

"Your committee therefore conclude that the specimen belongs to the class of spurious hermaphrodites characterized by the presence of true female organs conjoined with excessively developed external organs and imperfect development of the vagina.

"Harrison Allen,
"Jno. M. Keating."

5. *Monstrosity. Case of malformation of the nose.*

By Dr. Ferdinand H. Gross.

The monstrosity is the body of a male child born at term with a peculiar malformation of the nose. The organ consisted of a mere cylindrical fleshy tube starting out from between the eyes or the position of the root of the nose, its dimensions being a little over an inch in length and about half an inch in diameter. There was no cartilage of the septum nor columna, and instead of the two anterior nares there was but one small round opening or canal. It was quite soft and flexible, and bore a resemblance to the male organ of an infant.

The case came to my notice under the following circumstances: On the previous day, while visiting a case of frost-bite in the house of a midwife, she informed me that on the same morning a German woman, the wife of a butcher, had been unexpectedly taken with strong labor-pains while standing at her stall in the market, and that there had been only time enough to get the woman into the house of the midwife, which was in the neighborhood, when she gave birth to this child. She reported that it showed signs of life immediately, that it cried, breathed imperfectly for nearly an hour, and then died. The body was quite livid when first shown to me, and the cause of death was no doubt asphyxia.

The mother was twenty-four years of age, and had borne four healthy children.

The specimen was referred to a special committee, consisting of Drs. F. H. Gross, Harrison Allen, John Guitéras, and John M. Keating, for examination and report. *January* 15*th*, 1875.

Report of the Committee appointed to examine the specimen of imperfect-cyclops monster presented by Dr. F. H. Gross:

"Your committee beg leave to report that upon examination they found that the specimen was an example of the deformation known as the *ethmocephale* of Saint-Hilaire, the exact position of the specimen being, it was thought, in close connection with the cyclops group of monsters.

"The body was that of a male child at full term. It presented nothing unusual apart from the head and face, to which your committee's remarks will be confined.

"The forehead was much contracted from side to side, and presented a single frontal protuberance. The palpebral fissures were approximated, each fissure measuring five lines in length, and directed slightly downwards

and outwards. The space between the eyes was nine lines in width, and was occupied by the base of the nose. The latter organ was the most re-

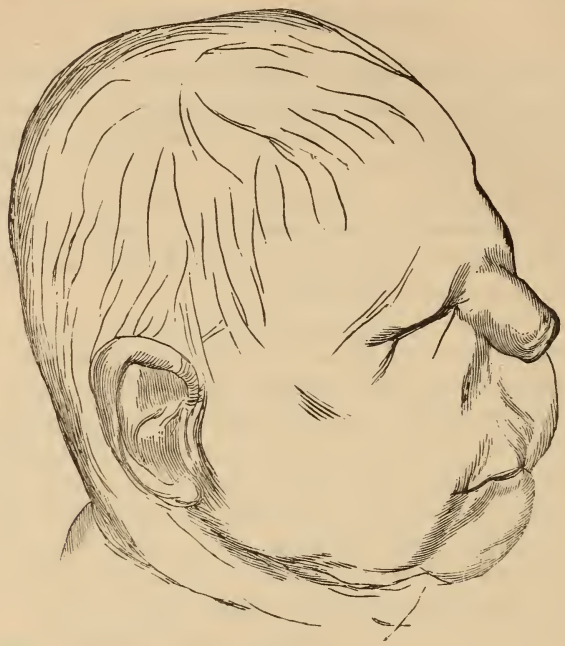

Fig. 11.

View of the Head before Dissection.

markable feature of the specimen. It consisted of a tubular proboscis-like organ, which measured eleven lines in length along its upper surface, five lines in length along its lower, nine lines in width at the base, and five and a half at the tip. It was flexible, covered throughout with integument, presented a single sub-rounded nostril, having somewhat tumid margins, which, towards the middle, both above and below, slightly projected. The interior of this organ appeared to be a *cul-de-sac*, without communication with the mucous membrane.

"The lips were well formed, the oral fissure measuring ten lines in length. The upper margin of the fibres of the orbicularis oris muscle was defined by a well-marked wrinkle. The space between this and the base of the nose was smooth, measured nine lines in height, and was continuous with the cheek surfaces.

"Upon removing the calvaria, it was found that the brain-case was not entirely occupied with the brain, the top of the cerebral hemispheres fail-

ing to reach the sagittal suture by one inch. Its appearance was, moreover, remarkable by the failure of the posterior cerebral lobes to overlie the cerebellum. The sides of the longitudinal fissure at its posterior part were widely divergent, disclosing the *velum*. The space not occupied by the brain was filled with a thin serous fluid. The dura mater sent no folds between the encephalic masses; so that the great falx and tentorium were absent. There was, of course, no longitudinal sinus.

"When the brain was removed, the dura mater was seen lining the base of the skull in the usual manner, so far as the posterior and middle cerebral fossæ were concerned. That lining the anterior cerebral fossa presented a smooth surface, not interrupted by any eminence which would indicate the position of the *crista galli*. The transverse diameter of the

Fig. 12.

THE BRAIN VIEWED FROM ABOVE.

a. The cerebellum.
b. Corpora quadrigemina.
c. Probable position of the optic thalamus.
d. The median sulcus.
e. The occipital lobe.
f. The first posterior transverse convolution.
g. The first anterior transverse convolution.
h. The parieto-occipital fissure.

anterior cerebral fossa was one inch and ten lines. There was no appearance of olfactory grooves or cribriform plate.

"Viewed from above (Fig. 12), the encephalon presented the following appearances: The cerebellum (*a*), corpora quadrigemina (*b*); and optic thalami (*c*) were exposed; the cerebrum terminating four lines in advance of the cerebellum. The cerebrum was imperfectly divided into two hemi-

spheres. The longitudinal fissure was represented by a median sulcus (*d*) measuring nine lines in length, which did not extend downwards to a corpus callosum,—this commissure being entirely absent; nor did this sulcus differ in any respect from those elsewhere seen on the cortex. The occipital lobes (*e*) were not approximated; indeed, it was by their want of approximation that the optic thalami and corpora quadrigemina were seen.

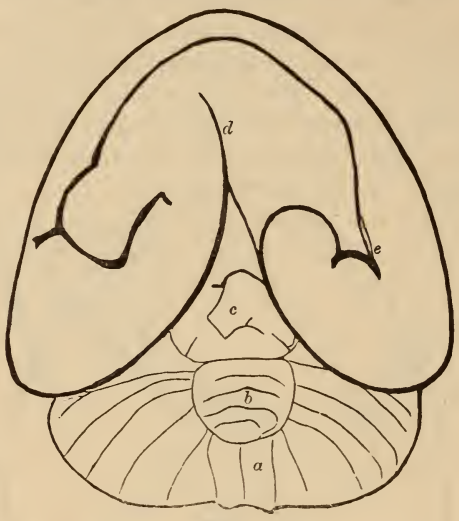

Fig. 13.

THE BRAIN VIEWED FROM BELOW.

a. Medulla oblongata.
b. Pons Varolii.
c. Infundibulum.
d. Inferior median sulcus.
e. Fissure of Sylvius.

"Viewed from beneath (Fig. 13), the encephalon presented a normal medulla oblongata and pons. There were no mammillary bodies. The under part of the mass, answering to the conjoined thalami, (?) presented a conspicuous infundibulum (*c*). The posterior perforated space was absent; the two anterior were conjoined into a central space placed in advance of the infundibulum. In front of the latter space was a median sulcus, measuring seven lines in length. The olfactory nerves were absent. The position of the optic tract was obscurely defined. No trace of a chiasm was seen.

"The general aspect of the cerebrum led your committee to determine the significance of its malformation to be as follows: that at an early period in the history of the fœtus, at a time when the hemispheres were

about to be discerned, the development of the mass was arrested. A decided attempt at a symmetrical division of its parts was announced, which, however, was not successfully attained in many parts of the cerebrum: thus a right and a left hemisphere were recognized, united by two conspicuous transverse convolutions in front, and by two shorter and less conspicuous convolutions behind. The superior median sulcus was terminated posteriorly by the first posterior transverse convolution. The first anterior transverse convolution presented upon its upper margin a pyramidal offset, which abruptly arose, and was lodged within the superior sulcus, bifurcating it in front.

"In the right cerebral hemisphere the fissure of Sylvius began about a line above the level of the anterior perforated space, and ascended less than half the way up the side of the hemisphere. In front of this fissure were the transverse convolutions, the fissure joining the sulcus between them. Behind it was a large smooth surface which answered pretty nearly

Fig. 14.

PROFILE VIEW OF THE BRAIN SEEN FROM THE RIGHT.

a. Anterior superior transverse convolution. *c.* The posterior superior transverse convolution.
b. Superior median sulcus. *d.* The parieto-occipital sulcus.
e. The occipital lobe.

to the posterior half of the hemisphere. The fissure of Rolando began at the anterior border of the superior median sulcus, with which it was continuous, and extended downwards and outwards to the end of the first anterior transverse convolution. The position of the parieto-occipital sulcus was marked by a wide fissure, bounded in front by the posterior superior transverse convolution, and behind by the occipital lobe.

"The left cerebral hemisphere presented a fissure of Sylvius which began at the level of the anterior perforated space, and did not ascend the side of the hemisphere, but was deflected forwards and inwards, to be continuous with the sulcus between the two anterior transverse convolutions.

"The fissure of Rolando passed outwards and backwards, not parallel with the median sulcus, but outwards along the side of the hemisphere to the first anterior transverse convolution. The parieto-occipital sulcus was less deep than that on the right side, but wider. About the posterior third of the hemisphere, below, and at its sides, no convolutions were seen.



Fig. 15.

PROFILE VIEW OF THE BRAIN SEEN FROM THE LEFT.

a. Parieto-occipital sulcus.

"These features represented, it was thought by your committee, the most important points of the superficies. Of minor value would appear to be the presence of a conspicuous sulcus upon the upper surface of either hemisphere, which on the right side joined the fissure of Rolando in front and at its termination, and extended backwards and nearly parallel to the median sulcus, to terminate in the occipital lobe by a Y-shaped flange. A similar sulcus on the left side had no connection with the fissure of Rolando anteriorly, but extended backwards and outwards to terminate in a similar manner with that of the right side.

"Two other sulci were seen, which were not symmetrical: the one on the right was a little depression about the middle of the side of the hemisphere; the one on the left, somewhat larger, seen upon the upper portion of the occipital lobe.

"It will be observed that all the parts are better developed upon the left than upon the right side.

"The interior of the cerebrum was a simple cavity, without any attempt apparent at the formation of *fornix*, *corpus callosum*, or *septum lucidum*. No prolongations were seen in the position of the olfactory nerves. Posteriorly, the cavity was continuous, with a *cul-de-sac* about seven lines in depth, apparently formed by the doubling of the cerebral tissue at that point; and the fold thereby made determined the posterior inferior border of the hemisphere. This *cul-de-sac* your committee took to be in the position of the future middle horn of the lateral ventricle.

"A longitudinal section of the skull was made a little to the right of the

median line; yet so narrow was the pre-sphenoidal portion of the body of the sphenoid bone that the section was directed through the right optic foramen, where an optic nerve was found in position.

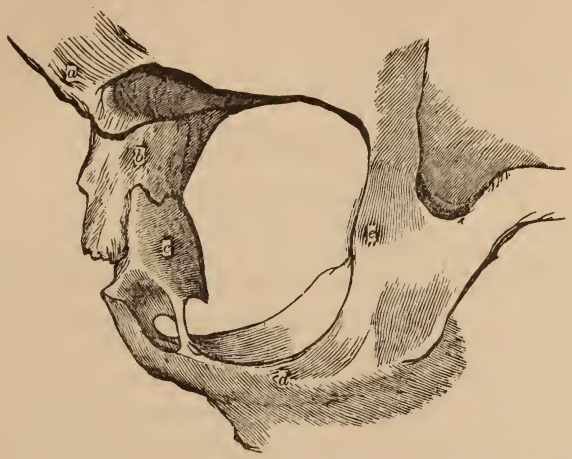

Fig. 16.

PROFILE VIEW OF THE IMPERFECT INTER-ORBITAL SEPTUM SEEN FROM THE LEFT.

a. The frontal bone.
b. The ethmoid bone.
c. The lachrymal bone.
d. The superior maxilla.

"An osseous column was now displayed, which extended in the median line from the frontal bone to the intermaxillary bone, and which was thought to answer to the associated ethmoid and lachrymal bones. No trace of the vomer could be found. The above mass measured six lines in height, six from behind forwards, and three in width. It formed an imperfect septum between the orbits, which served to separate these cavities anteriorly only, while posteriorly the eyeballs were surrounded by a common mass of fatty tissue and muscle.

"The section exposed the dental sacs. The left half contained almost the whole of the palate, presenting anteriorly an intermaxillary bone, the outline of which was well marked on the upper or orbital surface. This surface terminated in an anterior nasal spine. This latter process was much more pronounced than is normal, or rather the intermaxilla was deeper than normal, by which the process in question was raised above the level of the orbits. The outer walls of the orbits were normal. The floor was common to both, and was formed by a coalescence of the orbital plates of the superior maxillæ with the intermaxillæ. The infra-orbital canals were in position.

"The hard palate terminated posteriorly in a normal velum. There was no room for the posterior nares: in fact, in their place was found a mere pouch of mucous membrane between the two pterygoid processes, extending below into the velum and above into the roof of the pharynx. The Eustachian tubes were in position. At the line of junction of the nasal columns with the frontal bone (Fig. 16, *a*) there was on either side a foramen transmitting a nerve which was traceable into the cranial cavity. Your committee would take this nerve to be the nasal branch of the ophthalmic. This fact alone led them to conclude that the upper portion of the septum consisted of the ethmoid bone (*b*). The latter structure presented in the median line an imperfectly developed vertical plate, and on either side, appearing respectively in the right and left orbits, was an irregular mass of bone, which represented the lateral mass. This articulated above with the frontal bone, and below with the lachrymal (*c*) of its own side. Each lateral mass inclined towards its fellow, so that the two touched behind their entire length, forming the posterior free edge of the upper half of the column. The plates were also approximated in front, at their upper portions, but were slightly divergent below, to define, with the aid of the lachrymals, an opening which answered in position to the nasal chambers, within which was seen the lumpish perpendicular plate. The lower bone of the septum on either side was undoubtedly the lachrymal. It presented on its outer surface a marked groove which was completed by the ascending portion of the intermaxillæ. On the left side the groove was better marked, the posterior inferior angle of the bone being prolonged into a hook-like process which was attached by ligamentous union to the upper surface of the intermaxillæ. The anterior inferior angle of the bone was attached to the nasal spine of the intermaxillæ. The lachrymal bones converged and touched behind, to form a sharpened edge, which constituted about the lower half of the posterior border of the nasal column. Anteriorly, the bones aid in defining the lower portion of the lateral walls of the nasal chamber. The integument lining the proboscis-like organ was evidently continuous with the true skin-surface, but had united with the parts above described so far as to have entered and been held in close connection with the interior of the rudiment of the nasal chambers.

"The thoracic and abdominal viscera were normal. A section of the lungs floated in water.

"F. H. Gross,
"Jno. Guitéras,
"Jno. M. Keating,
"Harrison Allen."

XII.—SPECIMENS FROM THE LOWER ANIMALS.

1. *Trichina spiralis.*

By Dr. R. M. Bertolet.

The specimen is a piece of ham infested with *trichina spiralis* sent to me for microscopic examination. To the naked eye it did not present any abnormal appearances, although the muscular fibres were quite densely packed with the trichinæ: this was easily accounted for by the fact that many of the parasites were still in the migratory state; others again were encapsuled, but the surrounding membrane had not yet been rendered opaque and thus visible to the unaided eye as white dots by the deposition of calcareous matters. No trichinæ were found in the layers of fat surrounding the muscular tissue. The fibres of the latter still presented their transverse striations, except in the immediate vicinity of the capsules, where they were cloudy and disintegrated, while at the same time the sarcolemma and interstitial connective tissue were greatly thickened.

It is presumable that the animal had been slaughtered within a brief time after being infested. It has been ascertained by experiment that from one to three months must elapse before the capsules become opaque.

Portions of the same ham, which had been cured and smoked, were eaten uncooked by a family at Harrisburg, all the members of which were taken violently ill upon the third day, one of the cases terminating fatally in less than a week's time. The communication received did not state what symptoms the patient had presented, but generally, in those rare cases where the disease proves so rapidly fatal, there is violent gastro-enteritis, with more or less pronounced peritonitis. Usually trichinosis assumes a much slower progress, giving rise to intense muscular pains and œdema, simulating muscular rheumatism. *May* 28*th*, 1874.

2. *Cystic liver from a rat.*

By Dr. A. C. W. Beecher, for Dr. Isaac E. Roberts.

The rat was found dead, lying in the middle of the cellar floor. Because so found although no poison had been laid for rats, curiosity as to the cause of apparent sudden death led to the *post-mortem* examination.

The rat appeared to be an old one, was well nourished, but not fat. When opened, the stomach was found distended to its utmost capacity with material resembling moist dirt, having no appearance of food. The intestines were entirely empty. It was neglected to observe whether or not there was an obstruction at the pylorus. The liver was covered with cysts about the size of a pea, each cyst containing a worm from one and a quarter to one and a half inches long. The liver-structures seemed to be healthy.

October 8th, 1874.

Report of the Committee on Morbid Growths:

"In each of the numerous cysts contained in the rat's liver presented by Dr. Beecher, was found coiled up a single worm, averaging fully an inch in length, with numerous transverse segments (over a hundred proglottides were counted in a single specimen). The caudal joints are contracted and filled with ova. The double row of hooklets upon the head, numbering thirty-two in all, each supplied with the characteristic claw, determines this parasite to be a tænia solium." *October 22d*, 1874.

---

3. *Sponge-like bodies from synovial cyst in a cow.*

By Dr. J. C. Wilson.

These small bodies were evacuated by the spontaneous opening of a large synovial sac on the leg of a cow. They were irregularly spherical in shape, and ranged from a quarter to a half inch in diameter. They looked like small pieces of soft, white sponge. The cyst which contained them was a large one, and had existed four years, without, however, producing lameness. It burst whilst the animal was in the stable, and the quantity of these sponge-like masses that fell out amounted to a quart.

A little clear gummy liquid escaped with them. When fresh, they had a strong alkaline odor. *April 22d*, 1875.

INDEX.

Addison's disease, diseased supra-renal capsules from, 211.
Adenoid (Hodgkin's) disease, 208.
Albuminoid expectoration, 124.
Allen, H., case of lipoma from popliteal space, 226.
Allis, O. H., intra-capsular fracture of femur, 5.
cancer of the liver, 65.
pseudo-membranous laryngitis, 119.
Anatomical differences between sarcoma, carcinoma, etc., 227.
Aneurism of aorta, 77, 97.
of subclavian artery, treated by introduction of horse-hair, 79.
of abdominal aorta, 86, 88, 105, 106.
of arch of aorta, 84, 87.
of arch of aorta with enormous hypertrophy of heart, 88.
of innominate artery, causing obstruction of larynx, 103.
Aneurismal perforation of trachea, 96.
Angeioma, multiple, of the liver, 68.
with sarcomatous degeneration, 223.
Aorta, rupture of abdominal, 63.
calcareous and atheromatous degeneration of, 83.
incised wound of, with punctured wound of chest-wall, 106.
rupture of, 111.
Aortic and mitral disease, 72.
Apoplexy complicating fracture of skull, 191.
Arthritis, chronic, of knee-joint, 5.
chronic, of wrist, 9.
Ashhurst, Jno., Jr., exostosis of lower jaw, 11.
excision of knee, 14.
compound fracture of skull, vertebræ, and ribs, 15.
cystic disease of submaxillary gland, 45.
rupture of external iliac artery, 107.
vesical calculus of small size producing marked symptoms, 153.
gunshot wound of eye, with excision of the ball, 203.
case of hard cancer of mamma, 220.
Ashhurst, John, Jr., sebaceous cyst from temporal region, 226.
case of lipoma from infra-mammary region, 226.
solid enlargement of bursa patellæ, 227.
verbal communication on the anatomical differences between sarcoma, carcinoma, etc., 227.
cystic mammary tumor, 230.
supernumerary toe, 242.
Atheroma of aorta, 83.
of circle of Willis and cerebral arteries, 90.
Aural polyp, 197.
polypi, with portions of necrosed incus, 199.

Barton, J. M., coxalgia, 15.
Bead removed from meatus auditorius externus, 201.
Beecher, A. C. W., multiple intussusception, 25.
gummata in liver, 56.
cystic liver from a rat, 252.
Bertolet, R. M., epulis, 6.
multiple gummata of cranial bones and dorsal vertebræ, 7.
biliary calculi, impacted, 65.
multiple cavernous angeioma of the liver, 68.
aneurismal perforation of trachea, 96.
papillomata in the larynx of a child, 113.
tubercular ulceration of the larynx and trachea, 129.
tuberculosis of kidney: peculiar worm-like bodies from urine of, 142.
sclerosis of posterior columns of spinal cord (ordinary locomotor ataxia), 182.
sclerosis of posterior columns of the spinal cord, with atrophy of the motor cells in the anterior horns of the gray substance (infantile spinal paralysis), 184.
myxomatous sarcoma of the brachial plexus, 188.

Bertolet, R. M., multiple myxoma of the spinal cord, 189.
trichina spiralis, 251.
Black, J. J., cancer of cæcum, etc., 46.
Bowel, obstruction of, 20.
Brachial plexus, myxomatous sarcoma of, 188.
Brain, tuberculous deposit at base of, 181.
Broad ligament, fluid removed from cyst of, 155.
Bronchial cast, 126.
Burnett, Chas. H., aural polyp, 197.
polypi from ear, with portions of necrosed incus, 199.
keratosis obturans, 201.
bead removed from meatus auditorius externus, 201.
Bursa patellæ, solid enlargement of, 227.

Cæcum, cancer of, and intussusception into large intestine; fibroid tumor of uterus; cystic ovaries, 46.
Calculi, impacted biliary, causing cystic formations in liver, 65.
Calculus, bladder, ureters, and sacculated kidneys, 152.
vesical, of small size, producing marked symptoms, 153.
Cancer of liver, 22.
of gall-bladder, 32.
scirrhous, of the pancreas, liver, and lung; hydatid cyst of the liver, 51.
epithelial, of rectum, 59.
of the liver, 65.
medullary, of the left ovary, 157.
of uterus, 164.
epithelial, of vagina, 166.
cystic medullary, of the testicle, 175.
epithelial, of the male urethra, 178.
hard, of the mamma, 215, 218, 220.
Cast of a bronchial tube, 126.
Chest-wall, punctured wound of, with incised wound of aorta, 106.
Chloral, anatomical, pathological, and surgical uses of, 232.
Cirrhosis of liver, 21.
of liver and congested stomach, 55.
Cirrhotic kidneys and hypertrophied heart, 147.
kidneys, latent, 150.
Clark, L. S., epithelial cancer of rectum, 59.
Cleemann, R. A., congenital imperforation of duodenum and absence of gall-bladder, 38.
extensive subcranial extravasation, complicating fissured fracture of the skull, 191.
Cohen, J. Solis-, cast from a bronchial tube, 126.
Corpus striatum, clot in left, 190.
Coxalgia, 15.
Cyst of the broad ligament, fluid removed from, 155.
sebaceous, from temporal region, 226.
Cystic disease of submaxillary gland, 45.
ovaries, with cancer of the cæcum, and its intussusception; fibroid tumor of the uterus, 46.
formations in liver due to biliary calculi, 65.
kidneys, 35, 139, 148.
mammary tumor, 230.
liver from a rat, 252.

Darrach, Wm., case of clot in left corpus striatum, 190.
Digestive apparatus, 20.
Duhring, L. A., specimen of lupus vulgaris, 205.
sarcomatous degeneration of angeioma, 223.
Duodenum, congenital imperforation of, 38.
Dysenteric inflammation, with cystic kidneys, 35.

Empyema, 135.
Epithelioma of lip, two specimens of, 229.
Epulis, 6.
Exostosis of lower jaw, 11.
Expectoration, albuminoid, 124.
Extravasation, extensive subcranial, complicating fissured fracture of the skull, 191.
Eye, gunshot wound of; excision of eyeball, 203.

Fallopian tube, dropsy of right, with ovarian tumor of the left, 154.
Fatty tumor from region of the scapula, 220.
Female organs of generation, 154.
Femur, intra-capsular fracture of, 5.
Fibroid tumor of the uterus, 165.
Foramen ovale, patulous; thickened pericardium, 93.
Forbes, W. S., fracture of skull, 16.
cystic medullary cancer of the testicle, 175.

Gall-bladder, rupture of, 23.
cancer of, 32.
absence of, 38.
Gall-stone passed during life, 25.
Gastric ulcer, 35.
Genito-urinary apparatus, 139.
Glands, ductless, diseases of, 208.
Graham, Jas., aneurism of abdominal aorta, 105.
Guitéras, Jno., aneurism of aorta with supposed rupture of heart, 97.
aneurism of innominate artery, causing compression of the trachea, 103.
abscess of the lung, 127.
Gummata, multiple, of cranial bones and dorsal vertebræ, 7.
in liver, 56.

Hæmaturia, kidney from a case of, 151.
Haynes, Francis L., fibroid tumor of uterus, 165.
Heart, congenital malformation of, 78.
hypertrophy of, with aneurism of the aorta, 88.
hypertrophy of, 92.
rupture of, 94.
hypertrophy of, with pericarditis, 95.
dilated with pleuritic effusion, 100.
Hemorrhage, cerebral, 179.
Henry, F. P., cancer of pylorus, 27.
cystic kidneys, with dysenteric inflammation, 35.
gastric ulcer, 35.
two cases of intestinal perforation, the sequelæ of typhoid fever, 41.
peritoneal tuberculosis, 50.
cirrhosis of liver and congested stomach, 55.
lungs from a case of empyema, 135.
cirrhotic kidneys and hypertrophied heart, 147.
ovarian tumor, 156.
diseased supra-renal capsules from Addison's disease, 211.
Hernia, multiple, 62.
Hip-joint disease, 10.
Hodge, H. L., chronic arthritis of knee-joint, 5.
chronic arthritis of wrist, 9.
hip-joint disease, 10.
ovarian tumor, 154.
ovarian tumor removed by ovariotomy, 154.
ovarian tumor of the left ovary, and a tubal dropsy of the right Fallopian tube, 154.
fluid removed from cyst of the broad ligament, 155.
Hodgkin's disease, 208.
Hutchinson, J. H., aneurism of aorta, 77.
atheromatous and calcareous degeneration of aorta, 83.
aneurism of arch of aorta, 84.
adenoid (Hodgkin's) disease, 208.
Hydrocele, chylous fluid from, 176.
Hydrothorax, from chronic subacute pleurisy; paracentesis, 116.

Iliac, external, artery, rupture of, 107.
Innominate artery, aneurism of, causing obstruction in larynx; tracheotomy, 103.
Intestinal perforation, two cases of, 41.
obstruction by thrombus resulting from rupture of aorta, 63.
Intussusception, 24.
multiple, 25, 26.
of a cancerous cæcum into large intestine; fibroid tumors of the uterus; cystic ovaries, 46.

Jaw, lower, exostosis of, 11.
Jaw, lower, osteo-sarcoma of, 12.

Keating, John M., so-called hermaphroditism, 242.
Keen, W. W., medullary cancer of the left ovary, 157.
anatomical, etc., uses of chloral, 232.
Keratosis obturans, 201.
Kidneys, cystic, with dysenteric inflammation, 35.
disease of, with mitral disease, 72.
bladder, etc., 139.
cirrhotic, with enormous hypertrophy of heart, 140.
contracted, with hypertrophy of heart, 147.
cystic, 148.
soft cancer of, and of lumbar glands, 148.
latent cirrhosis of, 150.
from a case of hæmaturia in an infant, 151.
sacculated, 152.
Knee, excision of, 14.
-joint, chronic arthritis in, 5.

Laryngitis, pseudo-membranous, 119.
Larynx of a child, papillomata in, 113.
and trachea, tubercular ulceration of, 129.
of a man strangled by a piece of meat, with the bolus, 137.
Lipoma from infra-mammary region, 226.
from popliteal space, 226.
Liver, cancer of, 22, 65.
abscess of, 47.
hydatid cyst in, 51.
pancreas, and lung, scirrhous cancer of, 51.
cirrhosis of, 55.
gummata in, 56.
cystic formations in, due to impacted calculi, 65.
multiple cavernous angeioma of, 68.
cystic, from a rat, 252.
Locomotor ataxia, 182.
Longstreth, Morris, obstruction of bowel, 20.
enlarged spleen and cirrhotic liver, 21.
cancer of liver, 22.
multiple intussusception, 26.
specimens from Dr. Levis's case of aneurism of the subclavian artery, treated by the introduction of horse-hair, 79.
Lung, abscess of, 127.
pancreas, and liver, scirrhous cancer of, 51.
Lungs from a case of empyema, 135.
Lupus vulgaris, 205.
Lymphatics, enlarged, with general tuberculosis, 113.

Male organs of generation, 172.

Mamma, viscera from case of amputation of, 31.
hard cancer of, 218, 220.
cystic tumor of, 230.
Masten, C. H., chylous fluid from hydrocele, 176.
Mears, J. E., osteo-sarcoma of lower jaw, 12.
compound fracture of cranium, 12.
ulceration of Peyer's glands, 33.
sarcoma, involving parotid gland, 41.
disease of the mitral and aortic valves, 72.
medullary cancer of the left ovary, 157.
epithelial cancer of the vagina, 166.
epithelial cancer of the male urethra, 178.
wad of paper and cloth removed from lacerated wound of leg, 241.
Mitral and aortic disease, 72.
Mitral disease of the heart, with disease of the kidneys, 72.
Monstrosity, case of, 243.
Morbid growths, report of Committee on Dr. Mears's specimen of osteo-sarcoma of the jaw, 12.
report of Committee on viscera from Dr. Packard's case of amputation of breast, 32.
report of Committee on Dr. Beecher's case of gummata in the liver, 59.
report of Committee on Dr. Clark's specimen of epithelial cancer of the rectum, 62.
report of Committee on the thickened pericardium presented by Dr. Sinkler, 92.
report of Committee on the ruptured aorta presented by Dr. Porter, 112.
report of Committee on the button-like prominence upon the inner wall of the pulmonary cavity presented by Dr. Pepper, 126.
report of Committee on the cystic kidney presented by Dr. Willard, 140.
report of Committee on Dr. Packard's case of cancer of the uterus, 165.
report of Committee on Dr. Schell's case of congenital occlusion of the vagina, 172.
report of Committee on Dr. Forbes's case of cystic medullary cancer of testicle, 176.
report of Committee on Dr. Mears's case of epithelial cancer of male urethra, 178.
report of Committee on Dr. Burnett's case of aural polyp, 198.
report of Committee on supra-renal capsule presented by Dr. Henry, 213.
report of Committee on Dr. Packard's case of tumor of the thyroid gland, 213.
Morbid growths, report of Committee on Dr. Porter's case of enlarged spleen, 217.
report of Committee on Dr. Mears's specimen of hard cancer of the mamma, 219.
report of Committee on Dr. Allen's case of lipoma, 227.
report of Committee on Dr. Ashhurst's specimen of enlarged bursa patellæ, 227.
report of Committee on Dr. Ashhurst's case of cystic mammary tumor, 231.
Muscular spasms, post-mortem, with rupture of the heart, 94.
Myxoma, multiple, of the spinal cord, 189.
Myxomatous sarcoma of the brachial plexus, 188.

Nancrede, C. B., small round-celled sarcoma, 1.
fatty tumor from region of scapula, 220.
epithelioma of lip, 229.
Nervous system, 179.
Norris, W. F., report on Dr. Ashhurst's case of excision of the eyeball after gunshot wound, 203.

Obstruction of bowel, 20.
Osgood, Hamilton, scirrhous cancer of pancreas, liver, and lung; hydatid cyst of liver, 51.
Osseous system, 1.
Ovarian tumor, 154, 156.
removed by ovariotomy, 154.
of left ovary, and a tubal dropsy of the right Fallopian tube, 154.
Ovary, left, medullary cancer of, 157.

Packard, Jno. H., viscera from a case of amputation of breast, 31.
dilated heart, with pleuritic effusion, 100.
cancer of uterus, 164.
cerebral hemorrhage, 179, 180.
tuberculous deposit at base of brain, 181.
tumor of thyroid gland, 213.
case of hard cancer of mamma, 218.
Pancreas, liver, and lung, scirrhous cancer of, 51.
Papillomata in the larynx of a child, 113.
Paracentesis thoracis, 116.
Paralysis, infantile spinal, 184.
Parish, W. H., cystic kidneys, 148.
Parks, Edw. L., fracture of cranium, 17.
punctured wound of chest-wall, with incised wound of aorta, 106.
larynx of a man strangled by a piece of meat, with the bolus, 137.
Parotid gland, sarcoma involving, 41.
Pepper, Wm., rupture of gall-bladder, 26.
enormously distended stomach, 27.

Pepper, Wm., typhoid fever; anomalous course of temperature, 29.
two specimens of intestines from typhoid fever, 36.
hepatic abscess, 47.
verbal communication on intestinal obstruction caused by huge thrombus resulting from rupture of abdominal aorta, 63.
acute pericarditis, with hypertrophy of heart from previous disease, 95.
hydrothorax, from chronic subacute pleurisy; paracentesis; return of pleurisy; death from ulceration of colon, 116.
albuminoid expectoration, 124.
pulmonary phthisis, with cavities, 125.
latent cirrhosis of kidneys without albuminuria or dropsy, 150.
Pericarditis, with thickening, 92.
with thickening; patulous foramen ovale, 93.
acute: hypertrophy of heart, 95.
Peritoneum, tuberculosis of, 50.
Peyer's glands, ulceration of, 33.
Phthisis, with chronic pleurisy, 122.
with cavities, 125.
Pleura, acute miliary tuberculosis of, after acute catarrhal pneumonia, 120.
Pleurisy, chronic, with phthisis, 122.
Pleuritic effusion, with dilated heart, 100.
Pneumonia, acute catarrhal, with secondary miliary tuberculosis of the pleura, 120.
Porter, W. G., aneurism of abdominal aorta, 106.
rupture of aorta, 111.
calculus, bladder, ureters, and sacculated kidneys, 152.
enormously enlarged spleen, 214.
Pylorus, cancer of, 27.

Rectum, epithelial cancer of, 59.
Reed, H. B., aneurism of abdominal aorta, 86.
Reed, Thomas B., tuberculosis of kidney: peculiar worm-like bodies from urine of, 142.
Rex, Geo., congenital malformation of heart, contraction of pulmonary artery, and deficient septum ventriculorum, with origin of aorta from both ventricles, 78.
Richardson, Joseph G., general tuberculosis, with enlarged lymphatics, 113.
kidney from a case of hæmaturia in an infant, 151.
report on Dr. Packard's case of tuberculosis at base of brain, 182.

Sarcoma, case of small round-celled, 1.
osteo-, of lower jaw, 12.
involving parotid gland, 41.
Sarcoma of the testicle, and undescended testicle, occurring in the same individual, 172.
myxomatous, of the brachial plexus, 188.
carcinoma, etc., anatomical differences between, 227.
Sarcomatous degeneration of angeioma, 223.
Schell, H. S., a case of atresia vaginæ, 168.
Sebaceous cyst from temporal region, 226.
Sinkler, Wharton, cancer of the cæcum, and intussusception into large intestine; cystic ovaries, 46.
atheroma of circle of Willis, 90.
hypertrophy of heart; pericarditis, with thickening, 92.
patulous foramen ovale; pericarditis, with thickening, 93.
extensive disease of mitral valves, 93.
Skull, multiple gummata in, 7.
compound fracture of, 12, 15.
fracture of, 16, 17.
Skin, diseases of, 205.
Special sense, organs of, 197.
Committee, report of, on the calculus presented by Dr. Porter, 153.
Committee, report of, on Dr. Hodge's specimen of ovarian tumor, 155.
Committee, report of, on Dr. Jno. M. Keating's case of so-called hermaphroditism, 242.
Committee, report of, on Dr. F. H. Gross's case of monstrosity, 243.
Spinal cord, sclerosis of the posterior columns of, 182.
sclerosis of the posterior columns of, with atrophy of the motor cells in the anterior horns of the gray substance, 184.
multiple myxoma of, 189.
Spleen, enlarged, with cirrhotic liver, 20.
enormously enlarged, 214.
Sponge-like bodies from a synovial cyst in a cow, 252.
Stewart, ——, cancer of cæcum, etc., 46.
Stomach, enormously distended, 26.
congestion of, with cirrhosis of liver, 55.
Strangulation, with the bolus which caused it, 137.
Subclavian artery, aneurism of, treated by introduction of horse-hair, 79.
Submaxillary gland, cystic disease of, 45.
Supra-renal capsules from a case of Addison's disease, 211.

Testicle, undescended, with sarcoma of the other testicle, in the same individual, 172.
cystic medullary cancer of, 175.
Thyroid gland, tumor of, 213.
Toe, supernumerary, 242.

Townsend, Ralph M., sarcoma of the testicle, with second testicle undescended, 172.
Trachea, aneurismal perforation of, 96.
Trichina spiralis, 251.
Tubercular ulceration of larynx and trachea, 129.
Tuberculosis, peritoneal, 50.
general, with enlarged lymphatics, 113.
acute miliary, of the pleura after acute catarrhal pneumonia, 120.
of the kidney, 142.
Tuberculous deposit at base of brain, 180.
Typhoid fever, anomalous course of temperature in, 29.
two specimens of intestines from, 36.
cases of intestinal perforation after, 41.
Tyson, James, intussusception, 24.
gall-stone passed during life, 25.
cancer of gall-bladder, 32.
mitral disease, with renal disease, 72.
aneurism of aorta, with hypertrophy of heart, 88.
lungs, from a case of acute catarrhal pneumonia, with secondary miliary tuberculosis of the pleura, 120.
cirrhotic kidneys, with enormous hypertrophy of heart, 140.
soft cancer of kidneys and lumbar glands, 148.
Tyson, James, report on Dr. Masten's case of chylous fluid from a hydrocele, 176.

Uterus, fibroid tumor of, with cancer of the cæcum, intussusception, and cystic ovaries, 46.
cancer of, 164.
fibroid tumor of, 165.

Vagina, epithelial cancer of, 166.
Vaginæ, atresia, a case of, 168.
Vascular system, 72.
Vermiform appendix, perforation of, 43.
Vertebræ and ribs, multiple fractures of, 15.

Wad of paper and cloth removed from lacerated wound of leg, 241.
Warder, W. H., perforation of vermiform appendix, 43.
Willard, De F., multiple hernia, 62.
chronic pleurisy, with phthisis, 122.
cystic kidneys; tuberculous phthisis; ulceration of stomach and intestines, 139.
Wilson, J. C., aneurism of the abdominal aorta, 88.
sponge-like bodies from a synovial cyst from a cow, 252.
Woodward, J. J., remarks on myxoma, 190.
"Worm-like" bodies, peculiar, from a case of tuberculosis of the kidney, 142.
Wrist, chronic arthritis of, 9.

THE END.

ERRATUM.

On page 51, for Dr. H. R. Osgood read Dr. Hamilton Osgood.